



INSTRUMENTS FOR IMAGE GUIDE PROCEDURES – IIGP REVIEW PAPERS

Student Papers and Poster

Michael Friebe, Editor

WS 2016/2017 – ADD-ON



INKA:
Otto-von-Guericke-University of Magdeburg
P.O.Box 4120, 39016 Magdeburg, Germany
www.inka-md.de || inka@ovgu.de || +49 391 67 57024



INSTRUMENTS FOR IMAGE GUIDED PROCEDURES – OVGU/INKA – WS 2016/2017 – Prof. Michael Friebe

1	Alan Guthrie	<i>Current neuroaneurysm treatment strategies and future developments Will we continue the way we do the procedures right now?</i>	5
2	Nazila Esmaeli	<i>Electrochemotherapy – What is it? What is it used for? What is needed? What are alternative IGP approaches? What needs to be done to make it applicable for other applications?</i>	18
3	Philipp Steiner	<i>Interventional Photodynamic Therapy (PDT) – Applications, current problems and future developments</i>	30
4	Sagar Shetty	<i>Dose Management of Interventional X-Ray Procedures</i>	41
5	Parisa Parsanejad	<i>Selective Internal Radiation Therapy: Systems, Applications, Limitations and Future</i>	52
6	Marco Ferrari	<i>Bladder tumor treatment with IGP how could we improve this?</i>	61
7	Charusree Madhav	<i>MRI Guided Interventions: A Review</i>	73
8	Aswith Kottary	<i>Interventional palliative treatment for bone metastases</i>	81
9	Mahurshi Parikh	<i>Exponential Technologies in Healthcare Possible Impact on Future</i>	92
10	Rajan H. Patel	<i>Hybrid Imaging for Image Guided Procedures</i>	101
11	Debarati Bag	<i>Do we need robotic prostatectomy? - The Big Question</i>	111
12	Maryam Sadeghi	<i>Review of balloon radiation in breast cancer treatment: Advantages, disadvantages and future outlook</i>	119
13	Erdinç Avcıoğlu	<i>Stenosis – Interventional and Diagnostic Tools and Systems needed and available to treat Atherosclerosis</i>	128

INSTRUMENTS FOR IMAGE GUIDED PROCEDURES

The MASTER OF SCIENCE IN MEDICAL SYSTEMS ENGINEERING (<http://www.lmt.ovgu.de/MasterMSE.html>) at the Otto-von-Guericke-University in Magdeburg, Germany (www.ovgu.de) is an english language program. The current enrolment is very international (> 10 nations) with more than 50% coming from non-German language countries.

While it is very exciting to have such an international student body it also shows huge differences in what the students are capable of and what their undergraduate degree prepared them for. Some of them have never been exposed to scientific evaluation, to analyse and to present scientific data. Besides teaching the technical essentials and attending laboratory sessions (total 3 SWS, 5 ECTS) the students had therefore several additional assignments to complete to address some of these issues.

Part of the lecture INSTRUMENTS FOR IMAGE GUIDED PROCEDURES (IIGP) was an individual final project that should also teach the students on how to prepare themselves for future scientific work, by evaluating current technologies and procedures for a relatively narrowly formulated topic in the field of IMAGE GUIDED PROCEDURES.

This project consisted of a “review” paper with approx. 3.000 - 4.000 words, as well as a poster that summarises the findings. The main focus for their analysis was on describing the technologies and their limitations with an outlook on future developments.

The review documents and the posters came from 13 students (5 nations) that had capabilities that are very typical for a graduate lecture and seminar class and resemble a standard gauss distribution. You will easily recognise the good works and the ones where the students could have invested more time and effort in preparing the assignment. The included works have not been intensively edited.

This was the second time that this lecture was given (WS 2015/2016 and WS 2016/2017). The summaries and poster presentations provide a great value for the Master students and also for the academic staff, and other researchers by giving them a short introduction and overview, as well as some of the references for further more depth information. This is the reason why we decided to publish the summaries in an Open-Access booklet – this is the first add-on to the initial booklet, which was published in January 2016.

In the coming semesters the assignments below average will be replaced and also many new topics from the exciting field of IMAGE GUIDED PROCEDURES will be added.

Magdeburg, Germany, January 2017



Michael Friebe, PhD

Professor of Catheter Technologies and Image Guided Therapies

Faculty of Electrical and Information Technologies
Institute for Medical Engineering
Otto-von-Guericke-University, Magdeburg, Germany
michael.friebe@ovgu.de
www.inka-md.de



Current neuroaneurysm treatment strategies and future developments

Alan Guthrie, Medical Systems Engineering, Otto-von-Guericke-Universität Magdeburg
Instruments for Image Guided Procedures

Introduction

An aneurysm is a bulging deformation in the wall of a blood vessel, with reduced thickness, higher stress

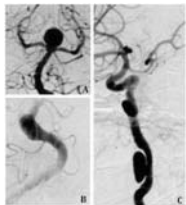


Fig. 1. DSA images of A) saccular, B) fusiform, and C) dissecting unruptured aneurysms [1].

- Saccular, fusiform, dissecting types (saccular most common)
- Risk factors: smoking, hypertension, genetics
- Growth through inflammation
- Treatable with open-surgical or endovascular approaches
- Market shares roughly equal; not all aneurysms amenable to endovascular approach

Rupture of a neuroaneurysm (in the brain) means death or brain damage in most cases

- Neuroaneurysm overall prevalence of 2.3%, increases with age [1]
- Neuroaneurysm rupture occurs in about 1 in 10,000 persons yearly [1]
- May lead to subarachnoid hemorrhage
- Death/permanent disability in most of those affected
- Intraoperative hemorrhage in small number of patients, larger number in next 30 days
- Unruptured, can still cause mass effect

Table 1: Comparison of surgical treatment strategies

Performance: + + Good, - - Bad	Clipping	Coiling	IC-IC bypass	EV flow diversion	Liquid embolization
Invasive	yes	min.	yes	min.	min.
Scarring	-	++	--	++	++
Rebleeding	++	0	-	-	0
Complications	-	+	-	+	++
Difficult geometry	-	--	++	+	-
Cost	+	0	+	--	++
Improviability	-	0	-	++	++

Current treatment methods

Open surgical clipping

- Access gained by removal of cranium segment (craniotomy)
- Biocompatible titanium clip applied with forceps to aneurysm neck, starving blood flow, preventing rupture
- To open surgical path, brain must be relaxed by draining cerebrospinal fluid
- Excellent long-term stability, low rates of rebleeding
- Favored in young patients
- Fluoroscopy not needed

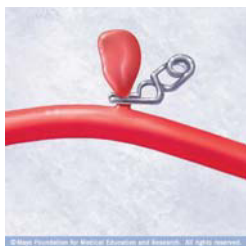


Fig. 2. Titanium surgical clip applied to neck of a saccular aneurysm [2].

Extracranial-intracranial (EC-IC) bypass

- Blood flow rerouted to avoid aneurysm entirely
- Blood sourced from neck artery
- Vessel segment with aneurysm ligated proximally
- Donor vessel from leg or arm
- Permanent hole in cranium required to route bypass
- Poor efficacy at preventing stroke
- Still usable for otherwise-untreatable giant aneurysms, or aneurysms with complicating features (no neck, calcification, atheroma)

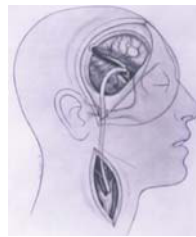


Fig. 3. Extracranial-intracranial (EC-IC) bypass, showing craniotomy and neck incision [3].

Endovascular coiling

- Platinum coils fed into aneurysm from catheter
- Embolic reaction provoked, aneurysm fills with blood clot, preventing future rupture
- Stents can be used to keep coils inside aneurysm
- Large study in 2002 [6] showed risk reduction vs. clipping, fewer patients dead/disabled at 1 year
- To enhance stability, coatings can be applied (benefit not conclusively proven yet)
- Some aneurysms can't be treated with coils due to bad geometry (e.g. large or non-existent neck)

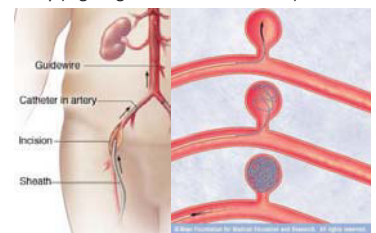


Fig. 4. Endovascular coiling, showing insertion in femoral artery [2].

Emerging treatment methods

Endovascular flow diversion

- Endovascular version of bypass approach
- Stent placed over aneurysm, vascular wall grows over time- total occlusion after months to a year
- Can be coated with pharmaceuticals
- Well-suited to otherwise untreatable aneurysms
- Alone, poorly suited to ruptured aneurysms
- Expensive
- Market share increasing




Fig. 5. Two models of flow diverter: A) Enterprise, B) Vision [4].

Intracranial-Intracranial (IC-IC) bypass

- Evolution of EC-IC bypass
- Blood redirected from inside the cranium, instead of from neck vessel; shorter graft needed
- Various techniques, more challenging than EC-IC
- In-situ: donor and recipient arteries connected side-to-side
- Reanastomosis: arterial ends before and after aneurysm joined together, aneurysm excised
- Increases number of vessels occluded during surgery, but avoids diameter vessel mismatch

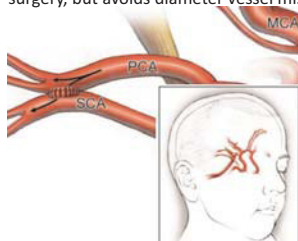


Fig. 6. IC-IC bypass from posterior cerebral artery, bypassing aneurysm of the superior cerebral artery with in-situ technique [5].

Liquid embolization

- Similar approach to coiling, but liquid replaces coils
- Binary composition, liquid solidifies inside aneurysm
- Can be adhesive or non-adhesive
- In current practice, used to stabilize coils; could be used to replace them
- ONYX: ethylene/vinyl alcohol copolymer, tantalum powder for fluoroscopy visibility
- TRUFILL: n-butyl cyanoacrylate
- ALGEL: calcium alginate, completely mechanical occlusion, does not cause thrombosis

Non-surgical treatment

- Most aneurysms will never rupture
- Proportion can be further decreased by reducing inflammation, blood pressure
- Angiotensin-1-7 reduced rupture rate in mice
- Implantation of progenitor cells, steered with iron oxide nanoparticles, hastened regeneration of vessel wall over coiled aneurysms in mice
- Genetic testing could inform lifestyle choices of vulnerable individuals

Unmet needs

- Reduction in rebleed rate, long-term stability for coiling, liquid embolization to be more competitive with clipping
- Reduced time for revascularization of flow diverter; 3x more rebleeds in 30-days after surgery than thereafter [6]

Trends

- Preference for minimally-invasive approach
- Clipping still needed for some aneurysms
- Flow diversion increasing despite expense
- EC-IC bypass phased out; IC-IC next?
- Major reductions in mortality through improved pharmaceuticals

References

- [1] Forsting M, Wanke I (ed). Intracranial vascular malformations and aneurysms. Berlin/Heidelberg: Springer-Verlag 2006.
- [2] Mayo Clinic. Diseases and Conditions: Brain aneurysm. 2015 (www.mayoclinic.org/diseases-conditions/brain-aneurysm/basics/treatment/con-20028457) [Accessed 28 December 2016].
- [3] Gobble RM, Hoang H, et al. Extracranial-intracranial bypass: resurrection of a nearly extinct operation. J Vasc Surg 56 (5): 13037, 2012.
- [4] Tremmel M, Xiang J, et al. Alteration of intraaneurysmal hemodynamics for flow diversion using enterprise and vision stents. World Neurosurgery 74 (2):306-15, 2010.
- [5] Rodríguez-Hernández A, Huang C, Lawton MT. Superior cerebellar artery—posterior cerebral artery bypass: in situ bypass for posterior cerebral artery revascularization: Technical note. J Neurosurg 118 (5):1053-7, 2013.
- [6] Molyneux A, Kerr R, et al. International Subarachnoid Aneurysm Trial (ISAT) of neurosurgical clipping versus endovascular coiling in 2143 patients with ruptured intracranial aneurysms. The Lancet 360.9342: 1267-1274, 2002.

Current neuroaneurysm treatment strategies and future developments

Will we continue the way we do the procedures right now?

ALAN GUTHRIE

Faculty of Electrical Engineering and Information Technology, Otto-von-Guericke-Universität Magdeburg, Germany

Abstract

Lurking silently in the intricate vasculature of the brain, aneurysms are a deadly threat in modern life. Current strategies to eliminate them before or after they rupture are mainly focused on causing thrombosis by injecting platinum coils into the inside, constricting them from the outside with titanium clips, or if they aren't amenable to these treatments, cutting off their blood flow and replacing it with a link to a different artery. Emerging therapies include replacing coils with liquid agents, clipping with endoscopic tools, and diverting blood flow with stents. Non-surgical approaches are also highly effective, and will become more so.

KEY WORDS: cerebral aneurysm • neurosurgery • future treatments

AN aneurysm is a bulging, blood-containing deformation of a section of a blood vessel wall, which can grow and ultimately rupture, resulting in hemorrhage. Rupture of aneurysms occurring in the vessels which supply blood flow to the brain ('intracranial' or 'neuro'aneurysms) can lead to bleeding between the brain-protecting membranes of the arachnoid and pia matres, subarachnoid hemorrhage (SAH), which is exceptionally dangerous and results in death or permanent disability in 60% or more of those affected.

Abbreviations used in this paper: SAH: subarachnoid hemorrhage; IC: intracranial; EC: extracranial; STA-MCA: superficial temporal artery to middle cerebral artery; PET: positron emission tomography

For such lethality, neuroaneurysm is relatively common; its probability increases with age, especially past the thirties, and it is found in about 5-6% of bodies examined postmortem. Rupture is comparatively uncommon, occurring in about 1 in every 10,000 persons [1].

From a set of risk factors, including smoking, hypertension, and potentially genetics, neuroaneurysms are initiated by hemodynamic stress and resultant endothelial dysfunction. Growth is thought to occur by a process of inflammation, wherein the smooth muscle cells and intercellular matrix of the vascular wall are attacked and degraded by macrophages [2]. Much more rarely, aneurysms can be initiated by a head trauma. Rupture can occur when the inflammatory

process develops positive feedback, progressively weakening the blood vessel to the point where it cannot withstand the increased mechanical stress it will experience from its reduced wall thickness, even more so when the aneurysm reaches a large diameter. If growth becomes significant enough without rupture, the aneurysm may cause neurological symptoms by mass effect, i.e., by compression of nearby tissues.

Intracranial aneurysms are classifiable by form, size, and location. They occur mostly (~85%) in the anterior of the brain, and alone (70-75%) more commonly than multiply [3]. Saccular or “berry” aneurysms are the most common form, occurring primarily at arterial bifurcations. Dissecting aneurysms result from a tear in the inner layer of a blood vessel, and unlike saccular aneurysms occur more frequently in the vertebrobasilar system. Fusiform aneurysms are enlarged, twisted vascular sections, which often present symptoms from mass effect but rarely

rupture and cause hemorrhage. Some aneurysms, particularly fusiform types, do not have a well-defined neck, which complicates surgical treatment.

Surgical treatment can be performed with either an endovascular or an open approach. The endovascular approach relies on provoking the body’s thrombolytic reaction to platinum coils dispensed into the interior of the aneurysm. The process may be assisted or replaced with an injection of embolic chemicals. The open surgery approach involves placing a clip across the neck of the aneurysm to physically constrict blood flow to the inside of the aneurysm. If the aneurysm is not amenable to coiling or clipping due to lack of a well-defined neck or other problematic geometry, an alternative approach is to reroute blood around it, either endovascularly with a flow diverter stent or with open bypass surgery. Bypass surgery excludes the aneurysm from normal blood flow by creating a new flow route, either from outside or inside the cranium.

Prior to rupture, aneurysms may not cause any symptoms, especially if they are small. They may be discovered incidentally during medical imaging related to completely different pathologies. At this point, the doctor and patient must weigh the risk of the untreated aneurysm eventually rupturing against the risks of performing surgery. The intervention itself can cause hemorrhage, with one study observing a rate of 1.37% in endovascular coiling and 2.38% in surgical clipping amongst voluntarily admitted patients with unruptured aneurysms, with a total hospital mortality rate of the same cohort of 0.57% for coiling and 1.61% for clipping [4].

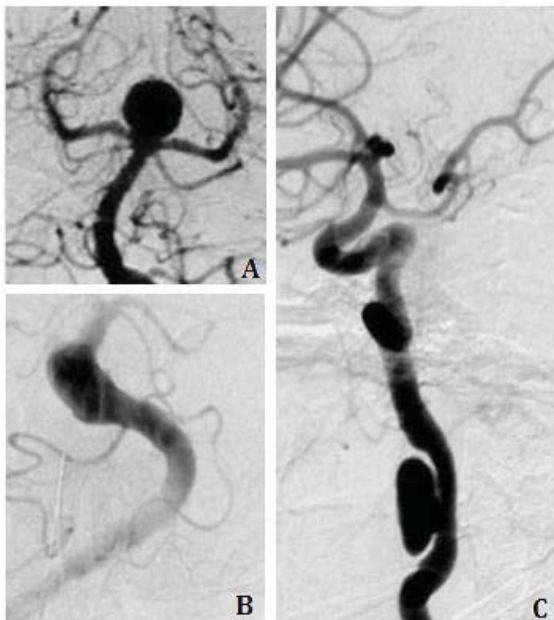


Fig. 1. DSA images of A) saccular, B) fusiform, and C) dissecting unruptured aneurysms [3].

After the procedure codes for coiling were established in 2001, the US market rapidly adopted it. By 2010, the 10,000 patients recorded in the Nationwide Inpatient Sample with surgically treated subarachnoid hemorrhage were being treated in roughly equal proportion with clipping and coiling. This trend was closely mirrored in treatment of unruptured aneurysms, although with a slight bias towards coiling (see figure 2) [5].

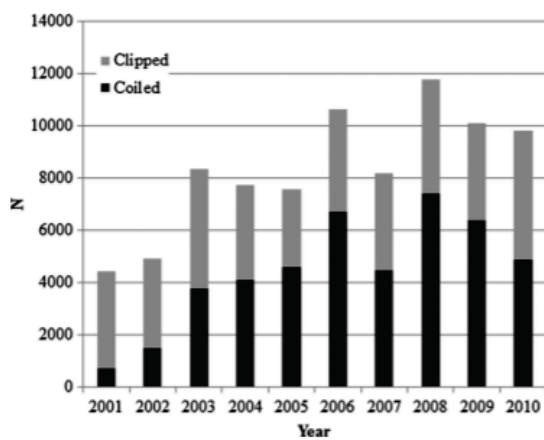


Fig. 2: Trend in procedural share from 2001-2010 for unruptured neuroaneurysms [5].

Current Treatment Strategy

Open Surgical Clipping

The result of evolutionary improvement in the traditional open-surgical approach is the placement of clips across the neck of the aneurysm. Gaining access to the surgical site requires temporary removal of a section of the cranium (craniotomy). With medical acceptance of the general superiority of minimally-invasive approaches, surgeons attempt to incise the smallest possible craniotomy in such cranial areas as the pterion for aneurysms near the circle of Willis, the frontal bone between the hemispheres for the anterior cerebral artery, or the supraorbital ridge for the terminal segment of the internal carotid artery [6].

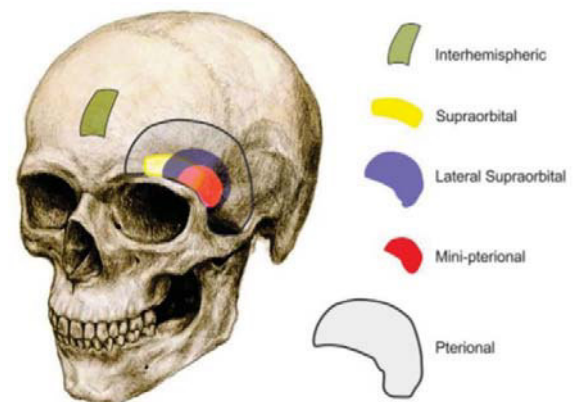


Fig. 3. Minimal craniotomies compared to traditional pterional craniotomy [7].

Under the guidance of a microscope, the surgeon will then navigate through the fissures of the brain to the aneurysm and place a clip across its neck. These clips are constructed of biocompatible titanium, and are available in a variety of shapes to better match various types and locations of aneurysms.

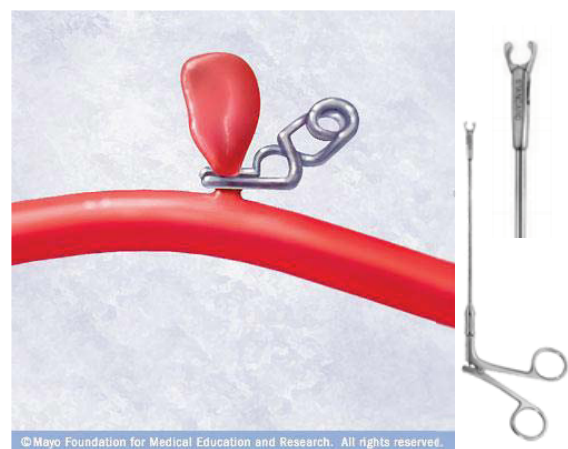


Fig. 4. Surgical clip placed on saccular aneurysm [8], and minimally-invasive placement tool [9].

Prior to clip placement, the brain must be relaxed by the drainage of cerebrospinal fluid to minimize the surgeon's need to retract surrounding brain tissue to clear a path to the working space. Brain retraction, along with temporary vessel occlusion and secondary hemorrhage, can result complications [10].

Depending on whether the aneurysm is unruptured or has previously ruptured, these complications can include postoperative inpatient death (0.7/11.5%), stroke (5.3/5.5%), cardiac issues (1.3/1.7%), pulmonary embolism (2.0/2.7%), deep vein thrombosis (0.6/2.8%), and treatable hydrocephalus (1.5/1.7%) [11].

Extracranial-intracranial (EC-IC) bypass

Bypass surgery can be used to open a blood supply route from the common carotid, external carotid, or superficial temporal artery, excluding an aneurysm from blood supply altogether without directly performing surgery on it. This challenging procedure is of use in treating giant intracranial artery aneurysms (GIAAs) with a diameter greater than 2.5 cm, with complicating features such as calcification, large neck, or atheroma. These features considerably decrease the safety of both clipping and coiling.

The bypass is constructed of a harvested segment from vessels such as the great saphenous vein which runs the length of the leg at a superficial depth, or the radial artery which runs along the radial bone in the forearm and supplies blood to the hand. The bypass vessel must match the diameter of the target vessels, limiting the suitability of donors. The extracranial artery is exposed through a cervical incision, and the intracranial artery through craniotomy. A tunnel must be bored in the removed skull flap to allow passage of the bypass vessel. Beginning with the distal end, and with injection of pharmaceuticals to control clotting time, the bypass site is dissected and anastomosis (surgical joining of blood

vessels) is performed with the bypass vessel. Then, the proximal end of the bypassed artery is ligated; even with the distal end remaining open, the aneurysm will thoroughly thrombose. Gobble et al. performed a series of 36 EC-IC bypass operations, with a death rate of 5.6% (2/36) and that same rate of both asymptomatic and symptomatic graft occlusion [12].

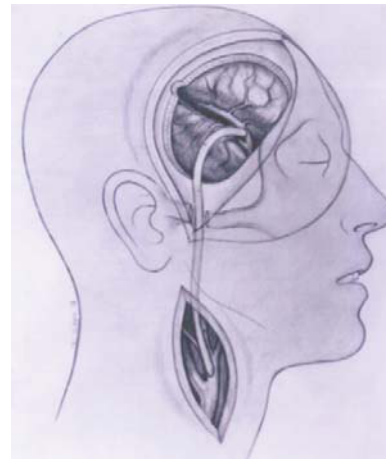


Fig. 5: Extracranial-intracranial bypass [12].

Although EC-IC bypass was a somewhat widespread technique in the past, evidence to support its efficacy in the prevention of stroke has not materialized. Early skepticism of the efficacy of EC-IC bypass in preventing stroke (bolstered by the results of the STA-MCA bypass trial in the 1980s) was hampered by criticism of patient selection. At the time, the state of the art in medical imaging was insufficient to select patients with impaired cerebral hemodynamics resulting from occlusive cerebrovascular disease, who would be the most likely to benefit from bypass surgery. The 2003-2013 Carotid Occlusion Surgery Study, COSS, used recently developed enhancements in PET imaging to detect hemodynamic cerebral ischemia through an increase in oxygen extraction fraction. Despite definite improvement in cerebral hemodynamics,

bypass only reduced the stroke rate from 22.7% to 21.0%, a non-significant improvement. Reasons given for this result included a high (15%) perioperative stroke rate, and a lower-than-expected stroke rate in the non-surgical group [13]. It was thus concluded that EC-IC bypass is not indicated in the prevention of stroke.

Endovascular coiling

The predominance of the endovascular approach in treating neuroaneurysm was heralded with Dr. Guido Guglielmi's invention of detachable platinum coils in 1990 [14]. Under the guidance of X-ray fluoroscopy, a surgeon inserts a catheter into an easily accessible artery (generally the femoral) with an introducer sheath, and maneuvers it through the circulatory system until the aneurysm is reached. Then, a thin, coiled platinum wire is dispensed through the catheter into the aneurysm, where it partially relaxes and fills the aneurysm. The coil can be adjusted, and once it is in the correct position it is detached from the catheter and followed by more coils until the aneurysm is sufficiently filled. The presence of a foreign body provokes a thrombotic reaction, embolizing the aneurysm and preventing rupture and/or bleeding. In aneurysms with wider necks, a stent can be placed over the aneurysm and the coils can be fed through

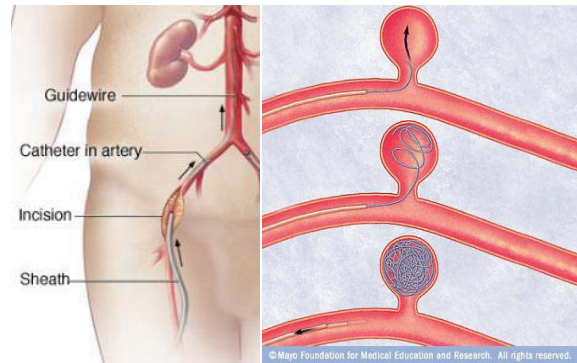


Fig. 6: Endovascular coiling procedure in saccular aneurysm [8].

gaps in the stent, preventing the coils from escaping the body of the aneurysm and causing undesirable embolization elsewhere.

Since its invention, the coiling method has generally displaced the clipping method in patients who are not unsuitable for coiling for clinical or anatomical reasons. However, its advantageousness compared to clipping has been debated. The turning point came with the publishing of the International Subarachnoid Aneurysm Trial (ISAT) in 2002, a study of over a thousand ruptured-neuroaneurysm patients treated with each method. The primary metric was the proportion of patients dependent or dead after 1 year; the absolute endovascular risk reduction was 6.9%, a relative reduction of 22.6% compared with the conventional surgery [15]. Mortality was similar between the two treatments, but a significantly lower

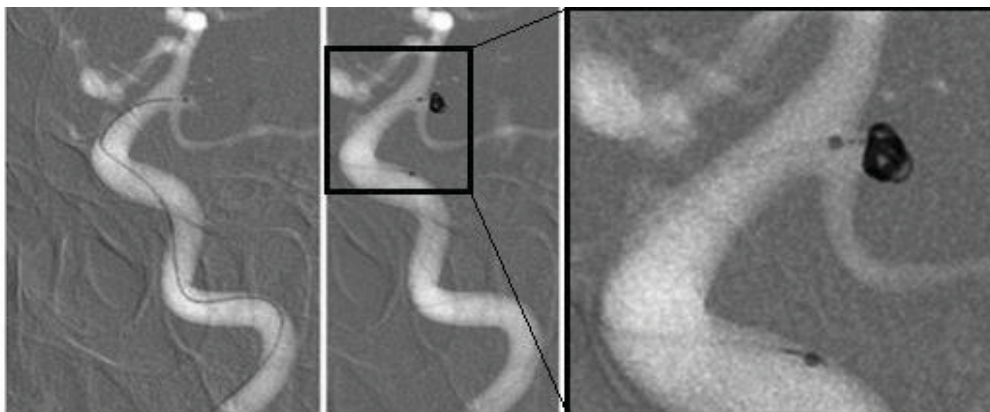


Fig. 7. Fluoroscopic view of a saccular aneurysm being coiled, ad. [16].

frequency of serious brain damage was assessed in the patients treated endovascularly. One of the major reasons for institutional distrust of the endovascular method was a perception of higher likelihood of rebleeding after treatment, but the study showed that this difference was only significant when restricted to a 30-day period, and was likely a result of application of thrombolytic drugs (which were already being replaced by antiplatelet agents in good practice) and due to some patients having a lethally excessive wait period after failed coiling procedures. Beginning one year after surgery, only two instances of rebleeding were observed in the coiled group, indicating statistical equivalence to the clipped group, which had no rebleeding. Ongoing uncertainty over the long-term stability of coil embolism means that surgical clipping may still be preferred for younger patients; incidentally, this can eliminate the cancer risk from fluoroscopic ionizing radiation, to which younger patients would be more averse. However, given that aneurysm prevalence increases significantly with age, coiling is still the generally preferred surgery in those cases amenable to it.

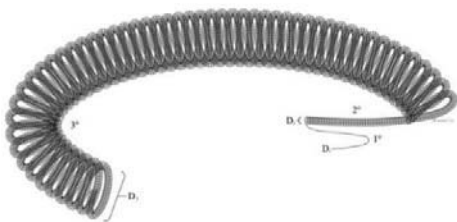


Fig. 8: Non-detached Guglielmi coils before insertion into catheter [10].

Non-surgical therapy

Failure to treat a ruptured aneurysm with surgical means will very likely result in death. For unruptured aneurysms not thought to be worth the risk of surgery, medical action can be taken to reduce the risk of rupture. This involves eliminating lifestyle risk

factors such as smoking, and reducing blood pressure to relieve aneurysmal stress. Drugs to reduce inflammation and blood pressure can also be prescribed. Aspirin has been shown to be effective in reducing incidence of aneurysm rupture, with an odds ratio of 0.82 versus no treatment (improving to 0.63 with 3 or more years of treatment) [17], while cholesterol-reducing statins have not [2].

Emerging Strategies

Keyhole microsurgery

As with many other types of surgery, benefits may be realized by conversion from open-craniotomy to minimally-invasive clipping, even when conversion to endovascular surgery is not realized due to various concerns. The instruments used in clipping can be engineered into a narrow tubular format for insertion through craniotomy sections that are much smaller than in precedent, and guided by similarly shaped microscopes. A 20-year study with 1,000 patients found that the keyhole approach had similar outcomes to open surgery, a slight reduction in need for retreatment, and a significant reduction in approach-related complications (as might be expected when the approach craniotomy is made smaller) [18]. One noticeable disadvantage is that unlike, for instance, the abdominal cavity, the cranium cannot be expanded with gas injection; only the previously mentioned technique of brain relaxation can allow expansion of the surgical workspace. This is especially problematic because poor illumination and coaxial orientation of instruments and light sources are noted problems. Advanced, detailed planning of the surgical approach is therefore fundamental for the success of this type of procedure [19].

Intracranial-intracranial (IC-IC) bypass

Despite the lack of benefit seen in stroke prevention, bypass is still considered to be a legitimate treatment for complex aneurysms without favorable endovascular treatment options. Evolution in treatment has led to a shift in approach: instead of diverting blood from outside the cranium, the blood supply can also be diverted from inside the cranium.

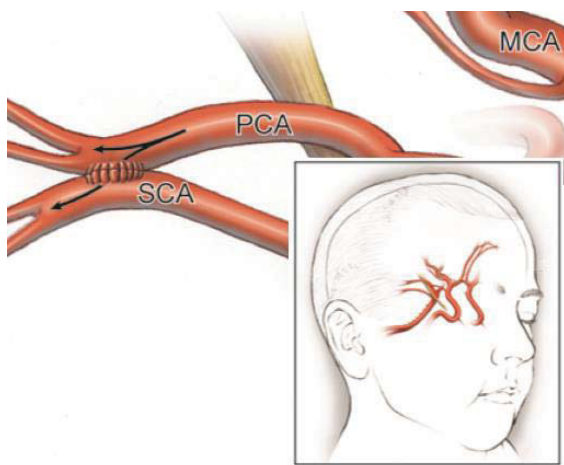


Fig. 9: In-situ IC-IC bypass from proximal segment of posterior cerebral artery (PCA) to distal segment of superior cerebellar artery (SCA) [20].

This type of surgery is more challenging to perform, and increases the number of cerebral vessels to be occluded, but shortens the required graft length and avoids problems related to vessel diameter. Techniques of IC-IC bypass dissimilar to EC-IC bypass include in-situ, where donor and recipient arteries are brought in side-to-side contact without a separate graft vessel, and reanastomosis, where the aneurysm is excised and the normal vessel ends are brought together end-to-end [6]. IC-IC bypass requires a craniotomy like EC-IC, but there is no need to incise the patient's neck or route an artery through a hole drilled in the cranium.

Endovascular flow diversion

Conceptually related to the bypass approach, the use of endovascular stents can divert blood flow around an aneurysm and induce aneurysmal thrombosis without causing ischemia. In most cases (79-92%) [20], blood flow to the aneurysm does not cease immediately. Rather, the stent provides a substrate for generation of a new vascular wall inner surface, completely occluding the aneurysm within 6 months in 69-76% of cases and within 1 year in >90%, even in wide-necked and giant aneurysms that may be impractically risky to treat with coiling or clipping [21], [22]. This inherently means that permeable stents of the type used ('flow diverters') are unsuited for ruptured aneurysms, as they will not quickly block hemorrhage, but also means that they can be placed over minor vessels without causing occlusion, as there will remain sufficient blood flow to prevent neointima formation. Stents can also be used in conjunction with coils, to hold them in place inside the aneurysm and prevent reflux. Despite the high cost of stents, and high rates of perforator infarction and hemorrhage in the middle cerebral artery and posterior circulation, flow diverters are expected to increasingly but not fully displace bypass surgery [6].




Fig. 10. Two flow-diverting stent models, A: Enterprise, B: Vision™ [23].

Liquid embolization

The predominant use of Guglielmi detachable coils is not entirely without problems: coil-induced thromboses may get loose and become problematically lodged away from the surgical site, the coils themselves may escape from the surgical site, or particularly fragile aneurysms may be ruptured during coiling [24]. Additionally, the platinum coils themselves are a somewhat expensive material.

One alternative is the use of liquid agents. These agents will frequently be shipped as a binary composition, which is mixed during or shortly before surgery to activate a solidification process. One of the key advantages of beginning in a lower-viscosity state is the ability to permeate small aneurysms, without being ejected back through the aneurysm's neck as might happen in coiling.

Historically, n-butyl cyanoacrylate (n-BCA), marketed as TRUFILL by Cordis Neurovascular, has been the most widespread liquid embolization agent. It is mainly being used in conjunction with coils to enable the use of fewer coils and smaller guidewires and catheters, rather than as the primary focus of embolization. When trialled, only one of about fifty patients suffered from agent reflux and subsequent arterial occlusion and cerebral infarction [25].

One of the modern front-runners in liquid embolization is Onyx, released by Micro Therapeutics, Inc., now a part of Medtronic. It is composed of EVOH, a copolymer of ethylene and vinyl alcohol, which is dissolved in dimethyl sulfoxide (DMSO) as an inhibitor and includes tantalum powder as a fluoroscopy contrast medium. Unlike n-BCA, Onyx is non-adhesive, allowing for

longer injection times and mid-surgery operational pauses. The agent is also less likely to accidentally entrap the delivery catheter tip than adhesive liquid embolic agents. Unfortunately, the DMSO inhibitor, which diffuses away from the aneurysm to allow the EVOH to solidify, is somewhat neurotoxic and can cause vasospasm and necrosis [26]. It is indicated for use in wide-necked aneurysms that may be problematic to clip or coil.

Calcium alginate gel, ALGEL, is an even newer agent, the liquid acid form of which polymerizes into a matrix upon the exposure of cations. It is a polysaccharide that occurs naturally in the cell walls of brown algae. Its advantage is that it causes occlusion in a purely mechanical fashion, without causing thrombosis [26].

Non-surgical therapy

Pharmaceutical advancements, including a better understanding of the formation mechanism and a better means for selectively inhibiting inflammation at the neuro-aneurysm site, may obviate the need for surgery altogether in some cases.

Given the rupture rate of small, difficult to treat aneurysms, and the high rate of asymptomatic aneurysms in the population, one of the objectives of pharmaceutical research is to provide drugs which reduce the likelihood of rupture. For example, Shimada et al. report that administration of the peptide hormone angiotensin-1-7 in mice reduced the incidence of rupture of artificially-induced aneurysms from 83% to 33% [27]. Angiotensin-1-7 plays a role, through complex interactions with various receptors, in reducing inflammation in the vascular wall. The benefit was still seen when the vasodilatory/hypotensive effect, which could

be expected to reduce rupture rate by reducing systemic blood pressure, was intentionally inactivated by failing to augment levels of a related peptide.

Assuming that endovascular surgery in some form remains the first line of treatment, another line of inquiry relates to enhancing the natural embolization by chemical or biological means. Zhang et al. reported therapeutic benefit when bone-marrow derived epithelial progenitor cells were transplanted into mice with aneurysms that had been previously treated by coil embolization [28]. They noted that a lack of complete re-endothelialization is a factor in aneurysm recurrence. To guide progenitor cells to the correct location, super-paramagnetic iron oxide nanoparticles were used as labels. Having been guided, the progenitor cells showed signs of speeding reconstruction of the inner vascular wall, noted by the ISAT group to be a time-critical process, with failure to heal having potentially fatal repercussions in the 30-day time span. The approach of specifically targeting problematic sites with pharmaceuticals in order to avoid systemic problems is likely to become more widespread as the emergent properties of nanostructured materials such as nanoparticles and carbon nanotubes become more well-understood.

Lifestyle trends may also have a role to play in protecting against aneurysms. As genetic screening becomes more commonplace, at-risk populations will have a more specific impetus to take preventative measures, such as exercise and salt intake reduction to reduce hypertension. Declining smoking rates will also be epidemiologically important.

Unmet clinical needs

Despite the invasiveness of the procedure compared to endovascular approaches, surgical clipping is still widely used. If the rebleed rate of coil and/or chemical embolization could be reduced to the level observed in clipping, or these methods could halt bleeding as immediately as clipping, surgeons could be more inclined to treat patients endovascularly.

To improve stability of the aneurysmal embolism, various coatings can be applied to the surface of detachable platinum coils. The first commercially available bioactive-coated coil, Matrix, used a polyglycolide-poly lactide copolymer coating with the hopes of inducing an inflammatory reaction, but clinical experience showed a higher rate of recanalization compared to bare coils. A later product, Hydrocoil, using cross-linked acrylamide/sodium acrylate, showed a reduction in primary poor outcome (measured by aneurysm remnant, recurrence and morbidity/mortality) to 28%, compared with 36% in the control [10].

The time required for revascularization after placement of a flow diverter is a major weakness. As observed in the ISAT, non-procedural bleeding was over 3 times more frequent in the 30-day period after surgery than in the next 11 months [15]. The first month, in which revascularization may be new or incomplete, is therefore a critical period for the prevention of rebleeding. Making the flow diverter surface more conducive to new vessel wall growth, such as including pharmaceuticals, surface coatings, or even stem cells, could prevent negative outcomes in this critical period.

Table 1: Comparison of neuroaneurysm treatment options.

Performance: ++ Good, -- Bad	Clipping	Coiling	IC-IC bypass	EV flow diversion	Liquid embolization
Invasive	yes	min.	yes	min.	min.
Scarring	-	++	--	++	++
Rebleeding	++	0	-	-	0
Complications	-	+	-	+	++
Difficult geometry	0	--	++	+	-
Cost	+	0	+	--	++
Improvable	-	0	-	++	++

Conclusion and outlook

Endovascular coiling and surgical clipping are the most common surgical procedures for dealing with neuroaneurysms. Extracranial-intracranial bypass has mostly been phased out, due to its demonstrated ineffectiveness in preventing stroke, which is partially due to the increased effectiveness of non-surgical treatment.

Since coiling is not always effective, clipping must remain in the surgical toolbox, although the trend towards minimal invasiveness is likely to continue, with robotic assistance being introduced and maybe even becoming the dominant approach, as has happened with prostatectomies.

Flow diversion will be more and more widely used, as its endovascular nature and indirect action appeal to the modern surgeon who demands a lower complication rate.

Given that the mnemonic inertia of bypass surgery may be the only thing keeping it from total extinction, it can be expected that this sort of revascularization will at some point be supplanted almost entirely, either with one or more endovascular procedures (stent-based flow diversion seems a likely candidate) or by non-surgical means.

It remains to be seen whether liquid-based embolization will displace coil embolization to any great extent, but it is probable that smart drug delivery will enable non-surgical therapy to displace neurosurgery under some conditions.

References

1. Caplan LR. *Subarachnoid hemorrhage, aneurysms, and vascular malformations*. Caplan's Stroke: A Clinical Approach. Cambridge University Press, 2016, pp. 439-476.
2. Chalouhi N, Hoh BL, Hasan D. Review of cerebral aneurysm formation, growth, and rupture. *Stroke* 44 (12): 3613-22, 2013.
3. Forsting M, Wanke I (ed). *Intracranial vascular malformations and aneurysms*. Berlin/Heidelberg: Springer-Verlag 2006.
4. Alshekhlee A, Sonal M. Hospital mortality and complications of electively clipped or coiled unruptured intracranial aneurysm. *Stroke* 41:1471-6, 2010.
5. Brinjikji W, Lanzino G, et al. Cerebral aneurysm treatment is beginning to shift to low volume centers. *J Neuroint Surg* 6:349-352, 2014.

6. Davies JM, Lawton MT. Advances in open microsurgery for cerebral aneurysms. *Neurosurgery* 74:S7-16, 2014.
7. Wong JH, Tymianski R, et al. Minimally invasive microsurgery for cerebral aneurysms. *Stroke* 46 (9):2699-706, 2015.
8. Mayo Clinic. Diseases and Conditions: Brain aneurysm. 2015 (www.mayoclinic.org/diseases-conditions/brain-aneurysm/basics/treatment/con-20028457) [Accessed 28 December 2016].
9. Rebstock Instruments GmbH. Aneurysm Clip System catalogue. (www.rebstock.de/fileadmin/pdf/Aneurysm_Clips.pdf) [Accessed 28 December 2016].
10. Mehra M, Spilberg G, et al. *Intracranial Aneurysms: Clinical Assessment and Treatment Options*. Biomechanics and Mechanobiology of Aneurysms. Berlin/Heidelberg: Springer-Verlag, 2011, pp. 331-372.
11. Bekelis K, Missios S, et al. Predicting inpatient complications from cerebral aneurysm clipping: the Nationwide Inpatient Sample 2005–2009. *J Neurosurg* 120 (3):591-8, 2014.
12. Gobble RM, Hoang H, et al. Extracranial-intracranial bypass: resurrection of a nearly extinct operation. *J Vasc Surg* 56 (5): 1303-7, 2012.
13. Grubb Jr RL, Powers WJ, et al. Surgical results of the carotid occlusion surgery study. *J Neurosurg* 118 (1):25, 2013.
14. Guglielmi G. Letter to the editor: Guglielmi detachable coils. *J Neurointervent Surg* 0 (1), 2014.
15. Molyneux A, Kerr R, et al. International Subarachnoid Aneurysm Trial (ISAT) of neurosurgical clipping versus endovascular coiling in 2143 patients with ruptured intracranial aneurysms: a randomised trial. *The Lancet* 360.9342: 1267-1274, 2002.
16. Lim YC, Kim BM, et al. Structural limitations of currently available microcatheters and coils for endovascular coiling of very small aneurysms. *Neuroradiology* 50 (5):423-7, 2008.
17. García-Rodríguez LA, Gaist D, et al. Antithrombotic drugs and risk of hemorrhagic stroke in the general population. *Neurology* 81:566–74 2013.
18. Fischer G, Stadie A, et al. The keyhole concept in aneurysm surgery: results of the past 20 years. *Neurosurgery* 68:45-51, 2011.
19. Perneczky A, Kindel S, et al. *Keyhole Approaches in Neurosurgery: Volume 1: Concept and Surgical Technique*. New York: Springer Science & Business Media, 2009.
20. Rodríguez-Hernández A, Huang C, Lawton MT. Superior cerebellar artery–posterior cerebral artery bypass: in situ bypass for posterior cerebral artery revascularization: Technical note. *J Neurosurg* 118 (5):1053-7, 2013.
21. D'Urso PI, Lanzino G, et al. Flow diversion for intracranial aneurysms a review. *Stroke* 42 (8):2363-8, 2011.
22. Brinjikji W, Murad MH, et al. Endovascular treatment of intracranial aneurysms with flow diverters: a meta-analysis. *Stroke* 44 (2):442-7, 2013.
23. Tremmel M, Xiang J, et al. Alteration of intraaneurysmal hemodynamics for flow diversion using enterprise and vision stents. *World Neurosurgery* 74 (2):306-15, 2010.

24. Standhardt H, Boecher-Schwarz H, et al. Endovascular treatment of unruptured intracranial aneurysms with Guglielmi detachable coils: short- and long-term results of a single-centre series. *Stroke* 39 (3):899-904, 2008.

25. Tomsick A et al. N-butyl cyanoacrylate embolization of cerebral arteriovenous malformations: results of a prospective, randomized, multi-center trial. *Am J Neurorad* 23 (5):748-55, 2002.

26. Vaidya S, Tozer KR, Chen J. An overview of embolic agents. In *Seminars in Interventional Radiology* 25 (03): 204-215, 2008.

27. Shimada K, Furukawa H, et al. Angiotensin-(1-7) protects against the development of aneurysmal subarachnoid hemorrhage in mice. *J Cereb Blood Flow Metab* 35 (7):1163-8, 2015.

28. Zhang S, An Q, et al. Therapeutic benefit of bone marrow-derived endothelial progenitor cell transplantation after experimental aneurysm embolization with coil in rats. *PloS One* 9 (2):e90069, 2014.

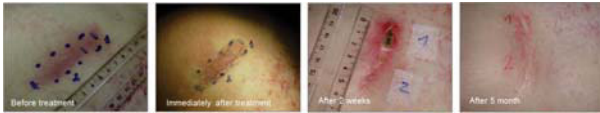


Electrochemotherapy — What is it? What is it used for? What is needed? What are alternative IGP approaches? What needs to be done to make it applicable for other applications?

Nazila Esmaceli, Electro-technic und Information Technology Faculty, Otto-von-Guericke University Magdeburg, E-Mail: nazila.esmaceli@st.ovgu.de

Introduction

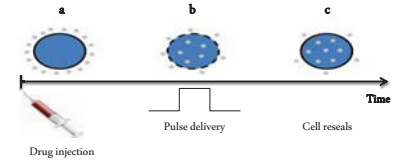
- **Electroporation (EP)**: when a cell is exposed to a sufficiently intense electric field for a sufficient duration, local defects in the cell membrane appear and become permeable to impermeable molecules. This physical method enables delivery of impermeable drugs, macromolecules and genetic material into the cell and is related to the induced transmembrane voltage.
- **Electrochemotherapy (ECT)**: An EP-based, local and non-thermal tumor ablation modality. It combines the **administration of a poorly permeant cytotoxic drug with the local application of electric pulses** that induce reversible EP, thus improving drug diffusion into cells. It is performed using either intratumoral or intravenous cytotoxic agents injection, followed by the application of electric pulses locally delivered to the target tumor via suitable sets of electrodes.
- ECT has been used in the treatment of subcutaneous lesions, cutaneous and non-cutaneous metastases, and primary tumors from tumors independent of histology.



Two tumor nodules of breast chest wall recurrence treated by ECT

Principles

1. Membrane non-permeant or poorly permeant cytotoxic drug injection: **Bleomycin** (intratumoral or systemic) or **Cisplatin** (intratumoral).
2. 1 to 20 short and intense electric pulses application. **100 - 1000 V**, lasts 100µs, **1 - 5000 Hz**: 1 to 10 minutes after intratumoral injection, and 8 to 28 minutes after systemic injection.
3. Relocation of charges on the cell membrane, which causes the buildup of transmembrane voltage. After a certain voltage, a sufficiently strong electric field through the membrane is established. This leads to rapid creation of pore within a few seconds to several minutes which allows passage of drug.
4. Membrane reseals, and anticancer drug exert its cytotoxicity.



Instruments

1. Electrical pulse generator.
2. Electrodes.

- An example:
- The Cliniporator™ (IGEA, Carpi, Italy):

 1. A console unit.
 2. A power supply unit.
 3. An applicator (electrodes which are named **plate an needle electrodes**).



The electric pulse delivery unit Cliniporator™

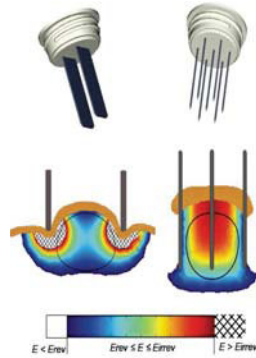



Plate electrodes and Hexagonal needle electrodes

New Applications: Deep-Seated Tumor Treatment

Challenges

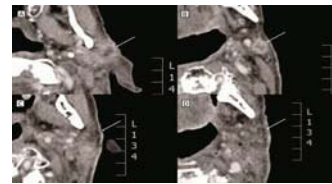
1. Tissue conductivity determination.
2. Conductivity changes due to EP.
3. Threshold determination for EP (reversible, irreversible).
4. A function of pulse parameters (duration and number of pulses).
5. Accuracy and robustness of a treatment plan (accuracy of positioning of electrodes).
6. Cost.



18 mm electrode with retractor tip used for drilling into bone. Shown with a bone model.

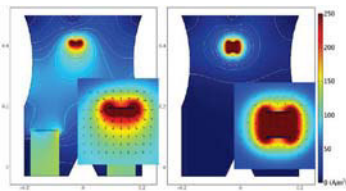
Requirements

1. High skilled and experienced surgeons.
2. Modified instruments.
3. Treatment planning with dedicated software to indicate electrodes' positioning and the required EP pulse conditions.
4. Intraoperative imaging (x-ray, ultrasound, CT and MR imaging).
5. Synchronization of the pulse deliver to the heart absolute refractory period for metastases in abdomen.



CT images before (A, B) and after (C, D) ECT

ECT vs Radiofrequency & Microwave Ablation (RFA & MWA)



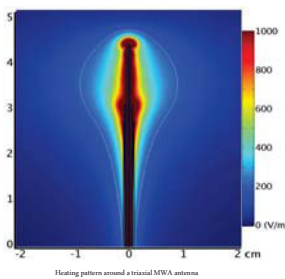
Simulated initial current densities of RFA in monopolar (left) and bipolar (right) modes

Treatment area

- RFA and MWA: Mainly tumors in internal organs like liver, bone, etc.
- ECT: Mainly cutaneous and subcutaneous tumors.

Time

- More time to perform ECT in the case of deep-seated tumors (because of the requirement of **multiple needles placement**).



Heating pattern around a triaxial MWA antenna

Temperature

- RFA: Thermal tumor ablation with **low intratumoral temperature** (between 60 °C to 100 °C).
- MWA: Thermal tumor ablation with **high intratumoral temperature** (150 °C).
- ECT: a **non-thermal** approach for treatment of tumors (main advantage of ECT).

Frequency range

- RFA: Medium frequency alternating current (350 - 500 KHz)
- MWA: 900 - 2450 MHz
- ECT: 1 - 5000 Hz

ECT Application in the future

- ECT development for big and deep-seated tumor treatment


- ECT combination with other treatment modalities:

1. Using ECT before the surgery to downsize the tumor.
2. Using ECT after the surgery to treat remaining mass.
3. Using ECT with other EP-based methods like immunomodulatory effect (immunogene electrotransfer) to increase systemic antitumor effectiveness.


- Using ECT to treat other diseases in the case of drug delivery



Treatment 3-D planning for registration and navigation (A) Navigation was used to accurately access the planned skin entry points and direction of electrodes (B) Positioning of navigation system needle and first needle electrode (C) and the final positioning of 18 five needle electrodes (D)



Retractable brain electrodes. A) Rendering of the electrode in fully retracted state. B) Electrode in fully extended state. Recommended voltage is 1000 V for the fully extended electrode.



A prototype of the new grid electrode

Conclusion

ECT is now at the stage of palliative and not curative treatment in most indications, or in the case other treatments have failed. It is an effective treatment of tumor lesions located in the skin or subcutaneous tissue, both primary and metastatic, regardless of the histological type of the tumor or previous treatments. It has also shown its effectiveness in the case of treating deep-seated tumors. On the other hand, ECT offers considerable advantages, like short time hospitalization, repeating several ECT cycles without precluding other types of treatment, good cost/benefit ratio and no serious adverse events or severe toxicity. However, because of novelty of this method, more research and investigation are needed to develop ECT.

References

1. Sersa G, Miklavcic D, Cemazar M, Rudolf Z, Pucihar G, Snoj M. Electrochemotherapy in treatment of tumours. European Journal of Surgical Oncology (EJSO). 2008 Feb 29;34(2):232-40.
2. Cadossi R, Ronchetti M, Cadossi M. Locally enhanced chemotherapy by electroporation: clinical experiences and perspective of use of electrochemotherapy. Future Oncology. 2014 Apr;10(5):877-90.
3. Miklavcic D, Davalos RV. Electrochemotherapy (ECT) and irreversible electroporation (IRE)-advanced techniques for treating deep-seated tumors based on electroporation. Biomedical engineering online. 2015 Aug 27;14(3):1.
4. Groselj A, Kos B, Cemazar M, Urbancic J, Kragej G, Bosnjak M, Veberic B, Strojanc P, Miklavcic D, Sersa G. Coupling treatment planning with navigation system: a new technological approach in treatment of head and neck tumors by electrochemotherapy. Biomedical engineering online. 2015 Aug 27;14(3):1.
5. Mali B, Gorjup V, Edhemovic I, Breclj E, Cemazar M, Sersa G, Strazisar B, Miklavcic D, Jarm T. Electrochemotherapy of colorectal liver metastases-an observational study of its effects on the electrocardiogram. Biomedical engineering online. 2015 Aug 27;14(3):1.

Electrochemotherapy – What is it? What is it used for? What is needed? What are alternative IGP approaches? What needs to be done to make it applicable for other applications?

Nazila Esmaeili

Electro-technic und Information Technology Faculty

Otto-von-Guericke University Magdeburg

E-Mail: nazila.esmaeili@st.ovgu.de

Abstract

Electroporation-based cancer treatment approaches are undergoing intensive research in the field of drug delivery. Their first biomedical application in the treatment of cancer came in the form of electrochemotherapy (ECT). ECT is a local treatment of cancer which combines the use of a medical device with pharmaceutical agents to obtain local tumor control in solid cancers. Several new clinical studies proposed ECT as a new and complementary therapeutic option for controlling cutaneous and subcutaneous metastases. On the other hand, it is also becoming a practical method for treatment of internal, deep-seated tumors and tissues. A review on this new method, needed instruments, alternative Image Guided Procedures (IGP) approaches and future perspectives and recommendations are discussed in this paper.

Keywords:

Electrochemotherapy, Image Guided Procedures

Abbreviations:

EP: Electroporation, ECT: Electrochemotherapy, IGP: Image Guided Procedures, INSPECT: International Network for Sharing Practice in Electrochemotherapy, GIDO: Gruppo Italiano Dermatologico Oncologico, SOP: Standard Operating Procedures (SOP), ESOPE: European Standard Operating Procedures for ECT, Rev: Reversible, Irrev: Irreversible, CT: Computed Tomography, MRI: Magnetic Resonance Imaging, PET: Positron Emission Tomography, PEMF: Pulsed Electromagnetic Field, RFA: Radiofrequency Ablation, MWA: Microwave Ablation, EM: Electromagnetic.

1. Introduction

When a tissue is exposed to a sufficiently large electric field for an adequate duration, due to its geometrical and material properties, transmembrane voltage is induced across the cell plasma membrane. Then the local defects in the cell membrane appear and become permeable to agents that otherwise cannot pass through it. This phenomenon is commonly known as electroporation (EP) [1, 2].

There are two types of EP: reversible and irreversible. The duration of the pulses and electric field intensity determine whether the structural changes in the cell membrane are irreversible, leading to cell death, due to the loss of homeostasis, or reversible, allowing cells to survive [3].

The universal effectiveness of EP has made it a popular technique for loading cells with substances that are otherwise not possible or difficult to transfer into the cells. In this regard, EP-based technology for biomedical applications starts to grow and go through investigations in the field of drug delivery and gene therapy, like gene electrotransfection, non-thermal irreversible electroporation and electrochemotherapy (ECT) [2, 4, 5, 6, 7].

The effectiveness of these kinds of therapies depends on two factors: First, the electrical characteristics such as amplitude and duration of electric pulses, number of pulses and repetition, as well as type of electrodes which are used. Second, cell and tissues characteristics, like shape, size, and cytoskeleton structure and membrane

composition, that want to perform the EP on it [5, 8].

ECT is a local and non-thermal tumor ablation modality, which combines the administration of a poorly permeant cytotoxic agent with the local application of electric pulses that induce reversible EP, thus improving drug diffusion into cells [9, 10, 11, 12]. Through this method, the efficacy of chemotherapeutic medications increases by the use of electrical pulses which provides good local tumor control [13, 14]. The underlying chemical and physical processes associated with the effect of large electric fields to cells in tissue are still not fully explained. However, the predictions of theoretical models and the results of experimental studies show that the application of an appropriate electric field to the tumor leads to the transient opening of aqueous pores on the cell membrane which allows the passage of drugs, genes, or molecular probes [15].

ECT effectiveness has been approved in a large variety of tumors. In this regard, the first clinical study was published in 1991 on head and neck tumor nodules. It has been used in the treatment of subcutaneous and cutaneous lesions and metastases from tumors independent of histology. Now it is applied for treating melanomas, sarcomas, and other types of skin cancer, cervix leiomyosarcoma and breast cancer. Figure 1 shows a result of an actual treatment using ECT. This technique can improve the quality of patient's life as a palliative procedure, when all other treatment modalities have failed or proved insufficient [2, 9, 11, 14]. Furthermore, its development is focused onto treatment of bigger as well as deep-seated tumors; in internal organs or at least 1 cm below the skin. Figure 2 shows the potential application of ECT [10].

In ECT development, a close collaboration, experience and knowledge exchange among experts in the fields of oncology, biology, biophysics, physical chemistry and electrical, biomedical engineering and informatics is needed [8]. Nowadays, this modality is available at some European centers for the treatment of patients with cutaneous metastases from various tumor histotypes. It was estimated that in the year 2011 about 2000 patients will be treated by ECT. In Europe exist also two patient's databases; the International Network for Sharing Practice in ECT (INSPECT) database and Italian

Melanoma Group and Gruppo Italiano Dermatologico Oncologico (GIDO) [11, 16].

Following a review of ECT procedure in the terms of practical implementation and technical requirements, new application of ECT, alternative Image Guided Procedure (IGP) approaches and what needs to be done for further application in the future are discussed.

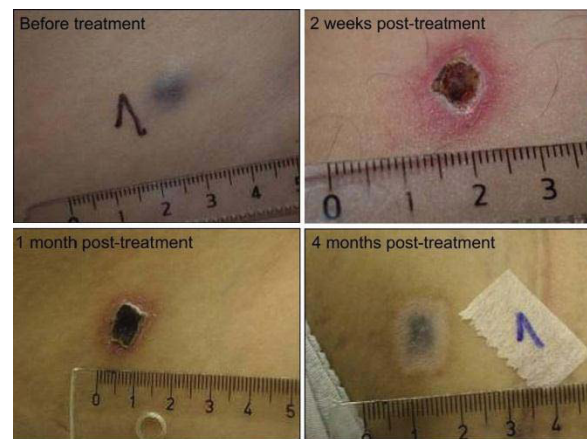


Figure 1. Melanoma treatment with ECT.

2. Practical Implementation and Technical Requirements

2.1. Principles and treatment Procedure

ECT is a procedure that combines a membrane non-permeant or poorly permeant cytotoxic drug having an intracellular target with the use of short and intense electric pulses which are causing increased membrane permeability [9, 11]. It is performed using either intratumoral or intravenous cytotoxic drugs injection, followed by the application of electric pulses locally delivered to the target tumor via suitable sets of electrodes. Upon the application of external electric pulses to cells, the electric field causes relocation of charges on the cell membrane. This causes the buildup of transmembrane voltage (termed induced transmembrane voltage, which is superimposed to the cells' normal resting transmembrane voltage or resting membrane potential). The increase in transmembrane voltage follows Schwann's equation, and in areas, where transmembrane voltage exceeds a certain voltage, a sufficiently strong electric field through the membrane is established [5, 17].

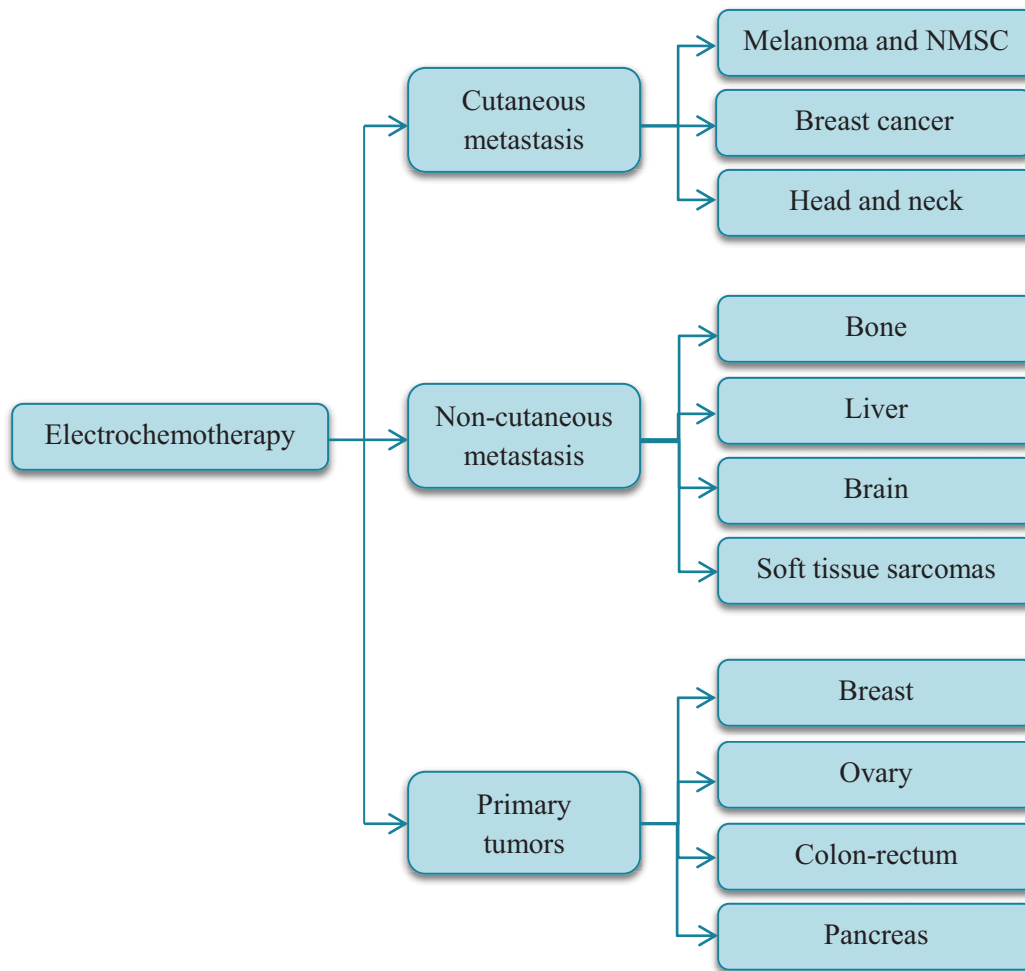


Figure 2. Potential application of ECT for tumor treatment

This leads to pore formation which allows the passage of water, charged molecules, as well as larger molecules. They are created rapidly and disappear within a few seconds to several minutes after exposure to the electric field. Although these pores are too small and short-lived to be observed using conventional or electron microscopy, indirect evidence supporting their existence comes from simulations of lipid bilayers using molecular dynamics simulations. Cellular membranes can remain permeable, for large and charged molecules, for minutes after the external electric field delivery stops. The mechanism of membrane resealing or repair requires active cellular mechanisms and therefore also energy. So, a possible explanation of the relatively long term permeability of cell membranes is chemical alteration of membrane lipids [5, 18].

The basic principles for effective treatment with ECT are: First, the pharmacological peak of the injected cytotoxic drug reaches the tumor at the time of application of short and intense electric pulses (the range between reversible and irreversible electropermeabilization threshold values). Second, the entire tumor mass is sufficiently covered by the electric field (Figure 3) [2, 9, 11, 17]. On the other hand, the application of electric pulses to tissues causes a transient but reversible reduction of blood flow. The 80% decline in tumor blood flow immediately after the application of electric pulses induces drug entrapment in the tissue for several hours, providing more time for the drug to act. Tumor blood flow returns to normal in tumors within 24 hour after the application of electric pulses; whereas in normal tissue the restoration is faster, within several hours [2].

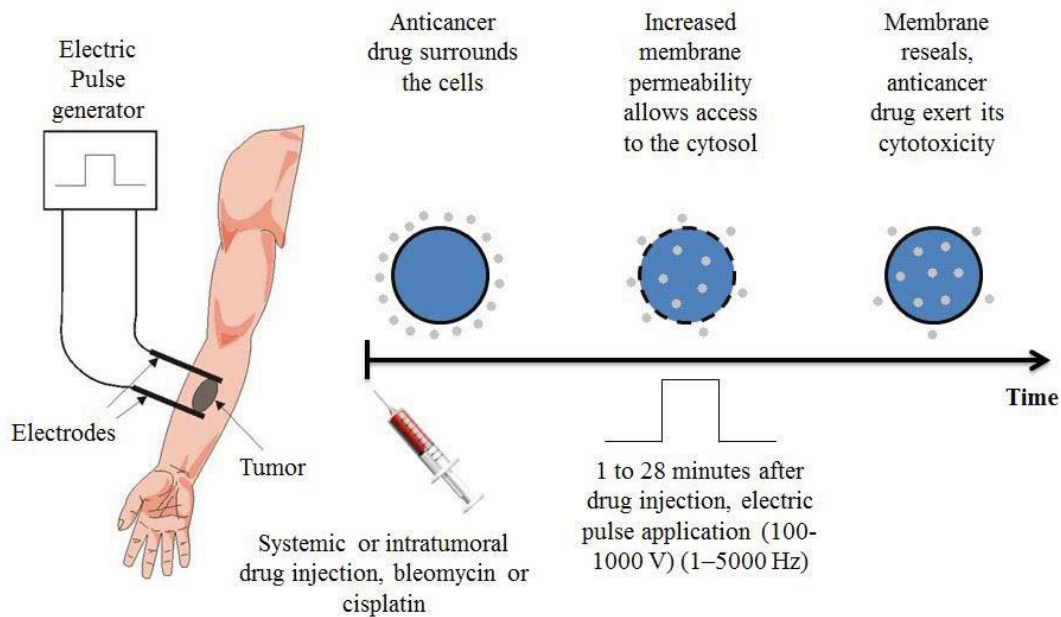


Figure 3. Principle of ECT

In addition, the used chemotherapeutic agents clinically, predominantly affect actively dividing cancer cells and to a lesser extent the largely non-dividing population of normal cells in the surrounding tissue [4].

Although ECT efficacy both in human and veterinary oncology was well demonstrated, differences among treatment protocols, the lack of defined operating procedures and the use of different pulse generators prevented the widespread adoption of ECT in the clinical setting for a while [5, 18]. Therefore, there was a critical need to have extremely accurate procedures for either systemic or local cytotoxic drug delivery, followed by the application of electric pulses, and also for each specific clinical condition [2]. In this regard, Standard Operating Procedures (SOP) have been developed and validated by the European Standard Operating Procedures for ECT (ESOPE) study. This reference describes with precision the timing, dosage, and value of the electric field, as well as the evaluation of the treatment response for various diseases [5, 14, 19]. The SOP decision tree is to help clinical staff to make decisions to treat the patient, based on the size, number and thickness/ depth of nodules to be treated. ECT procedure can be performed in 30 minutes both in local or general anesthesia, which should be decided by the treating surgeon, but few and smaller nodules are recommended to be treated in

local, while others in general anesthesia [5, 18].

2.2. Instruments

ECT is performed with the help of electrical pulse generator and different types of electrodes. Following these instruments are explained in detail:

2.2.1. Electric Pulse Generator

EP of cells is predominantly induced by pulsed electric fields, which are generated with the train of square wave electric pulses of sufficient amplitude establishing local electric field (hundreds of V/cm) [3].

An electric pulse generator generates various amplitude of electric pulse and then applies it to the tumor cells with the help of electrodes, in order to let EP phenomenon happens [5, 19]. In clinical settings, short and intense electric pulses, as well as monopolar and direct current are used. Also, in order to predict electric field distribution in biological tissues, numerical modeling is currently the only efficient way, as these are characterized by inherently nonlinear, non-homogeneous, and in some cases, anisotropic dielectric properties [4, 5].

Base on SOP of ECT, the emitted impulse lasts 100 μ s. The number of impulses varies between 1 to 20 and their amplitude between

100–1000 volts. Also, the frequency used is between 1–5000 Hz [2, 20].

2.2.2. Types of electrode

Different sets of electrodes for different nodule with different depth, size, and shape are available, which are named plate and needle electrodes. Different electrode configurations enable sufficient electric field coverage of the whole tumor mass in order to permeabilize as many as possible cells within the tumors. Figure 4 illustrates different types of electrodes [11, 20].

Plate electrodes are applied for the treatment of superficial or skin lesions. The depth of permeation of the effective electric field is somewhat small, and it depends on the distance between the electrodes: the greater the distance, the deeper the penetration of the electric field into the tissue, given that a larger voltage needs to be applied between both electrodes [2].

Needle electrodes are of two kinds: needles are positioned either in two parallel rows (perpendicular array) or in a circular (hexagonal) array. In contrast to plate electrodes, needle electrodes should be placed in throughout the tumor tissue up to the deep tumor border (up to 3 cm deep). Hexagonal configuration needle electrodes are used in the treatment of larger tumors, while linear configuration needle electrodes are used in treatment of small nodules [2, 5].

One important point is that regardless of type of the electrode, the electric field is highest around the electrode and between the electrodes, but becomes less very rapidly outside the electrode array (Figure 4). Therefore, the whole tumor can be treated in an efficient manner by moving and placing electrodes nearby for each sequential electric pulse application, if the tumor is larger than the distance between the electrodes. Because of the structural heterogeneity of tissues which is including tumors, the electric field that should be set in tumors for the permeabilisation of cells is hard to determine. Thus, it is important to apply the suggested pulse amplitude for different types of electrodes. This information is provided by the manufacturers of clinical electroporators [2, 16].

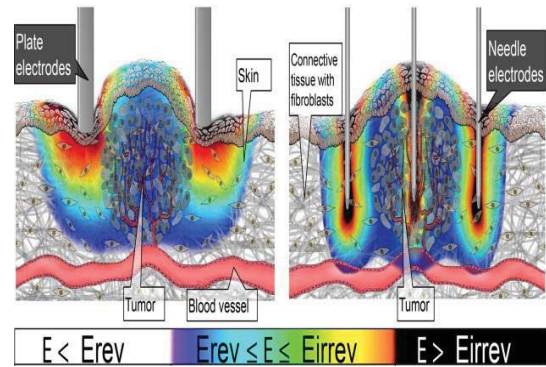


Figure 4. Electric field distribution in and around the tumor tissue during the application of electric pulses for plate (left) and hexagonal needle electrodes. The distribution is indicated with the rainbow color scale.

2.2.3. An Example

The Cliniporator™ (IGEA, Carpi, Italy) is introduced by (ESOPE) study to perform ECT in clinical practice. This device is exclusively employed in European Union. Cliniporator™ consists of a console unit, a power supply unit for supplying the current and an applicator (needles) for placement on the skin. This device is computer controlled. Additionally, this is the only device that offers the control of the pulses delivered on a screen, just after the delivery of the pulses. Therefore, the effectiveness of each individual EP can be observed on the monitor to prevent excess current for patient safety. The scheme of this device is illustrated in figure 5 and 6 [11, 18, 20].

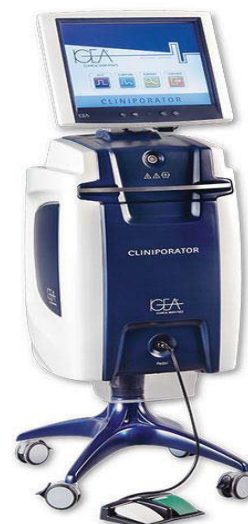

Figure 5. The electric pulse delivery unit Cliniporator™

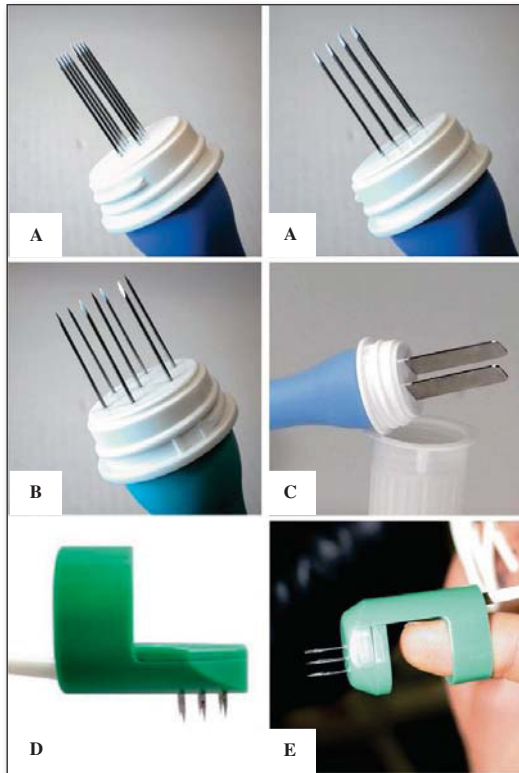


Figure 6. A: Linear needle electrodes. B: Hexagonal needle electrodes. C: Plate electrodes. D: Finger electrodes with perpendicular needles. E: Finger electrodes with axial needles.

2.3. Cytotoxic Agents

Suitable candidates for ECT are limited to those drugs that are hydrophilic and have lack transport systems in the membrane [2]. Hence, several chemotherapeutic drugs were tested on cells for potential application in combination with EP; these include daunorubicin, doxorubicin, etoposide, paclitaxel, etoposide, actinomycin D, Adriamycin, mitomycin C, 5-fluorouracil, vinblastine, vincristine, gemcitabine, cyclophosphamide, carboplatin, cisplatin and bleomycin. However, between all candidates only two of these drugs have been identified to date for ECT of cancer patients: bleomycin and cisplatin [2, 20].

Bleomycin can be delivered intravenously ($15,000 \text{ IU/m}^2$ in a bolus in 30–60 s) or locally through intratumoral injection. Intratumoral bleomycin should be administered in the form of solution (1000 IU/ml), in a dose of 1000 IU/cm^3 in lesions $< 0.5 \text{ cm}^3$, 500 IU/cm^3 in lesions $\geq 0.5 \text{ cm}^3$ and $\leq 1 \text{ cm}^3$, and 250 IU/cm^3 in lesions $> 1 \text{ cm}^3$.

Cisplatin (2 mg/ml) is only administered intratumoral. The dose of cisplatin also depends on the size of neoplastic lesions. Lesions larger than 1 cm^3 should be treated with a dose of 0.5 mg/cm^3 , those $\geq 0.5 \text{ cm}^3$ and $\leq 1 \text{ cm}^3$ should be treated with a dose of 1 mg/cm^3 , and for tumors smaller than 0.5 cm^3 , a dose of 2 mg/cm^3 should be applied [5].

When the drug is administrated systemically, electric pulses should be delivered to the tumor site during the pharmacokinetic peak, which was reported to be between 8 and 28 minutes in humans; for intratumoral application, however, the pulses need to be delivered from 1 min to 10 min after drug injection [2, 11].

3. Advantage and Disadvantage of ECT

3.1. Advantages

Recent studies have evaluated the effectiveness of several ablative skin-directed therapies and clearly showed the same, or even superior, effectiveness of ECT over photodynamic therapy, radiotherapy, intralesional therapy, and topical therapy. This method is suitable for patients with severe comorbidity and/or patients of an advanced age who have already exhausted all other treatments. On the whole, the quality of life of patients is improved by this procedure. The procedure is associated with a short hospital stay. The side effects are minor and most patients do not require analgesics. In most cases, there is only a temporary reddening of the skin and the injection sites of the electrodes. Furthermore, in contrast to radiotherapy, repeatability is possible in the case of this method. Also, the favorable cost-benefit ratio makes this method interesting [16, 20].

3.2. Disadvantages

In the case of using general anesthesia, the procedure is associated with common anesthesia-related risks. The use of intravenous bleomycin can develop pulmonary fibrosis, particularly as this treatment is administered to patients who have previously received radiation therapy and who are old. The electrode used during ECT is a disposable instrument which is not particularly inexpensive. Due to increased tumor decomposition in the case of extensive ECT in particular, the formation of large ulcers is possible. As the use of ECT is palliative and

not curative, it is possible that the treatment will have to be repeated, when the metastases become progressive over time. Also, in earlier studies ECT was not recommended in patients with cardiac pacemakers and patients on anticoagulant therapy for safety reasons [2, 20].

4. New Applications of ECT

New studies in two past years tried to add new characteristics to ECT, in order to make it more effective rather than the conventional form for different cancer treatments. Here, short review of these studies is provided:

4.1. Large Tumors

In 2014 the prototype of a new grid electrode was proposed, which is suitable for treating large, tumor-infiltrated skin surfaces as in breast cancer patients with chest wall metastases after mastectomy. According to the tests in different in vitro models, this new device allows applying the voltage pulses more quickly and homogeneously in comparison with standard pulse applicators. Also, it can be easily connected to an existing and widely adopted electric pulse generator (figure 7). Furthermore, this new grid electrode showed an improvement in ECT application [15].




Figure 7. A prototype of the new grid electrode

4.2. Deep-seated Tumors

Recently many researches have been focused on treating non-superficial tumors using ECT, like liver and bone metastasis, to treat them with the help of minimally invasive procedures. The main point is that in these situations, procedures are become more complex. In a comprehensive review of advanced techniques for treating deep-seated tumors based on EP in 2015, the current challenges in performing these treatments for

these types of tumors were named as following:

Tissue conductivity determination (necrotic regions, vasculature, micro-heterogeneities); conductivity changes due to EP (amount and dynamics); threshold determination for EP (reversible, irreversible) also as a function of pulse parameters (duration and number of pulses); and the accuracy needed for treatment planning, positioning of electrodes, which consequently dictates also accuracy and robustness of a treatment plan. Hence, it was mentioned that a holistic analysis of imaging, treatment planning, and clinical feedback can make this technology platform available for widespread use by clinicians and provide the best outcome and benefit for the patient [1].

In another study in 2014 clinical experiments and perspective of use of ECT was investigated. The following aspects were explained as important points for non-superficial metastasis:

1. Treatment needs to be carefully planned with dedicated software that indicates where to position electrodes and the required EP pulse conditions.
2. Correct spatial positioning of electrodes, usually individual long needles, requires skill and the support of intraoperative imaging: x-ray, ultrasound or CT (Computed Tomography) imaging.
3. In monitoring the effect of ECT for deep seated metastases, the use of imaging is mandatory. Nevertheless, the healing process is different from thermal ablation technologies inducing tissue necrosis, thus image interpretation and time interval for repeated examinations need to be that they are performed using CT, MRI (Magnetic Resonance Imaging) or CT/PET (Positron Emission Tomography).
4. The treatment of metastases localized to the abdomen requires synchronizing the pulse deliver to the heart absolute refractory period to avoid interference with the heart electrical activity [5].

In order to help locating the electrode precisely, a new technological approach in 2015 was introduced in treatment of deep-seated head and neck tumors by ECT with the help of both treatment planning and navigation system. Long single needle electrodes were used to perform the procedure and also a treatment plan, which provided the information on the optimal configuration of

the electrodes to adequately cover the tumor with electric field (figure 8). The results showed that the navigation system helped the surgeons to identify the exact location of the tumors, and helped with the positioning of the long needle electrodes during their insertion, according to treatment plan [6].

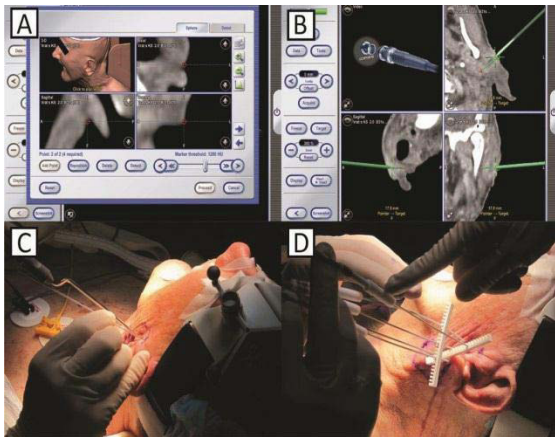


Figure 8. Treatment 3-D planning for registration and navigation (A) Navigation was used to accurately access the planned skin entry points and direction of electrodes (B) Positioning of navigation system needle and first needle electrode (C) and the final positioning of all five needle electrodes (D).

The effect of ECT of deep-seated tumors located close to the heart on functioning of the heart was investigated in 2015 for the first time. During this study, changes in several electrocardiographic signals and heart rate variability parameters of 10 patients with colorectal liver metastases treated with ECT were evaluated. No major heart rhythm changes (i.e., induction of extrasystoles, ventricular tachycardia or fibrillation) or pathological morphological changes (i.e., ST segment changes) indicating myocardial ischemia were found. Only minor effects of intra-abdominal ECT treatment on functioning of the heart were found. They were expressed as statistically significant but clinically irrelevant changes in heart rate and long-term heart rate variability parameters and were as such not life-threatening to the patients. [6].

4.3. Pulsed Electromagnetic Field

For the first time in 2016, ECT was performed using Pulsed Electromagnetic Field (PEMF) in mouse melanoma in vivo. In this regard,

noninvasive EP was performed by magnetic field pulse generator connected to an applicator consisting of round coil. Subcutaneous mouse B16F10 melanoma tumors were treated with intravenously injection of cisplatin (4 mg/kg), PEMF (480 bipolar pulses, at frequency of 80 Hz, pulse duration of 340 μ s) or with the combination of both therapies (ECT – PEMF + cisplatin). At the end the results in mouse melanoma model in vivo demonstrate the possible use of PEMF induced EP for biomedical applications, such as ECT. The main advantages of EP mediated by PEMF are contactless and painless application, as well as effective EP compared to conventional one [3].

5. Alternative Image Guided Procedure (IGP) Approaches

ECT is of course not the only technique available for local treatment of internal tumors. These local therapeutic options are available, from surgery and radiotherapy as prevalent, to thermal ablation techniques, like radiofrequency ablation (RFA), microwave ablation (MWA), which can be performed minimally invasively. Furthermore, cryosurgery and laser therapy can be other options for local cancer treatment [1, 4, 16].

A comparison between ECT, RFA and MWA is provided in the following:

These three techniques work with complete different principles.

ECT works based on non-thermal reversible EP and combines low permeable cytotoxic drug with the application of electric pulses to kill the tumors [13].

RFA and MWA both are thermal tumor ablation techniques, but their heating mechanisms are quite different. In RFA a needle electrode is delivered an electrical current in the radiofrequency range under imaging (Ultrasound, CT and MRI) or surgical guidance. This produces heat-based thermal cytotoxicity based on a creation of complete electrical circuit through the body. The critical tissue properties for RFA are electrical conductivity and thermal conductivity. On the other side, MWA is a special case of dielectric heating, where the dielectric material is tissue. When an alternating electromagnetic (EM) field is applied to an imperfect dielectric material, dielectric heating occurs. In tissue, heating take place because the EM field forces water molecules in the tissue to oscillate.

Hence, the best heating effect is achieved in tissues with a high content of water (e.g., most solid organs) and the worst is observed in fat. Another mechanism of MWA function is ionic polarization with conversion of kinetic energy into heat. A larger, more homogeneous ablation zone that is easily predicted is achievable and the heat-sink effect is attenuated. For MWA, the important properties are relative permittivity and effective conductivity. It is crucial to note that effective conductivity is different than the electrical conductivity in RFA. Radiofrequency electrical conductivity refers to an alternating flow of electrons, while effective conductivity encompasses effects related to the rotation of dipoles. Hence, RF heating requires an electrically conductive path while microwaves do not; thus, microwaves are capable of propagating through materials with low or zero conductivity (figure 9) [21, 22].

The main focus of ECT is to control and treat different cutaneous and subcutaneous lesions and metastasis. Only in these past few years it becomes a practical method for treating internal and deep-seated tumors [1]. RFA is mainly used to treat tumors in internal organs like liver, lung, kidney and bone. Then, because of some limitation of RFA which affects its efficiency, MWA becomes a new technique for this kind of tumors [21].

In the case of temperature, temperature in RFA is between 60 °C to 100 °C and result in almost instant coagulation necrosis (low intratumoral temperature). For the MWA, the temperature can exceed 150 °C (high intratumoral temperature) [21, 22]. However, due to heat sink effect, thermal ablation techniques are not recommended in all situations. For instance, RFA is not recommended in the vicinity of major hepatic vessels and leads to frequent tumor recurrences. Therefore, ECT provides a non-thermal approach for treatment of tumors in such locations. This is the main advantage of ECT in comparison with thermal ablative methods [4].

The frequency range of ECT is lower than two other ablative modalities (1 or 5000 Hz). RFA applies medium frequency alternating current (350-500 KHz) and MWA uses frequency between 900 to 2450 MHz [20, 21].

The effectiveness and safety have brought ECT into guidelines for the treatment of

different cutaneous and subcutaneous tumor. In the case of internal and deep-seated tumors and from the point of view of the clinicians, the main challenge of applying ECT is that currently this procedure takes too long in comparison with other minimally-invasive procedures such as RFA or MWA. This is due to the requirement of multiple needles placement for ECT whereas in RFA and MWA, only one probe is inserted [1, 4, 16]. Another point is that between these three modalities, MWA is the only technique that can treat multiple lesions simultaneously [22].

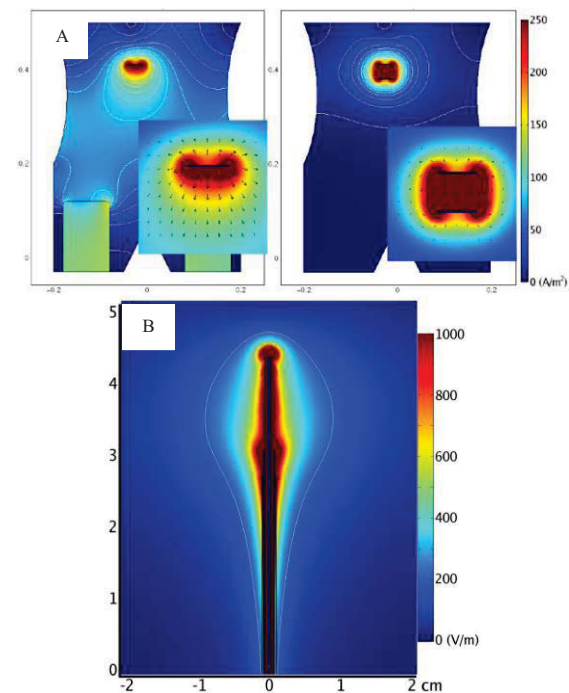


Figure 9. A: Simulated initial current densities of RFA in monopolar (left) and bipolar (right) modes. B: Heating pattern around a triaxial MWA antenna.

6. Make ECT applicable for other applications in Future

ECT is now at the stage of palliative and not curative treatment in most indications, or in the case other treatments have failed. Also it is in its early phase of clinical acceptance, currently the focus being on skin tumors and metastasis. However, further work is required. In this regard, treating deep-seated tumors needs more effort, time and resources. First the effectiveness of applying ECT in comparison with other treatments should be considered. Because as it was mentioned before,

placement of ECT needles is more complicated and time consuming than other IGP approaches. On the other side, even though the technology of image guided transcutaneous insertion of electrodes is available, pretreatment planning development for ECT is still in its early development. Hence, designing new electrodes and needles, using imaging modalities and treatment planning can be helpful to develop ECT in the clinical practices. However, besides of adding new features to the conventional form of this approach, the usability and price should be considered.

One idea to develop the use of ECT and also have a successful tumor treatment is to combine this technique with other modalities like surgery. Using ECT before the surgery to downsize the tumor can facilitate surgical interventions. Additionally, ECT would be used after surgical removal of tumor to treat remaining mass. Furthermore, based on the several reports from animal models, another combination can be the use of ECT as radio sensitizing approach. Therefore, ECT could, by increased intratumoral accumulation, potentiate radiation response of tumors without normal tissue damage [18]. One of the novel ideas is also to combine ECT with other EP-based methods like immunomodulatory effect (immunogene electrotransfer) to increase systemic antitumor effectiveness of ECT, which is on a great investigation to make it applicable for the clinical practices [16].

ECT is one EP-based method just for cancer control. As another idea, one possibility in the future might be the use of EP-based therapies in order to deliver the medications directly to the special organs or parts of the body, which are fighting with special diseases apart from cancer. For instance in the case of Alzheimer, researcher found the specific area in the brain which is responsible for this disease. Hence they started to plan the treatment and produce the drugs. The use of EP-based methods might be practical to deliver the more effective but less permeable drugs to the brain in the case of Alzheimer. Therefore, changing the components and chemical structures of the drugs in the case of disease with limited treatment options will not be a problem in the future, because we know how to administrate these drugs. This idea will need a comprehensive study on requirements to

modify the instruments, especially for having a minimal invasive procedure.

7. Conclusion

Besides some limitations of ECT, studies showed that it is an effective treatment of tumor lesions located in the skin or subcutaneous tissue, both primary and metastatic, regardless of the histological type of the tumor or previous treatments. It has also shown its effectiveness in the case of treating deep-seated tumors. On the other hand, ECT offers considerable advantages, like in terms of time of hospitalization; it can be performed at a day hospital. It is also possible to repeat several ECT cycles without precluding other types of treatment. It has good cost/benefit ratio and no serious adverse events or severe toxicity have been related to this technique.

However, because of novelty of this method, more research and investigation are needed to develop ECT and make it more applicable for different types of cancers, as well as other diseases in various areas in the body.

7. Reference

1. Miklavcic D, Davalos RV. Electrochemotherapy (ECT) and irreversible electroporation (IRE)-advanced techniques for treating deep-seated tumors based on electroporation. *Biomedical engineering online*. 2015 Aug 27;14(3):1.
2. Sersa G, Miklavcic D, Cemazar M, Rudolf Z, Pucihar G, Snoj M. Electrochemotherapy in treatment of tumours. *European Journal of Surgical Oncology (EJSO)*. 2008 Feb 29;34(2):232-40.
3. Kranjc S, Kranjc M, Scancar J, Jelenc J, Sersa G, Miklavcic D. Electrochemotherapy by pulsed electromagnetic field treatment (PEMF) in mouse melanoma B16F10 in vivo. *Radiology and oncology*. 2016 Mar 1;50(1):39-48.
4. Miklavčič D, Serša G, Breclj E, Gehl J, Soden D, Bianchi G, Ruggieri P, Rossi CR, Campana LG, Jarm T. Electrochemotherapy: technological advancements for efficient electroporation-based treatment of internal tumors. *Medical & biological engineering & computing*. 2012 Dec 1;50(12):1213-25.
5. Cadossi R, Ronchetti M, Cadossi M. Locally enhanced chemotherapy by electroporation: clinical experiences and

perspective of use of electrochemotherapy. *Future Oncology*. 2014 Apr;10(5):877-90.

6. Groselj A, Kos B, Cemazar M, Urbancic J, Kragelj G, Bosnjak M, Veberic B, Strojan P, Miklavcic D, Sersa G. Coupling treatment planning with navigation system: a new technological approach in treatment of head and neck tumors by electrochemotherapy. *Biomedical engineering online*. 2015 Aug 27;14(3):1.
7. Mali B, Gorjup V, Edhemovic I, Breclj E, Cemazar M, Sersa G, Strazisar B, Miklavcic D, Jarm T. Electrochemotherapy of colorectal liver metastases-an observational study of its effects on the electrocardiogram. *Biomedical engineering online*. 2015 Aug 27;14(3):1.
8. Corovic S, Bester J, Miklavcic D. An e-learning application on electrochemotherapy. *Biomedical engineering online*. 2009 Oct 20;8(1):1.
9. Benevento R, Santoriello A, Perna G, Canonico S. Electrochemotherapy of cutaneous metastasis from breast cancer in elderly patients: a preliminary report. *BMC surgery*. 2012 Nov 15;12(1):1.
10. Edhemovic I, Gadzije EM, Breclj E, Miklavcic D, Kos B, Zupanic A, Mali B, Jarm T, Pavliha D, Marcan M, Gasljevic G. Electrochemotherapy: a new technological approach in treatment of metastases in the liver. *Technology in cancer research & treatment*. 2011 Oct 1;10(5):475-85.
11. Sersa G, Cufer T, Paulin SM, Cemazar M, Snoj M. Electrochemotherapy of chest wall breast cancer recurrence. *Cancer treatment reviews*. 2012 Aug 31;38(5):379-86.
12. Cabula C, Campana LG, Grilz G, Galuppo S, Bussone R, De Meo L, Bonadies A, Curatolo P, De Laurentiis M, Renne M, Valpione S. Electrochemotherapy in the treatment of cutaneous metastases from breast cancer: A multicenter cohort analysis. *Annals of surgical oncology*. 2015 Dec 1;22(3):442-50.
13. Miklavcic D, Snoj M, Zupanic A, Kos B, Cemazar M, Kropivnik M, Bracko M, Pecnik T, Gadzije E, Sersa G. Towards treatment planning and treatment of deep-seated solid tumors by electrochemotherapy. *BioMedical Engineering OnLine*. 2010 Feb 23;9(1):1.
14. Domanico R, Trapasso S, Santoro M, Pingitore D, Allegra E. Electrochemotherapy in combination with chemoradiotherapy in the treatment of oral carcinomas in advanced stages of disease: efficacy, safety, and clinical outcomes in a small number of selected cases. *Drug Design, Development and Therapy*. 2015;9:1185.
15. Castiello M, Dughiero F, Scandola F, Sieni E, Campana LG, Rossi CR, De Mattei M, Pellati A, Ongaro A. A new grid electrode for electrochemotherapy treatment of large skin tumors. *IEEE Transactions on Dielectrics and Electrical Insulation*. 2014 Jun;21(3):1424-32.
16. Sersa G, Teissie J, Cemazar M, Signori E, Kamensek U, Marshall G, Miklavcic D. Electrochemotherapy of tumors as in situ vaccination boosted by immunogene electrotransfer. *Cancer Immunology, Immunotherapy*. 2015 Oct 1;64(10):1315-27.
17. Corovic S, Zupanic A, Miklavcic D. Numerical modeling and optimization of electric field distribution in subcutaneous tumor treated with electrochemotherapy using needle electrodes. *IEEE Transactions on Plasma Science*. 2008 Aug;36(4):1665-72.
18. Miklavčič D, Mali B, Kos B, Heller R, Serša G. Electrochemotherapy: from the drawing board into medical practice. *Biomedical engineering online*. 2014 Mar 12;13(1):1.
19. Mir LM, Gehl J, Sersa G, Collins CG, Garbay JR, Billard V, Geertsen PF, Rudolf Z, O'Sullivan GC, Marty M. Standard operating procedures of the electrochemotherapy: instructions for the use of bleomycin or cisplatin administered either systemically or locally and electric pulses delivered by the Cliniporator TM by means of invasive or non-invasive electrodes. *European Journal of Cancer Supplements*. 2006 Nov 30;4(11):14-25.
20. Schmidt G, Juhasz-Böss I, Solomayer EF, Herr D. Electrochemotherapy in Breast Cancer: A Review of References. *Geburtshilfe und Frauenheilkunde*. 2014 Jun;74(06):557-62.
21. Brace CL. Radiofrequency and microwave ablation of the liver, lung, kidney, and bone: what are the differences?. *Current problems in diagnostic radiology*. 2009 Jun 30;38(3):135-43.
22. Poulou LS, Botsa E, Thanou I, Ziakas PD, Thanos L. Percutaneous microwave ablation vs radiofrequency ablation in the treatment of hepatocellular carcinoma. *World J Hepatol*. 2015 May 18;7(8):1054-63.



Interventional Photodynamic Therapy (PDT) Applications, current problems and future developments (Review)

Philipp Steinert, Faculty of Electrical and Information Technologies, Institute for Medical Engineering, Otto-von-Guericke-University, 39106 Magdeburg, Germany

Introduction

- PDT is well-known medical treatment modality, which allows high selectivity and accuracy
- Equipment, especially the light sources and the light delivery access, must be adapted to each specific application
- Current research fields: new approaches to deliver photosensitizer (PS) to the targeted cells, new ways to activate the PS and improved methods to guide PDT, which make PDT treatment an attractive future choice

PDT – BASIC PRINCIPLE

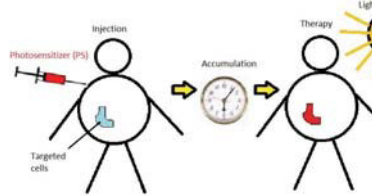


Fig. 1: Basic principle of PDT: 1. Injection of PS; 2. Accumulation in targeted cells; 3. Irradiation/Therapy

- Based on photodynamic reactions of a photosensitizer (PS), activated by a light source, a chemical reaction occurs, which can induce severe damage to tissue
- Activation of the PS: electromagnetic radiation, normally within the visible light spectrum
- Three different reactions are possible: Type I redox reaction creates reactive species like free radicals, type II redox reaction generates highly reactive singlet oxygen and the third possibility is phosphorescence or fluorescence

Components & Medical applications

Photodynamic Therapy (PDT) is a treatment option which requires three main components: A photosensitizer (PS) which accumulates in the targeted cells, a light source to activate the photosensitizer (PS) and oxygen. The combination of these three components can lead to a toxic chemical reaction in the targeted tissue. In theory PDT offers the possibility to treat malignant and premalignant diseases in a less invasive method compared to conventional methods like open surgery.

Photosensitizer (PS)

Table 1: Selection of clinically Applied Photosensitizers (PS)

PS	A: Approved T: Trials	Ideal Characteristics					Accumulation / elimination
		High singlet oxygen	Efficient light absorption (nm)	Non-toxic	Low dark toxicity	Tissue selectivity	
Photofrin (HPD)	A: Worldwide	+	630	++	--	-	--
ALA	A: Worldwide	0	635	++	+	0	-
ALA esters	A: Europe	+	635	+	+	+	0
Foscan (mTHPC)	A: Europe T: United States	++	652	-	--	-	0
HPPH	T: United States	++	665	+	0	+	+
Talaporfin (LS11, MACE, NPe6)	T: United States	+	660	+	0	--	+
Silicon phthalocyanine (Pc4)	T: United States	0	675	+	0	+	+
Tadoporfin (TOOKAD)	T: United States	+	762		++		++

Light source

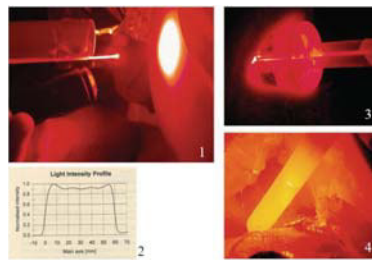


Fig. 2: Examples of light applicator systems [1]: 1. Glass fiber; 2. Light intensity profile of glass fiber with attached micro lens; 3. & 4. Diffuse light applicators

- Three main classes of clinical PDT light sources: lasers, LEDs and filtered lamps
- Light source defines area to irradiate and penetration depth

Oxygen

- Available oxygen in tissue determines effectiveness of PDT treatment
- lifetime of singlet oxygen is ca. 10 – 320 ns; limits diffusion to approximately 10 – 55 nm in cells → damage close to the location of the PS; enables accurate treatment
- Cell damage mainly in three different ways: Apoptosis, necrosis or autophagy-associated cell death

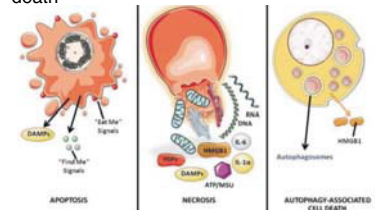


Fig. 3: Cell death can occur in three different ways: Apoptosis, necrosis or autophagy-associated cell death

Medical applications

PDT is often used as a complimentary approach to open surgery, chemotherapy and radiation therapy. PDT is established in a wide field of different medical applications, including gastroenterology, dermatology, gynecology, ophthalmology, ENT, etc. It can be distinguished between a superficial, an intraoperative, an interstitial and an endoscopically access. An example for superficial access can be found in Dermatology, for intraoperative in thoracic Oncology, interstitial in Neurosurgery and endoscopic in lung cancer treatment.

Drawbacks & Future outlook

There are also disadvantages of PDT, like the dependence on penetration depth of visible light into tissue, distribution and monitoring issues of the PS, and difficulties with the intraoperative access that make further improvements necessary. Since the penetration depth of visible light is limited in tissue, PDT is often used as a complementary treatment in combination with other medical treatments

Drawbacks

- Major disadvantage is the dependence of penetration depth of visible light into tissue – activation of PS only in superficial tissue layers
- Entire monitoring process of a PDT treatment is still largely unresolved – accurate dose measurement and monitoring often not possible
- Photosensitivity of the skin with accumulated PS – also sunlight can activate PS; precautions have to be met

Future outlook

- Overcome depth dependency: Light source: ultrafast pulsed laser light for deeper penetration; X-ray radiation to stimulate singlet oxygen generation; Radionuclides to emit photon directly in tissue to activate PS
- PS: Nanoparticles for better delivery and accumulation; PS can be integrated with drug delivery → not only to damage tissue also to deposit medication
- Approaches to integrate PDT treatment into other medical treatments like radiation therapy

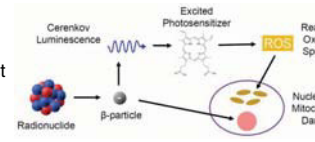


Fig. 4: Cerenkov radiation activated PDT <http://bmc.uclavis.edu/marculab/files/2014/08/crenkov.jpg>

Conclusion

PDT is used for many years, still it has not found a big breakthrough in one specific medical field. It is widely used in all kind of medical fields and its importance can be measured at the high amount of ongoing research. It is also not a standalone treatment, but it complements different medical treatments and is important for palliative treatments. At the same time the high flexibility of the PDT treatment opens up possibilities for further developments. PDT will also complement the multimodal and patient specific treatment approaches of the near future in medicine.

References

- [1] M. H. Abdel-Kader, Photodynamic Therapy - From Theory to Application, Springer Heidelberg New York Dordrecht London: Springer-Verlag, 2014.
- [2] A. Ehrhardt, *Inkohärente Lichtsysteme für die Fluoreszenzdiagnostik und die Photodynamische Therapie*, München, 2005.
- [3] M. H. Gold, Photodynamic Therapy in Dermatology, New York Dordrecht Heidelberg London: Springer, 2011.
- [4] P. Mroz und M. R. Hamblin, „PDT in Dermatology,“ in *Advances in Photodynamic Therapy: Basic, Translational, and Clinical*, Artech House, 2008, pp. 419 - 439.
- [5] B. C. Wilson und M. S. Patterson, „The physics, biophysics and technology of photodynamic therapy,“ *PHYSICS IN MEDICINE AND BIOLOGY*, Bd. Phys. Med. Biol. 53, p. R61–R109, 2008.

Interventional Photodynamic Therapy (PDT) – Applications, current problems and future developments

Philipp Steinert¹ January 2017

¹Faculty of Electrical and Information Technologies, Institute for Medical Engineering, Otto-von-Guericke-University, 39106 Magdeburg, Germany

Abstract Photodynamic therapy (PDT) is a well-known medical treatment modality. Based on photodynamic reactions of a photosensitizer (PS), activated by a light source, a chemical reaction occurs, which can induce severe damage to tissue. Although this method is known in modern medicine for more than 100 years, there is still intensive research ongoing. PDT is used in many different medical fields, because this treatment method allows high selectivity and accuracy. Therefore the equipment, especially the light sources and the light delivery access must be adapted to the specific application. Before the invention of glass fibers the PDT treatment was limited to superficial applications. With fiber optics, the improvement and new development of light sources and new PS, it became now possible to apply this treatment also intracorporeal. But there are also disadvantages of PDT, like the dependence on penetration depth of visible light into tissue, distribution and monitoring issues of the PS, and difficulties with the intraoperative access that make further improvements necessary. Since the penetration depth of visible light is limited in tissue, PDT is often used as a complementary treatment in combination with other medical treatments. Current research fields include new approaches to deliver the PS to the targeted cells, new ways to activate the PS and improved methods to guide PDT, which make PDT treatment an attractive future choice.

Index Terms—PDT, Photodynamic Therapy; PS, Photosensitizer

I. INTRODUCTION

Photodynamic Therapy (PDT) uses light to activate a photosensitizer (PS) which is accumulated in cells of special interest. Light energy is absorbed and can lead to the generation of highly reactive oxygen or radicals. If the right conditions are available a chemical reaction to destroy targeted cells can be evoked. The first clinical approaches with this therapeutic treatment modality in modern medicine can be traced back to the beginning of the twentieth century. This review paper gives a brief overview on the applications today and the existing drawbacks. It will also focus, based on literature review, on ongoing developments and future outlooks of PDT. A special focus is put on the systems and instruments that are employed for the procedures. Today PDT is widely used in medical applications, but there are also applications in the treatment of noxious insects and parasite control. The basic principle is the same, but since the requirements are different, this paper focuses exclusively on the medical applications. [1] [2]

II. PDT – BASIC PRINCIPLE

Photodynamic Therapy (PDT) is a treatment option which requires three main components: A photosensitizer (PS) which accumulates in the targeted cells, a light source to activate the photosensitizer (PS) and oxygen. The combination of these three components can lead to a toxic chemical reaction in the targeted tissue. In theory PDT offers the possibility to treat malignant and premalignant diseases in a less invasive method compared to conventional methods

like open surgery.

First the PS has to be administered to the patient. This can be done in a systemic or in a topical approach. Systemic means that the PS is injected intravenous or is administered oral in the form of a drug into the patient, while topical means it is applied only at the region of interest. In both cases the PS has to accumulate in specific cells. These specific cells are often tumor cells. Some PS accumulate in different cell organelles, others in membranes or the vascular system.

As described in Fig. 1, after the accumulation, the main therapy, the irradiation with a light source, takes place. The PS ideally is nontoxic to the human body, but it changes its chemical structure by irradiation with light. This chemical activation and the following chemical reactions lead to highly reactive singlet oxygen, which in most cases causes cell death. The main parameters to control the therapy are the amount of available PS, the time between PS application and treatment, molecular oxygen and the irradiation dose.

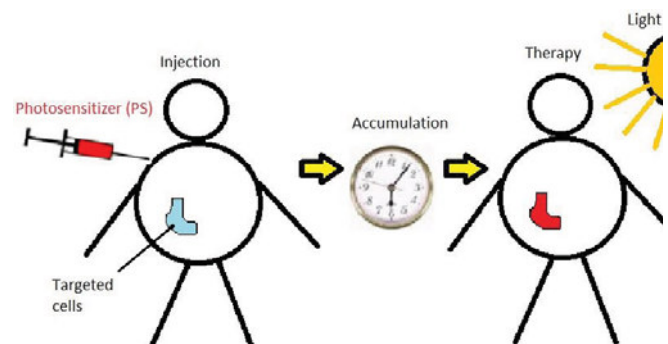


Fig. 1: Basic principle of PDT: 1. Injection of PS; 2. Accumulation in targeted cells; 3. Irradiation/Therapy

A. Photosensitizer (PS)

The activation of the PS is achieved by electromagnetic radiation, normally within the visible light spectrum. Each PS has a specific absorption spectrum. If the PS is irradiated at this specific absorption spectrum or at least at a peak of the absorption spectrum, the PS can absorb energy and therefore change its energy level. The energy level is changed by electronic excitation. This can lead in a second step to a chemical reaction. The chemical reaction can vary for different PS. Basically three different reactions are possible: A type I redox reaction creates reactive species like free radicals, a type II redox reaction generates highly reactive singlet oxygen and the third possibility is phosphorescence or fluorescence. Depending on the available oxygen and induced energy the result of this chemical reaction is a highly reactive radical, in most cases singlet oxygen, often combined with fluorescence of the molecule. This highly reactive radical interacts with the surrounded tissue, which can lead to necrosis or apoptosis of the cells. The fluorescence can be used to

monitor and guide the procedure, but has no toxic effect.

The ideal photosensitizer (PS) has to fulfill certain characteristics. First of all a high singlet oxygen quantum yield is to achieve to make the treatment as efficient as possible, since the singlet oxygen is the main cause for destroying the targeted cells.

Also a high quantum yield of natural fluorescence would be beneficial to achieve a visual control of the tissue with accumulated PS. A high uptake of the PS in the targeted cells with high contrast to the neighboring healthy tissue is therefore preferred. With the PS only present in the targeted cells, a visual control by fluorescence of the targeted cells would be possible, and with that the irradiation of the treatment could be simplified and monitored.

An efficient light absorption at longer wavelength is advantageous, since the spectral range of light with a wavelength in between 700 to 800 nm has the deepest penetration into tissue. The PS should also be nontoxic with a low dark toxicity, so that it is not harmful to patients who are exposed to light.

Table 1: Clinically Applied Photosensitizers [1] [7] [8] [22] [23] (fulfills characteristics: ++,+0,-,- :does not fulfill characteristics)

Photosensitizer	Structure	A: Approved T: Trials	Ideal Characteristics						
			high singlet oxygen quantum yield	high quantum yield of natural fluorescence	efficient light absorption at longer wavelength (nm)	nontoxic	low dark toxicity	selective uptake in targeted cells	short time period of accumulation and elimination
Porfimer sodium (Photofrin) (HPD)	Phorphyrin	A: Worldwide	+		630	++	--	-	--
ALA	Phorphyrin precursor	A: Worldwide	0	+	635	++	+	0	-
ALA esters	Phorphyrin precursor	A: Europe	+	++	635	+	+	+	0
Tempoporfin (Foscan) (mTHPC)	Chlorine	A: Europe T: United States	++		652	-	--	-	0
Verteporfin	Chlorine	A: Worldwide (AMD) T: United Kingdom	+		690		+	-	++
HPPH	Chlorine	T: United States	++		665	+	0	+	+
SnEt2 (Purlytin)	Chlorine	T: United States	0		660		0	+	+
Talaporfin (LS11, MACE, NPe6)	Chlorine	T: United States	+	+	660	+	0	--	+
Ce6-PVP (Fotolon), Ce6 derivatives (Radachlorin, Photodithazine)	Chlorine	T: Belarus, Russia	+		660	+			+
Silicon phthalocyanine (Pc4)	Phthalocyanine	T: United States	0	+	675	+	0	+	+
Padoporfin (TOOKAD)	Bacteriochlorin	T: United States	+		762		++		++
Motexafin lutetium (Lutex)	Texaphyrin	T: United States	++		732		+	0	++

Abbreviations from [8]: ALA, 5-aminolevulinic acid; AMD, age-related macular degeneration; Ce6-PVP, chlorin e6-polyvinylpyrrolidone; HPD, hematoporphyrin derivative; HPPH, 2-(1-hexyloxyethyl)-2-devinyl pyropheophorbide-a; MACE, mono-(L)-aspartylchlorin-e6; mTHPC, m-tetrahydroxyphenylchlorin; nm indicates nanometers; SnEt2, tin ethyl etiopurpurin.

This means if the patient is exposed to sunlight and the PS is still present in e.g. cells of the skin the reactions of PDT will occur as long as the PS is available. Therefore also a fast metabolism to eliminate the PS from the body after treatment is to achieve.

The PS can be categorized into three broad families according to their chemical structure: porphyrin, chlorines and dyes. The PS can be further categorized into three generations. The first generation, which includes the porphyrin hp are present in cells and can be produced by the body itself. The second generation includes the chlorines and some dyes. The third generation includes antibodies that bind selectively to an antigen on the targeted cells. This generation of PS is still in development.

The most important and widely used porphyrin is hematoporphyrin (hp). First studies with hp were executed in 1980. One important and widely used derivatives of hp is photofrin. Medical studies from the 1980s until today support the positive impact of photofrin as a PS for PDT applications.

An important endogenous PS is 5-Aminolevulinic acid (5-ALA). Endogenous means that it can be found in the body. 5-ALA is enzymatically converted to the active PS protoporphyrin IX (PPIX). Normally the 5-ALA production in the body is controlled via a feedback system, but if this PS is administered exogenous, which means from outside, this feedback control can be bypassed and an accumulation of PPIX is possible. For example 5-ALA can be used in the treatment of malignant glioblastoma or in bladder cancer treatment.

Chlorines are chlorophyll-like substances and can be found in bacteria and algae. Examples are bacteriochlorin, chlorin e6 (Ce6) and chlorophyll derivatives (CpD). Tempoporfin (mTHPC) is a second generation PS based on chlorin and is used in PDT to treat squamous cell carcinoma of the head and neck. In the European Union, it is also known under the name Foscan.

The most common dyes are phthalocyanines. They belong to the second generation PS and have a high absorption rate when irradiated with light of 650 – 800 nm, also a short tissue accumulation can be observed.

This only gives a brief overview of possible PS, for further information the author refers to [1]. Many different PS are available and for each application the ideal PS has to be chosen. Table 1 gives an overview of clinically applied PS and some of their characteristics. It also evaluates the PS regarding the ideal characteristics. Although the table is not complete it shows that PS with completely different characteristics are available. [1] - [3] [8] [23]

B. Light source

The second important component of a PDT treatment is the light source. It is important to choose the light source application-specific, since the light source defines the efficient activation of the PS. The penetration depth of the light and the available molecular oxygen is directly related to the induced dose of toxicity.

The three main classes of clinical PDT light sources are lasers, LEDs and filtered lamps. LEDs and filtered lamps can be used to irradiate wide areas, while lasers are used if deeper penetration is necessary. Additionally longer wavelengths are preferred, since it causes deeper light penetration into tissue. As already mentioned the emitted wavelength of the light source has to match the absorption spectrum of the PS. Therefore often a tradeoff between penetration depth (longer wavelength) and maximum absorption rate of the PS has to be found.

Dependent on the application the light access route is also different. While in Dermatology light can be emitted directly on top of the skin, in intracorporeal applications the light or light source has to be brought to the application area. It can be distinguished between a superficial, an intraoperative, an interstitial and an endoscopically access.

Different light applicator systems can be seen in Fig. 2. Depending on the application a certain area must be illuminated homogenously. Glass fibers enable to transmit light, especially laser light, into the body. To get a uniform illumination often a micro lens is used at the distal tip of the fiber. For longer hollow organs or for interstitial applications diffuse light applicators are used (see Fig. 2).

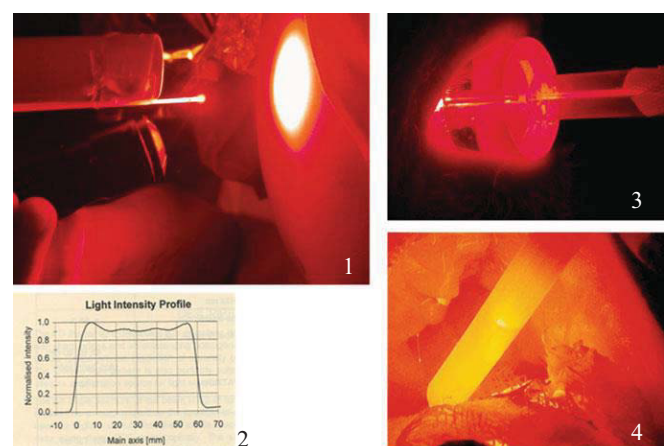


Fig. 2: Examples of light applicator systems [1]: 1. Glass fiber; 2. Light intensity profile of glass fiber with attached micro lens; 3. & 4. Diffuse light applicators

Lasers couple light into a glass fiber and are able to irradiate small spots with a comparably higher penetration depth. The use of LEDs are another and cheaper option. In intracorporeal applications the heat emission of LEDs can be a problem to healthy tissue

however. They can also be coupled into light fiber systems, which then make LEDs comparable to laser light sources. LEDs cover all visible light wavelengths and can be arranged in many different configurations. This makes LEDs also an important light source for wide area irradiation. Filtered lamps have a low efficiency compared to other light sources, but are still used due to historical and cost reasons. In certain applications it makes sense to use a filtered light source, for example in endoscopic applications it enables to use one light source for illumination during inspection of an area with reduced intensity and use the same light source with a filter and higher intensity to irradiate the area of interest. Also if a filter is used, the filter can be adjusted to match to many different PS, while a laser or LEDs often only emit one wavelength and therefore match only with a low number of PS. [1] - [3] [8]

C. Oxygen

The available oxygen in the tissue is one of the determining factors of the effectiveness of a PDT application. Only if enough oxygen is present the toxic chemical reaction can take place. The PS is activated by the light source to produce reactive oxygen species (ROS).

Two different types of reactions lead to the generation of these highly reactive ROS. Type I redox reactions involve an electron or hydrogen transfer, induced in the PS, to form free radicals. Type II redox reactions produce the highly reactive state of oxygen, called singlet oxygen. In PDT mainly type II redox reactions take place.

The lifetime of singlet oxygen is between 10 – 320 ns, which limits the diffusion to approximately 10 – 55 nm in cells. Therefore the photodynamic damage takes place close to the location of the PS. This enables an accurate treatment of cells with accumulated PS.

The cell damage mainly occurs in three different ways. Fig. 3 summarizes the different mechanisms. Apoptosis can take place. It is a programmed cell death due to damage of singlet oxygen inside the cell.

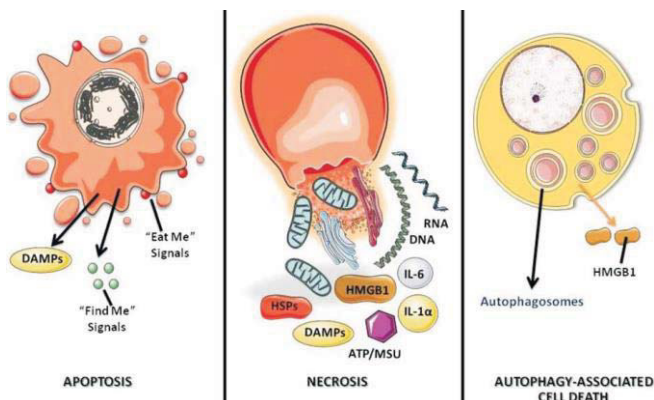


Fig. 3: Cell death can occur in three different ways: Apoptosis, necrosis or autophagy-associated cell death [8]

During that process cell fragments, so called apoptotic bodies are produced, which can be removed by phagocytic cells. If the damage is too severe necrosis takes place. Necrosis is a traumatic cell death. The cell content spills into the interstitium, which can lead to further damage. A third method can be autophagy-associated cell death. In this case damaged cell organelles are basically isolated in a double-membraned vesicle, called autophagosomes. These autophagosomes are then processed in a second step. [1] - [3] [8]

III. PDT – FIELDS OF APPLICATION

PDT is often used as a complimentary approach to open surgery, chemotherapy and radiation therapy. PDT is established in a wide field of different medical applications, including gastroenterology, dermatology, gynecology, ophthalmology, ENT, etc.

In this chapter different applications are described. They were chosen to give an overview of the different possible applications and the required instruments. Almost all existing medical PDT applications follow one of the described methods. The focus therefore is on highlighting the differences in these medical applications.

A. Dermatology

PDT is well established in Dermatology. Many different treatments are available, since the skin can be irradiated and the PS can be applied very easily from the outside on the skin. Fig. 4 shows one possible application of PDT in Dermatology. PDT is used here to irradiate a lesion which sits in the middle of the white tissue on the patients arm. The light source can be placed above the lesion.

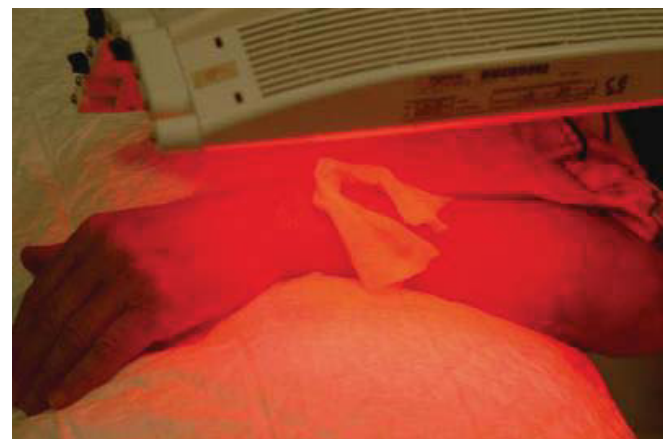

Fig. 4: Application of PDT in Dermatology [4]

One example is the treatment of actinic keratoses (AK). AK is a premalignant skin condition. The risk of untreated AK is the possible transformation to cutaneous squamous cell carcinoma (SCC).

Fig. 5 shows the clinical presentation of AK. Two main risk factors for AK are fair skin and history of

extensive, cumulative sun exposure. To prevent disease progression to SCC, which has metastatic potential an early treatment is necessary. Depending on the case, PDT is used as an additional treatment to surgical treatment, such as cryotherapy or excision. For the PDT treatment 5-ALA is most often used as the topical PS. The incubation time is anywhere between 3 – 4 hours and depends on the specific treatment. Depending on the application different light sources are used.

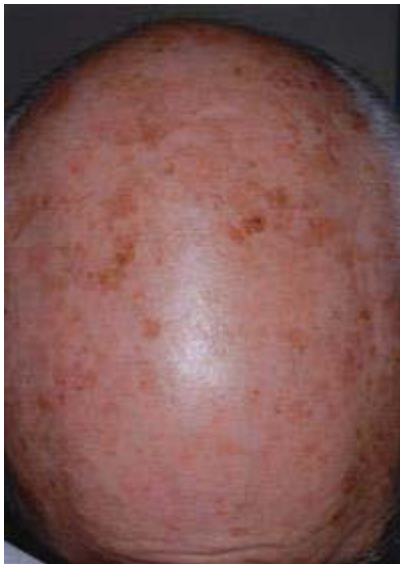

Fig. 5: Actinic keratosis (AK) on the frontal scalp of a male patient [4]

For example if many lesions are present, it may make sense to treat a wider area at once. Therefore a light source with a uniform illumination on the whole area of treatment is necessary. Fig. 6 shows an example of a light source which can be used to irradiate the whole skull at once.



Fig. 6: Example of light source to treat actinic keratosis (AK) [4]

If only a small area or individual lesions are present, a light source with a smaller spot can be used. For smaller spot laser light sources are preferred. To ensure a positive outcome the irradiation dose per area should be equivalent in each application. The light source should emit light with a wavelength of around 635 nm, since 5-ALA is activated at this wavelength and the penetration depth into tissue is considerably better compared to light with a shorter wavelength. However, in the United States blue light (wavelength: ca. 380 – 450 nm) is the only FDA-approved form of light for activating 5-ALA. The photochemical effect - the activation of 5-ALA - is effective, but blue light only penetrates 1 – 2 mm into tissue limiting treatment to that distance from the skin surface.

Other dermatology PDT treatments are possible, for example acne vulgaris, sebaceous gland hyperplasia (SGH) and hidradenitis suppurativa. [1] - [7]

B. Thoracic Oncology

PDT treatments in thoracic oncology are chosen as an example for the intracorporeal treatment method. In this field PDT is part of a multidisciplinary cancer treatment approach and compliments surgery, chemotherapy and radiation therapy. However, in some cases, like palliative therapy, PDT is the only available treatment option. The most common cancers in thoracic oncology are: lung cancer, oesophageal cancer, mesothelioma and breast cancer.

Photosensitivity of the patient can be an issue, since PS is mostly applied systemically or higher volumes have to be administered. PS can be accumulated in the skin of the patient, which leads to photochemical reactions when exposed to light. Even sunlight can activate the PS. Therefore precautions have to be taken, so that no unwanted photo-chemical reactions and damage to healthy tissue is provoked.

Irradiation delivery becomes a special technical problem in thoracic applications. For a successful PDT treatment a uniform irradiation of intracorporeal targeted tissue is necessary. Basically two types of irradiation can be distinguished: Diffuse and focused irradiation. Diffuse irradiation is used for larger areas, while focused irradiation can be used for smaller areas and to achieve deeper penetration depth. Diffuse irradiation has the disadvantage, that also PS which is available in non-targeted tissue is activated and can damage healthy tissue. If a bulky lesion has to be treated, the light source, often a glass fiber, can be put directly into the to be treated structure. To avoid breakage of the fragile fiber, a small incision can be done, just large enough for the fiber. These fibers are mostly diffuse light sources able to irradiate the whole bulky structure from the inside. Different additional substances such as emulsion can be used, to distribute light in cavities. This is used, if it is not possible to

irradiate a specific area from a frontal position.

An advantage of PDT is that the treatment can be repeated multiple times. This opens up the possibility to treat a larger area in multiple steps and also to reach deeper seated tissue by applying multiple treatments. Since the irradiation has to be adapted individually on each case, PDT also offers opportunities for personalized treatment approaches.

One example for a treatment in thoracic oncology is lung cancer, also called bronchial carcinoma. The available standard treatments are surgery, radiotherapy and chemotherapy. One indication for a PDT treatment is for example a patient that is ineligible for surgical resection.

Another indication is, if a tumor blocks an airway and therefore a large part of the lung is not ventilated anymore, PDT can be used to reduce the size of the tumor enabling to open up the airway again.

PDT is also used after major lung resections to treat the tumor bed. This increases the safety margin, since remaining tumor cells in the tumor bed can be destroyed. In thoracic oncology PS is administered intravenous (IV). The most common PS is Photofrin. Basically two different approaches are available: An endoscopic approach and an open surgery approach. The endoscopic approach is described in more detail in the next chapter. The open approach makes sense, if e.g. an open resection was done prior to the PDT treatment. The only disadvantage is that the administration of the PS must be planned prior to surgery so that an irradiation is effective after the tissue resection. Depending on the resection area, most of the irradiations are superficial although intracorporeal and therefore in general similar to the described irradiations in dermatology. For an endoscopic approach for e.g. treatments in the bronchus system the procedure follows in general the described methods in the next chapter. [1] - [7]

C. Endoscopic Applications

Endoscopic PDT applications are chosen as an example for intracorporeal treatments. Since endoscopy follows a minimal invasive approach, special requirements for the instruments and treatment methods are necessary. Since the available light sources are well developed and also many different PS are available, it makes sense to find new ways to reach regions of interest inside the body in a minimally invasive way. Modern endoscopic equipment makes it possible to apply PDT intracorporeal, since it brings all requirements already within the system. It has a light source which is used to illuminate hollow organs. But this light source could also be used to irradiate a specific area. The camera or image bundle, which transmits the image from inside to outside, can be used to monitor the treatment. Often, a working channel is

available to insert instruments, or even laser fibers for optimal irradiation. But for minimal invasive intracorporeal PDT treatments there is still plenty of room for improvements of the used instruments like catheters, light fibers, PS deposition methods, etc. The main challenges are to provide enough light dose and to ensure a uniform irradiation of the targeted tissue.

Endoscopic PDT applications can be found in different medical fields. As indicated in the previous chapter treatments in the bronchus can be done endoscopically. The major advantage is that the treatment area can be reached through natural body orifices or very small incisions. Another example is the treatment of bladder cancer in urology with PDT. Here also a natural body orifice can be used. The instruments can be introduced through the urethra. This limits the diameter however and defines the requirements for the shape of the used instruments.

For treatments in the bladder the PS can be administered intravenous (IV) or in a solution which is directly introduced into the bladder. After accumulation of the PS in the targeted cells the irradiation takes place. Fig. 7 shows a balloon catheter for irradiation of the bladder.




Fig. 7: Balloon catheter for light application [5]

In this case a catheter is used to irradiate the whole bladder at the same time. The balloon is used to position and to fix the catheter and white light to irradiate. The main reason for the white light is that the light source of the endoscopic system is used and with that no second light source is required. As long as the spectrum of the light source contains light with the required wavelength and enough intensity to activate the PS any light source can be used. To ensure a uniform irradiation, particles to diffuse the light in all directions are implemented into the distal tip of the catheter. [1] - [7]

D. Neurosurgery

The PS in neurosurgical applications has additional requirements. It should have a very high selectivity for tumor cells, also for tumor cells embedded in normal brain tissue. This is to ensure, that all tumor cells can be destroyed without damaging the surrounding tissue. If the PS is applied systemically, it should also be able to cross the blood brain barrier (BBB) since it has to reach the tumor cells in the brain. Also high fluorescence properties are preferred to have a visual control with the endoscopy system for irradiating the tumor cells. In these applications also a uniform and efficient irradiation is important.

The main procedure is similar to the already described procedures under C. Not a lot of space is available however, because one main goal is to save as much healthy tissue as possible. Light fibers are therefore most often used to irradiate the targeted tissue. [1] [4] [13]

E. Management of bacterial infections

A non-surgical application of PDT is the treatment of bacterial infections. Since drug-resistant bacteria get more and more a challenge in clinical routines, new approaches have to be found to manage bacterial infections. PDT is one of these approaches. This application is not part of interventional PDT and is therefore only mentioned to give a complete overview of medical PDT applications. [1] [4]

F. Conclusion

The above described PDT applications already show that the requirements for the technical equipment change for each application, although the basic principle is the same. To achieve the best outcome for the patient all these different medical and technical aspects have to be considered. In all treatments also treatment efficiency, after-care, treatment risks, affordability and insurance coverage have to be considered and compared with other treatment options. One of the main advantages is that PDT can be applied multiple times, which makes it also an excellent option for palliative treatments.

Approval for the specific treatments - including PDT - is national law and with that treatment protocols can differ in each country.

IV. PDT - DRAWBACKS

Although PDT is used in many different medical fields, there is still not the perfect combination of light source and PS. PDT is also used for many years, but there is no real breakthrough in one medical area. This could be because medical PDT is often only supplementary to other medical applications. Also some intrinsic drawbacks prevent the usage of current PDT methods for a large number of treatments.

The major disadvantage is the dependence of penetration depth of visible light into tissue. This creates problems in the delivery of light energy into deeper tissue. At this point already complementary approaches, like a tool which cuts and irradiates with a laser to get to deeper tumors could be developed. This would reduce the dependence on penetration depth, but it is not a plain PDT treatment anymore.

Even if light fibers are penetrated into tissue in several places and an irradiation would be possible the dose calculation and measurement is a problem due to individual tissue interaction, diffusion, and the lack of PS dosis monitoring.

More or less the entire monitoring process of a PDT treatment is still largely unresolved. If the application and the delivery of the PS to the targeted cells could be monitored, then the right moment to irradiate could be calculated. This would ensure an optimal result of the treatment and would make it better comparable to other treatments.

Another drawback is the photosensitivity of the skin with accumulated PS. If the PS is not eliminated in a short time period it can provoke tissue damage caused by sunlight. The patient will be photosensitive after treatment until the PS is processed or metabolized. If exposed to light symptoms of sunburn can occur. In an ideal case the PS should reach only the targeted cells in a short time period and be also eliminated from the body in a short time period.

Also the current PS have several drawbacks. Some are not water-soluble which makes the administration often difficult. Most of the PS have also a significant uptake in healthy tissue. During irradiation this leads to damage of healthy tissue. And the reason for the depth dependency can be found also within the PS drawbacks. Since the wavelength for activation of the PS is in the visible light range the penetration depth is low, due to the low penetration of visible light into tissue.

Drawbacks of the light sources can be found in the often low flexibility of the light source. That means for different applications it can be possible that different light sources are required. Often also the size of the light source is a problem and to achieve an accurate, sufficient and uniform illumination because of the treatment setup. [1] - [7] [13] [17]

V. PDT – FUTURE OUTLOOK

The focus of the future outlook is on ongoing research and on possible new developments in the PDT field. Most of the ideas were collected by reviewing the literature, but also ideas from the author are presented.

One major drawback is the depth dependency. A lot of research is going on to encounter this issue. Since

the light only penetrates a certain distance into the tissue either the light sources have to be improved or new ways to apply the PDT principle have to be found. One solution to improve the light source could be ultrafast pulsed laser light. This enables to reach deeper tissue, since the intensity of one pulse is very high, but the overall induce energy can be controlled by the pulse length. [7]

If the penetration depth is still not sufficient, also improvements of the devices to reach the tumor bed are possible. Endoscopy could be used to improve PDT intracorporeal. Fiberscopes could be used to reach deeper seated tumors. Rigid endoscopes could be used like a needle to penetrate into the targeted tissue. First to find the right spot the image bundle (glass fibers) are used to transmit an image from inside to the outside and during illumination they can also be used to transmit light from the outside to the inside additional to the light fibers which are also integrated in the fiberscope, to increase the light dose.

A further development of endoscopic applications could be catheter based applications. It may be possible to place a catheter under image guidance to the area of interest and then insert a light fiber through the catheter. This would require a better monitoring of dose measurement to ensure, that the irradiation is efficient. At the same time ways have to be found to evaluate the outcome, since the tumor bed would not be directly visible anymore under a catheter based treatment approach.

Another promising approach could be a combination of ionizing radiation therapy and PDT. If it would be possible to activate the PS with ionizing radiation, the depth dependency would vanish, since e.g. X-rays can penetrate tissue. The only disadvantage is that the patient is irradiated with ionizing radiation. But if this is already part of the multimodal treatment approach the used radiation therapy could maybe directly be used for activating the PS and would only be applied very locally. This would require the development of new PS which are activated at completely different wavelengths outside of the visible light range.

Another approach is to improve existing PS and also to find new approaches to deposit PS. Nanoparticles could be used to specifically deposit and activate PS. One described approach is to use single walled carbon nanotubes. These so called aptamers, which are DNA/RNA probes can bind to specific targeted tissue and control at the same time the singlet oxygen generation. This would improve the tissue contrast and allow better targeting of the specific tissue, but the depth dependency would still remain the same, since the PS in this case is activated by visible light with a low penetration depth into tissue. [10]

The conventional PS could also be replaced by

nanoparticles. These nanoparticles bear some advantages. For example the accumulation in the targeted cells can be controlled in some ways. Also nanoparticles can be designed to be less toxic than conventional PS. At the same time the degradation of the PS in the human body can be minimized, while the bioavailability and biocompatibility can be increased. [11]

One example of using nanoparticles as a PS are the so called fullerenes. These closed cage nanomaterials made from carbon atoms can be activated by light. They can also bind to other molecules which can improve the selectivity to certain tissues. These nanoparticles can bind to membranes, DNA, virus, bacteria or cancer cells. This would allow a very high selectivity for specific applications. These fullerenes used as a PS are still in the early stage of development. The basically photodynamic reaction is also slightly different to conventional PS. The main drawback is that the absorption spectrum and therefore the activation is the most efficient in the UV region of the light, but at this wavelength the penetration depth into tissue is very less. [12]

Another described method is to use X-ray radiation to stimulate the singlet oxygen generation during radiation with UV light. This research also showed that it is possible to use X-ray or γ -ray to activate nanoparticle-photosensitizer. If CeF_3 is used as a nanoparticle X-ray radiation can be used to stimulate the nanoparticle, therefore the nanoparticle emits UV light. This emitted UV light can then activate the PS. This approach has significantly better penetration depth, since the nanoparticle is linked to the PS and directly emits the light in the targeted cells. [14]

A similar approach is to use a radionuclide which emits a β -particle. This β -particle emits after annihilation a so called Cerenkov luminescence which activates a PS. Fig. 8 describes this method.

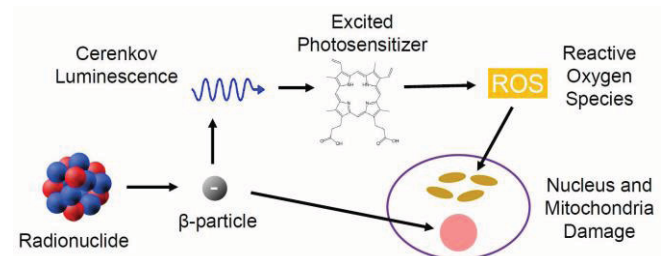


Fig. 8: Cerenkov radiation activated PDT
<http://bme.ucdavis.edu/marculab/files/2014/08/cerenkov.jpg>

Instead of X-ray or γ -ray a radionuclide is used to create visible light. As a PS a nanoparticle-photosensitizer is used, in this case transferrin-coated titanium dioxide (TiO_2). This would also enable to treat tumors in deeper seated tissue and at the same time open up new possibilities for new treatment approaches with different treatment modalities

combined. [15]

In the future also approaches might be possible, where PDT is used to deposit drugs in the targeted tissue. The nanoparticles could be used to carry drugs for e.g. cancer treatment and by activation of the PS the nanoparticles do not only support the reaction of reactive oxygen, but at the same time also release drugs in the targeted tissue which support the cancer treatment.

To improve PS delivery nanoparticles could be used. This could lead to a higher selective accumulation of the PS only in the targeted cells. Problems are that nanoparticles are often rapidly removed from the blood circulation. Therefore the delivery is not sufficient enough. New development with functionalized lipids in the construction of nanoparticles could address this issue [16].

To monitor the PDT treatment also different imaging modalities could be used. For example a MRI scanner is able to show the BOLD-contrast. BOLD stands for Blood-Oxygen-Level-Dependent, which allows to detect changes in the blood oxygen level. Since PDT consumes oxygen during the photochemical reactions also a change in the oxygen level of blood can be observed, if the treatment is close to or in a vascular system. Therefore in specific applications this imaging modality could be used to measure the consumption of molecular oxygen and monitor, based on this measurement, the effectiveness of the PDT treatment. [19]

In PDT treatments a guidance to ensure a satisfying result is missing most of the times. Optical spectroscopy could be a solution. [18]

In skin cancer treatment fluorescence guided PDT can also be used to improve the outcome. Fluorescence guidance until now was used as a visual feedback, but in some cases it makes sense to use image data of fluorescence imaging to actual guide the treatment. This can also improve the quality assurance, because it gives a visual feedback of the tissue with accumulated PS. [20]

Especially in brain tumor resection fluorescence image guidance potentially could improve the outcome. If a PS can be found with high fluorescence properties and a good tissue contrast then it can be used as a guidance tool to decide which tissue must be resected. In a second step a PDT treatment can be applied to irradiate the remaining tumor cells with accumulated PS. Here the resection and the PDT treatment would be integrated into one treatment, where the fluorescence of the PS is used as an image guided resection guidance. [21]

VI. CONCLUSION

PDT is used for many years. Because of its adaptable and flexible approach it still has not found a big breakthrough in one specific medical field. It is widely used in all kind of medical fields and its importance can be measured at the high amount of ongoing research. It is also not a standalone treatment, but it complements different medical treatments and is important for palliative treatments. At the same time the high flexibility of the PDT treatment opens up possibilities for further developments. The methods of PDT will definitely change in the future, but the ongoing research already describes possible developments. PDT will also complement the multimodal and patient specific treatment approaches of the near future in medicine. This makes PDT treatments preferable for a patient specific treatment approach. One possible patient specific approach could be to reproduce cells from e.g. a biopsy in the laboratory and to make preoperative tests to define which PS accumulates in the best way in the tumor cells to destroy only these specific cells.

Although many different PS are available and many different PS are still investigated and developed, it has to be mentioned for a product development, it is important to know which PS is licensed in which country.

In the medical field costs are often the main driving force for developments, in PDT treatments, besides the costs, it would also make sense to define some basic procedures and to research which application really makes sense for which treatment. There is still the question, how an ideal PDT system would look like. The problem is that the medical application defines the requirements for penetration depth of the light, access path and area to illuminate. This defines which light source should be used and at the same time how accurate the PS must accumulate in targeted cells in contrast to healthy tissue. There is not one ideal PDT system, but further development could lead to a systematic approach which defines a procedure how to choose the ideal combination for a specific application. Therefore more research to classify the PS due to their characteristics and effectiveness in combination with a few defined light sources is necessary. Until now the treatment options are very wide and undefined, therefore a clear classification is missing. The result of this research could be a plan to decide the best combination for each medical application.

One reason why there is no clear classification yet could be the still missing definition of a widely accepted dosimetry measurement system for PDT. To compare different approaches, first a method to measure the induced dose must be found and also clinical trials with a large number of cases are

necessary.

Besides the medical field PDT could also play a major role in treatment of infections. Since more and more resistant bacteria arise, maybe PDT could help to encounter this problem without increasing the resistant of the bacteria.

REFERENCES

- [1] M. H. Abdel-Kader, *Photodynamic Therapy - From Theory to Application*, Springer Heidelberg New York Dordrecht London: Springer-Verlag, 2014.
- [2] A. Ehrhardt, *Inkohärente Lichtsysteme für die Fluoreszenzdiagnostik und die Photodynamische Therapie*, München, 2005.
- [3] J R. BAUMGARTNER, Ph.D., M. Prof. KRIEGMAIR, M.D. und A. Prof. HOFSTETTER, M.D., M.D. h.c. mult., *FLUORESCENCE DIAGNOSIS OF BLADDER TUMOR Using 5-Aminolevulinic Acid – Fundamentals and Results –*, Tuttingen: Endo-Press, 2007.
- [4] M. H. Gold, *Photodynamic Therapy in Dermatology*, New York Dordrecht Heidelberg London: Springer, 2011.
- [5] R. WAIDELICH, W. BEYER, R. KNÜCHEL, H. STEPP, R. BAUMGARTNER, J. SCHRÖDER,, A. HOFSTETTER und M. KRIEGMAIR, „WHOLE BLADDER PHOTODYNAMIC THERAPY WITH 5-AMINOLEVULINIC ACID USING A WHITE LIGHT SOURCE,“ *UROLOGY, ELSEVIER SCIENCE INC.*, Bd. 61, Nr. 2, p. 332–337, 2003.
- [6] P. Mroz und M. R. Hamblin, „PDT in Dermatology,“ in *Advances in Photodynamic Therapy : Basic, Translational, and Clinical*, Artech House, 2008, pp. 419 - 439.
- [7] B. C. Wilson und M. S. Patterson, „The physics, biophysics and technology of photodynamic therapy,“ *PHYSICS IN MEDICINE AND BIOLOGY*, Bd. Phys. Med. Biol. 53, p. R61–R109, 2008.
- [8] P. P. Agostinis, K. P. Berg, K. A. M. P. Cengel, T. H. P. Foster, A. W. P. Girotti, S. O. P. Gollnick, S. M. M. P. Hahn, M. R. P. Hamblin, A. P. Juzeniene und J. M. P. Golab, „Photodynamic Therapy of Cancer: An Update,“ *CA: A Cancer Journal for Clinicians*, Bd. 61, Nr. 4, pp. 250-281, 2011.
- [9] J. L. Sandell und T. C. Zhu, „A review of in-vivo optical properties of human tissues and its impact on PDT,“ *J Biophotonics*, Bd. 4, Nr. 1, p. 773–787, 2011.
- [10] Z. Zhu, Z. Tang, J. A. Phillips, R. Yang, H. Wang and W. Tan, "Regulation of Singlet Oxygen Generation Using Single-Walled Carbon Nanotubes," *J. AM. CHEM. SOC.*, vol. 130, no. 33, p. 10856–10857, 2008.
- [11] E. Paszko, C. Ehrhardt, M. O. D. r. n. Senge, D. P. Kelleher and J. V. Reynoldse, "Nanodrug applications in photodynamic therapy," *Photodiagnosis and Photodynamic Therapy*, vol. 8, p. 14–29, 2011.
- [12] P. Mroz, . G. P. Tegos, H. Gali, T. Wharton, T. Sarnad and M. R. Hamblin, "Photodynamic therapy with fullerenes," *Photochemical & Photobiological Sciences*, vol. 6, p. 1139–1149, 2007.
- [13] B. J. Quirk, G. Brandal, S. Donlon, J. C. Vera, H. T. Whelan and et al., "Photodynamic therapy (PDT) for malignant brain tumors — Where do we stand?," *Photodiagnosis and Photodynamic Therapy*, vol. 12, p. 530—544, 2015.
- [14] S. Clement, W. Deng, E. Camilleri, B. C. Wilson und E. M. Goldys, „X-ray induced singlet oxygen generation by nanoparticle-photosensitizerconjugates for photodynamic therapy: determination of singlet oxygen quantum yield,“ *Scientific Reports*, pp. 1-9, 2016.
- [15] N. Kotagiri, G. P. Sudlow, W. J. Akers and S. Achilefu, "Breaking the Depth Dependency of Phototherapy with Cerenkov Radiation and Low Radiance Responsive Nanophotosensitizers," *Nature Naturenanotechnology*, vol. 10, no. 4, p. 370–379, 2015.
- [16] V. Rapozzi und G. Jori, *Resistance to Photodynamic Therapy in Cancer*, Springer Cham Heidelberg New York Dordrecht London: Springer International Publishing Switzerland, 2015.
- [17] R. Allison, H. Mota, V. Bagnato und C. P. Sibata, „Bio-nanotechnology and photodynamic therapy—State of the art review,“ *Photodiagnosis and Photodynamic Therapy*, Bd. 5, p. 19—28, 2008.
- [18] D. J. Robinson, M. B. Karakullukcu, B. Kruijt, S. Kanick, R. P. L. van Veen, A. Amelink, H. J. C. M. Sterenberg, M. J. H. Witjes und I. B. Tan, „Optical Spectroscopy to Guide Photodynamic Therapy of Head and Neck Tumors,“ *IEEE JOURNAL OF SELECTED TOPICS IN QUANTUM ELECTRONICS*, Bd. 16, Nr. 4, pp. 854-862, 2010.
- [19] S. Gross, A. Gilead, A. Scherz, M. Neemann und . Y. Salomon, „Monitoring photodynamic therapy of solid tumors online by BOLD-contrast MRI,“ *nature medicine*, Bd. 9, Nr. 10, pp. 1327-1331, 2003.
- [20] K. C. Blanco, L. T. Moriyama, N. M. Inada, A. G. Sálvio, P. F. C. Menezes, E. J. S. Leite, C. Kurachi und V. S. Bagnato, „Fluorescence guided PDT for optimization of the outcome of skin cancer treatment,“ *Frontiers in Physics*, Bd. 3, pp. 1-7, 2015.
- [21] A. Bogaards, A. Varma, K. Zhang, D. Zach, S. K. Bisland, E. H. Moriyama, L. Lilge, P. J. Muller and B. C. Wilson, "Fluorescence image-guided brain tumour resection with adjuvant metronomic photodynamic therapy: pre-clinical model and technology development," *Photochem. Photobiol. Sci.*, vol. 4, p. 438 – 442, 2005.
- [22] R. R. M. Allison, G. H. M. P. Downie, R. M. Cuenca, X.-H. P. Hu, C. J. M. Childs und C. H. P. Sibata, „Photosensitizers in clinical PDT,“ *Photodiagnosis and Photodynamic Therapy*, Bd. 1, p. 27—42, 2004.
- [23] R. R. M. Allison and C. H. P. Sibata, "Oncologic photodynamic therapy photosensitizers: A clinical review," *Photodiagnosis and Photodynamic Therapy*, vol. 7, p. 61—75, 2010.



Dose Management of Interventional X-ray Procedures

Sagar Shetty, Medical Systems Engineering (Msc.), Otto-von-Guericke Universität Magdeburg
E-mail :- sagar.shetty@st.ovgu.de

Introduction



- Interventional x-ray imaging is an essential part of modern day practise
- Advances in imaging technology has transformed patient care, enabling timely, effective decision making and ultimately saving lives

Reasons to implement Dose management :-

- Risks associated with x-ray radiations, as the high radiation dose involved may potentially damage the healthy tissues and cells of patients and staff
- Use of medical imaging techniques like CT & Fluoroscopy has soared in last 2 decades.
- In fact, interventional radiologists receive more radiation dose than workers in nuclear power plant per year on average.
- Pressure from several regulatory bodies such as Image gently, Image wisely, EuroSafe imaging against the use of high radiation doses.
- Introduction of standards such as European commission standards, ICRP and recently introduced Joint Commission rules 2015, have forced hospitals to track, record and improve x-ray dose performance against external benchmarks.
- Complexity of image guided procedures requiring understanding of every minute detail.

Dose Management Strategies



- Radiation dose-management programs should focus on determining the right test at the right dose in a timely fashion
- Adhering to appropriate radiation reduction techniques and using protective devices will minimize radiation exposure.

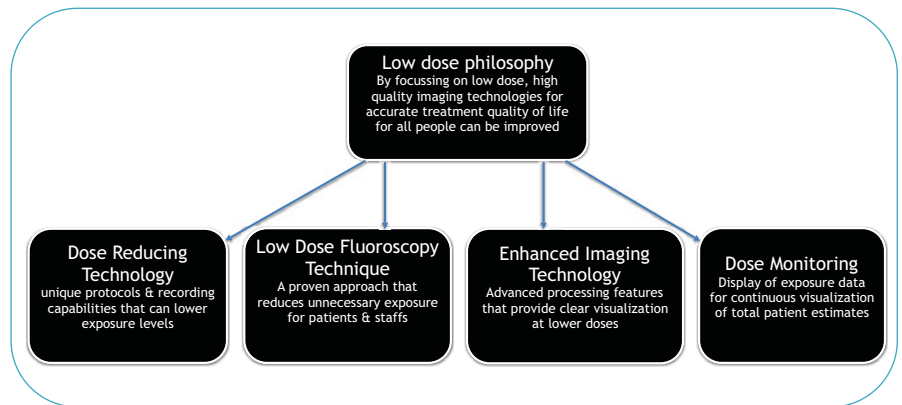


Fig. Standard dose management techniques in the operating room

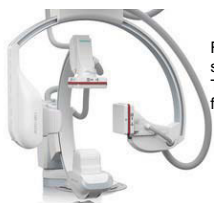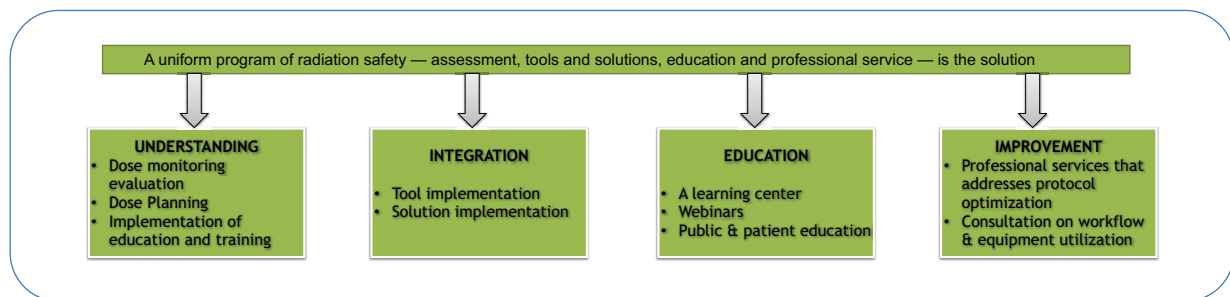


Fig. Artis Q.Zen from Siemens is one of the best Technology available for interventional x-ray imaging




Fig. Enhanced interoperability & IT integration of staff & patient Dose data is required to accurately capture, track & measure information

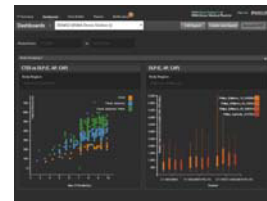

Fig. Radiation dose Information from dose monitoring software

Conclusion & Future scope

With the inventions of advanced technological tools for tracking, monitoring and recording of dose information, the healthcare providers needs to productively use these collected data in any meaningful way as a quality benchmarking tool. Therefore, the organizations will require enhanced interoperability and IT integration of both staff and patient dose data to accurately capture, track and measure information to assess quality for long term. The time is now for manufacturers, regulators and healthcare providers to work together to develop and implement cost-effective, realistic and meaningful programs to monitor radiation dose. For hospitals to comply with the new standards introduced by the Joint and European Commissions, support is needed to develop and sustain these programs. Therefore, establishing partnerships, including education on best practices to manage dose data, as well as technical support in performance quality for improved dose optimization will become critical for the future success of radiation safety programs.

References

- [1] Dominic Siewko, Philips Healthcare, The Road Ahead : The future of Radiology needs Radiation Safety Programs. <http://www.philips.com/a-w/innovationmatters/blog/the-road-ahead-the-future-of-radiology-needs-radiation-safety-programs.html>
- [2] Siemens Healthcare GmbH: Right Dose Technology; <https://www.healthcare.siemens.com/computed-tomography/technologies-innovations/care-right/right-dose-technology>
- [3] Toshiba Medical Systems Corporation: Low Dose Solution of X-ray. http://www.toshibamedicalsystems.com/products/dose/lowdose_xray/index.html
- [4] Gabriel Bartal, Elisaco Vano et al Management of Patient and Staff Radiation Dose in Interventional Radiology: Current Concepts; Cardiovasc Intervent Radiol (2014) 37:289–298 DOI 10.1007/s00270-013-0685-0.
- [5] H&HN research, (2013); "Radiation Dose Management : A patient safety priority"; <http://www.hnhmag.com/articles/6221-radiation-dose-management-a-patient-safety-priority>.

Dose Management of Interventional X-Ray Procedures

Sagar Shetty, Medical Systems Engineering (Msc.) Otto-von-Guericke Universitat Magdeburg
sagar.shetty@st.ovgu.de

ABSTRACT

A complex interventional X-ray procedure use large amount of radiation. The patients undergoing X-ray examinations are subject to a wide range of exposure levels, resulting in high radiation doses to patients as well as the staff. Therefore, Interventionalists needs to carefully plan each interventional procedure and this procedure planning should integrate radiation dose management, with the goal of an efficient and optimal use of radiation. Therefore, the review article discusses various strategies of dose management along with the future scope of reduction in dose.

Keywords: X-ray interventions, Dose Management, Radiation Protection

Abbreviations: CT Computer Tomography, SID source to detector distance, DSA Digital Subtraction Angiography, PACS Picture Archiving and Communication System, RIS Radiology Information System, ECG Electrocardiogram

1. INTRODUCTION

Interventional radiology, is an essential part of modern day medical practice. Advances in X-ray imaging technology have had a significant impact on the practice of radiology. These Advances in imaging technology has transformed patient care, enabling timely, effective decision-making and ultimately saving lives. The benefits, however, do not come without risks because these procedures use electromagnetic radiation (X-ray) for imaging and guidance therefore both the patient and medical staff receive radiation exposure. The high radiation doses involved in these procedures may potentially damage healthy cells and tissues of the patients and staff who are exposed.^{[1][2]}

There are two types of biological effects resulting from radiation exposure. They are, deterministic effects or stochastic effects. Deterministic effects results from cell death and is expressed in terms of radiation dose to a particular region that has a threshold level beyond which these effects generally occur. Deterministic risks are rarely seen with x-ray based examinations, as radiation doses typically do not reach the threshold level. The main cause of concern when it comes to x-ray based examinations are stochastic effects as they may result into cancer and genetic effects. The probability of stochastic effect depends

upon the absorbed dose. Therefore there is a need for radiation protection.^[18]

Medical imaging techniques are a necessary, as sometimes it is lifesaving. However, the use of medical imaging with high-dose radiation, including CT and fluoroscopy procedures that utilize continuous X-ray beams, has soared in the last 2 decades. In fact, interventional radiologists receive more radiation dose than workers in nuclear power plant per year on average. Several advocacy organizations, including Image Wisely and Image Gently in the U.S., and now the EuroSafe Imaging are against the hazards of too much radiation. Additionally, numerous international guidance standards have been developed, such as ICRP 105 (Radiation Protection in Medicine). The EU industry regulation and upcoming European Commission standards that was introduced recently will also have similar guidelines as that of the U.S. Joint Commission rules 2015 on patient dose, with expanded requirements for clinical decision support. While all of these coalitions are promising, there is a need of a structured radiation safety programs to ensure patient examinations are justified and dose levels are optimized.^[3] Therefore all medical procedures involving X-ray equipment must be carefully managed.

The International Commission on Radiological Protection (ICRP) has formulated three

fundamental principles for radiation protection: justification, optimization of protection, and application of dose limits. In Justification principle, for patients, the risk associated with the exposure to radiation must always be weighed against the clinical benefit of an accurate diagnosis or treatment. Justification states that, the anticipated clinical benefits should exceed all anticipated procedural risks, including radiation risk. The second principle optimization states that in all facilities and for all equipment types, procedures must be in place in order to ensure that exposures to patients, staff and the public are kept as low as reasonably achievable, taking into account economic as well as societal factors. The third principle is application of dose limits. These regulatory dose limits have been established for radiation workers and the general public (see table 1.), but these limits do not apply to doses received by a patient undergoing medical X-ray procedures. Therefore, there must always be a conscious effort to reduce patient doses to the lowest practical level along with optimal quality of diagnostic information. An effective radiation protection program while maintain a high quality medical imaging service should be established through cooperation between medical professionals and technologists.^{[2][18]}

Tissue	Risk	Recommended maximum dose	
		NCRP	ICRP
Occupational	Stochastic	50 mSv yr ⁻¹ 10 mSv × Age (yr)	100 mSv (5 yr) ⁻¹
Lens of eye	Cataract	150 mSv yr ⁻¹	
Extremities	Stochastic	500 mSv yr ⁻¹	
Embryo-fetus ^a	Stochastic	0.5 mSv month ⁻¹ 5 mSv per term ^b	1 mSv per term
General public	Stochastic	1 mSv yr ⁻¹	

10 mSv = 1 rem; Sources NCRP 116; ICRP 103.

^aAfter declaration of pregnancy

^bNRC recommendation.

Table 1. Current regulatory dose limit conditions^[12]

Interventional radiologist are very much aware of the damaging effects of these procedures and do their utmost to prevent them. They carefully plan each interventional procedure which includes consulting the referring physician, providing detailed explanation of the procedure and its benefits and risks to the patient, and obtaining informed consent, but it lacks in specific aspects of radiation dose management for the patient and radiation protection for the

staff. The recent increased emphasis on radiation safety, an essential component of safety for these procedure has reaffirmed the need for better training and advice on radiation dose management. Radiation management should become an integral part of routine procedure planning, performance, and post procedural follow-up.^[5] The development of comprehensive, radiation dose-management programs provides a systematic way for hospitals to track, report and monitor radiation dose and eliminate unnecessary exposure. This will ensure that the right test is performed on the right patient with the right dose.^[6]

Complex image-guided procedures require extensive expertise and awareness of every minute detail. The team which includes radiologists, radiologic technologists and radiation physicists must make sure that all dose management principles should be followed and must give radiation safety measures the same importance as every other safety issue. This in turn will ultimately result in shorter procedure times, shorter fluoroscopy times, and optimized radiation use.^[5]

2. DOSE MANAGEMENT

The appropriate use of radiation is an important patient safety and quality issue. Radiation dose-management programs should focus on determining the right test at the right dose in a timely fashion. Adhering to appropriate radiation reduction techniques and using protective devices will minimize radiation exposure. It can be substantially reduced by using proper body or part immobilization, motion reduction techniques, appropriate beam limitation devices and adequate filtration of the x-ray beam and specific area shielding. Selection of suitable technical exposure factors used in conjunction with either high-speed screen film combinations or computer-generated digital images, correct radiographic film-processing techniques or appropriate digital image processing, and the elimination of repeat radiographic can also contribute significantly to limit patient exposure during diagnostic x-ray procedures. Figure 1 shows some standard dose management techniques. ^[7]

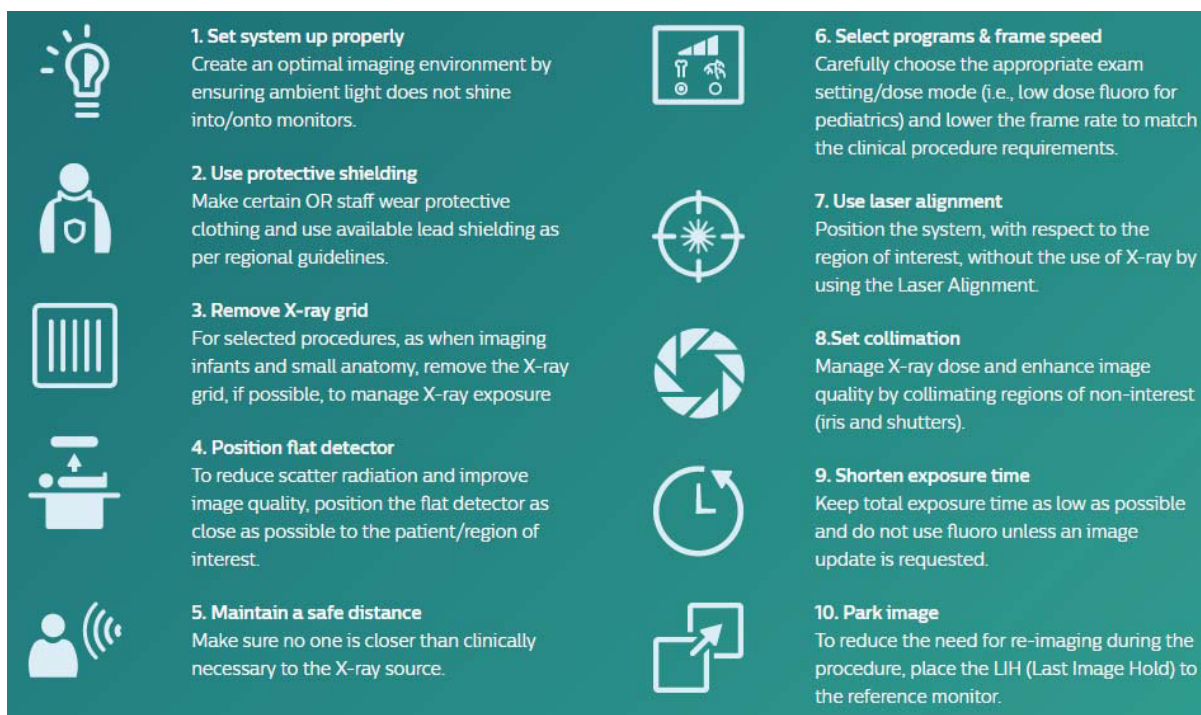

Fig. 1. Standard dose management techniques in the operating room.^[9]

2.1 Imaging Equipment

X-ray interventional procedures provide many imaging options like fluoroscopy and CT. These imaging options should be used wisely, so that it provides better imaging of normal and abnormal anatomy and better guidance for interventions.^[5] Accurate imaging and guidance in turn can improve the interventionalist's performance and shorten procedure time.

Radiation dose can be quantified in different measurements and units. First is the absorbed dose which is the intensity of energy absorbed by a tissue in body. Its unit of measurement is milligray (mGy). Second method is the equivalent dose which takes into account the amount of damaging properties of different types of radiation or it is the impact that the type of radiation has on that tissue. And its unit is millisievert (mSv). The most important one is the effective dose which takes into account the absorbed dose to all tissues as well as relative impact of the radiation and the sensitivities of each tissue. Its unit of measurement is mSv and is most useful when it comes to long term risk from a procedure as the other two are for short term.^[2] In the table 2 you can see exposure

values for different procedures involving x-rays.

<i>Procedure</i>	<i>Exposure (mR)</i>
Skull (L)	40 - 60 mR
Chest(L)	50 - 100 mR
Chest (PA)	10 - 30 mR
Breast (Mammography)	500 - 2,000 mR
Abdomen	100 - 400 mR
Lumbar Spine (L)	500 - 1,500 mR
Pelvis	250 - 500 mR
Fluoroscopy (1 min)	2,000 - 5,000 mR
Computed Tomography	1,000 - 4,000 mR

Table 2. Typical patient surface exposure values for various x-ray procedures.^[19]

In case of fluoroscopic procedures, there are four units for estimation of radiation dose: peak skin dose, reference dose, kerma-area product and fluoroscopy time. Peak skin dose is measured in grays and it is the highest radiation dose at any part of patient's skin during a procedure. But peak skin dose do not provide real-time measurements. Reference dose also

measure in grays is the air-kerma accumulated at a specific point in space relative to the gantry. It is the approximation of total dose to skin. Kerma-area product (KAP) measured in gray per centimeters square ($\text{Gy}\cdot\text{cm}^2$) is measure of total x-ray energy leaving the tube and is widely used in Europe to monitor patient dose during interventional procedures. Fluoroscopy time is the measure of time and does not indicate the dose. [18]

All modern X-ray systems use pulsed fluoroscopy where the operators can change the pulse rate for a given procedure. Pulsed fluoroscopy means delivering bursts of radiation at set intervals instead of continuous which results into large radiation doses. But here it should be noted that the pulse rate should be of reduced dose. Positioning of the image receptor should be as close as possible to the patient and the distance between the patient and the x-ray tube should be maximum as possible. Change the imaging beam angle, when the procedure is of longer duration, so that the primary beam entrance site is changed and peak skin dose is minimized as there is spreading of dose. Also, avoidance of steep angulations will decrease effective patient thickness, radiation dose rate, scatter radiation, and staff exposure. Utilization of collimation will decrease scatter radiation. Other standard dose-saving features include last image hold and store. Here when fluoroscopy is stopped, an image continues to be displayed on the monitor. The last image hold/save grab feature allows the image to be saved, thus reducing the need for another exposure. The patient's dose is decreased proportionally, the more frequently this option is used. Automatic beam filters based on calculated patient thickness and SID information provides improved optimization of dose and image quality for each clinical case. Variable dose mode offers joystick on the tableside console, the clinician can choose pre-programmed fluoroscopy modes. Fluoroscopy modes includes standard dose mode and high dose mode. In each case standard dose mode should be used. The DSA runs, usually performed for diagnosis and documentation, are responsible for about twice the radiation dose of the fluoroscopy-guided portion of the procedure. Here the radiation dose can be significantly reduced by using techniques like storing fluoroscopy loops where the image can

be stored and reviewed or representative images extracted from fluoroscopy loops instead of obtaining and storing higher-quality DSA images. This approach can be used in addition to standard techniques for dose saving, such as decreasing the number of DSA images per run and performing DSA at a lower dose rate. [5] Overall, Different combinations of dose levels, pulse rates and image processing parameters optimize dose rates and image quality for various study protocols. Also notification of dose values during the procedure is also essential. The staff should monitor and notify the operator so that excess dose is not given. The notification values are given in table 3. The complete summary including some other standard dose reduction strategies can be seen in table 4. [14][18]

Dose metric	First notification	Subsequent notifications (increments)	SRDL
$D_{\text{skin,max}}^a$	2 Gy	0.5 Gy	3 Gy
K_{air}^b	3 Gy	1 Gy	5 Gy ^b
P_{KA}^c	300 $\text{Gy}\cdot\text{cm}^{-2d}$	100 $\text{Gy}\cdot\text{cm}^{-2d}$	500 $\text{Gy}\cdot\text{cm}^{-2d}$
Fluoroscopy time	30 min	15 min	60 min

NCRP (2010) National Council on Radiation Protection and Measurements. Radiation Dose Management for Fluoroscopically Guided Interventional Medical Procedures, NCRP Report No. 168 (National Council on Radiation Protection and Measurements, Bethesda, Maryland).

^a $D_{\text{skin,max}}$ is peak skin dose, requiring calculations by physicist.

^b K_{air} is total air kerma at the reference point.

^c P_{KA} is air kerma-area product.

^dAssuming a 100 cm^2 field at the patient's skin. For other field sizes, the P_{KA} values should be adjusted proportionally to the actual procedural field size (e.g., for a field size of 50 cm^2 , the SRDL value for P_{KA} would be 250 $\text{Gy}\cdot\text{cm}^{-2}$).

Table 3. Typical values for first and subsequent notifications & substantial radiation dose level [12]

Obtain appropriate training in radiation protection and dose management
Use all available information to plan the interventional procedure
Always use all available patient dose reduction technologies
Use the lowest acceptable fluoroscopy dose rates
Use pulsed fluoroscopy at the lowest acceptable pulse rate
Avoid magnification unless it is essential
Use Last-Image-Hold and fluoroscopy loops to acquire and store images whenever these images are acceptable
Adjust the collimator blades tightly to the area of interest
Use leaded eyeglasses or ceiling-mounted shields to reduce radiation dose to the eyes
Keep the X-ray tube as far as possible from the patient and the image receptor as close as possible to the patient
Use power injectors for contrast material injections whenever feasible
Limit the use of DSA runs. Step out of the procedure room or behind a shield during DSA acquisitions

Table 4. Essentials for patient and occupational dose management [5]

In case of CT, the radiation dose descriptor is CT dose index or CTDI. It integrates the dose delivered both within and beyond the scan volume. The unit of $CTDI_{vol}$ is mGy. The other metric for measurement in CT is dose length product (DLP) which takes scan length into account. It is product of scan length and $CTDI_{vol}$. Therefore, its unit is mGy.cm. ^[11]

In CT the radiation dose is affected by scanning parameters which includes:

Scanner geometry

A single or multi detector helical CT scanner can have a long or short geometric configuration. And going by the definition of inverse square law, a short geometric scanner has more interaction of radiation with patient as compared to long. ^[11]

Tube current and potential

Decreasing the tube current is the most efficient way of reducing dose in CT. Reducing dose by 50% reduces radiation dose by half as it is proportional to the number of photons defined in an exposure time. Tube potential also causes a substantial change in radiation dose as it determines the incident x-ray energy. ^[11]

Scanning modes

It is always better to use a single helical scan as compared to multiple as multiple scan results into some amount of unused radiation which extends beyond the imaging region during initial and final acquisition. ^[11]

Scanning length

In helical scanner there is general possibility to increase the area of coverage beyond the region of interest which in turn increases the effective dose. Therefore, the examination should be restricted within the region of interest. ^[11]

Pitch, table speed and collimation

For a helical scanner, pitch is defined as table distance travelled in one 360° gantry rotation divided by the total collimated width of the x-ray beam. Therefore, all three parameters are interlinked to each other. For a given collimation with faster table speed resulting in higher pitch will eventually reduce the dose. ^[11]

Gantry rotation time

It is defined as the time taken by x-ray tube to complete one rotation of CT gantry. When the speed of rotation increases, the rotation time is decreased, in turn decreasing the exposure time and ultimately reducing the radiation dose. ^[11]

2.2 Dose Recording/Monitoring

European regulations and guidelines suggest that patient doses from interventional procedures should be measured and recorded as part of the quality assurance programs. The likes of CT and fluoroscopic devices should provide radiation dose information for use in patient medical records or a radiation dose registry. With the introduction of Digital Imaging and Communication in Medicine (DICOM), it is easy to collect and archive dosimetric and demographic data from the imaging procedures. Modality Performed Procedure Step (MPPS) and the Radiation Dose Structured Report (RDSR) are some of the services provided by DICOM. ^[5]

The regulatory also states that all individuals working in areas utilizing X-ray imaging needs to wear a personal dosimeter to keep a check on individual dose level readings. If an individual's dosimeter records an unusually high dose, a review of their practice patterns may benefit the individual, staff, and patient. ^[12]

2.3 Shielding

It is mandatory to wear protective garments by all persons who are in the procedure room when the X-ray beam is on. These garments are especially designed to protect the gonads, chest, abdomen, as they are very sensitive to radiation. The standard apron should be of 0.5-mm thickness of lead equivalent which can stop approximately 95% of scatter radiation. Radiation specific eye protection has been found to be effective as well. The glasses must fit properly for both protection and comfort, provide 0.25-mm lead equivalent protection, and have additional side shielding. Fixed barriers such as ceiling mounted shielding provide additional protection from scattered radiation. The part of the patient which is not being imaged should be protected by a transparent ceiling mounted shield with a patient contour cutout. Disposable radiation-

absorbing patient sterile drapes will also help in reducing dose to staff. [12]

2.4 Training/Education

New systems have a variety of options and control modes, therefore detailed knowledge of the system and comprehensive training are required in order to ensure dose optimization. Medical physicists, physicians, and radiographers need to master the specific features of individual units of these new systems as they act as an interface between patients and imaging technology. [5] Therefore, education and training are keys to success for this ever evolving fast paced technological development and special attention must be given to it for dose management. [6]

MEDRAPET (Medical Radiation Protection Education & Training) is a project under consortium of 6 European professional societies that aims to provide radiation protection education in Europe. It focuses on evaluating the current condition of radiation protection education and training of medical professionals as well as legislation and conducting workshops for training in radiation protection by health professional societies and national health authorities in Europe and as well as development of European guidance documents on radiation protection of medical professionals. The main aim of the MEDRAPET project is recognizing the needs in radiation protection training. The results of the project will form the basis for the revision of the Guidelines on Education and Training in Radiation Protection. [17]

3. TECHNOLOGICAL ADVANCES

Along with the strategies and technologies discussed above there are various other technological advances in modern systems using x-ray. These advances are in terms of hardware, monitoring, workflow and image reconstruction algorithms. Following are the technologies and advances in the modern x-ray systems of leading manufacturers.

3.1 Advances in Tracking and Monitoring Technology

Toshiba has developed an innovative automatic dose tracking system (Fig. 2) that provides interventionalists with real-time data on the

delivery of radiation during interventional procedures in the form of a detailed, easy-to-read color coded human map. This intuitive graphic aid highlights, with changing colors, if and when a targeted area of radiation distribution should be changed to a feature 'spread the skin dose'. This enables operators to instantaneously monitor and minimize patient radiation exposure and therefore significantly reduce the risk. [8]

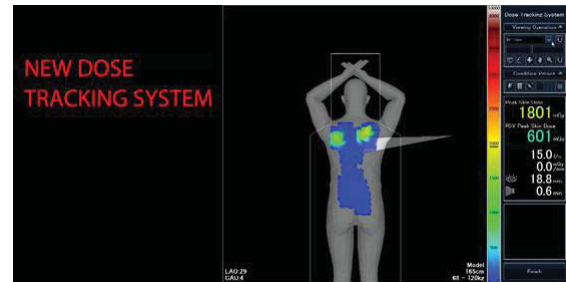


Fig. 2. Toshiba's new dose tracking system [8]

DICOM dose structured reporting are used in smart CT systems for recording dose information in standardized electronic format thus providing diagnostic reference level and quality assurance.

DoseWise Portal 2.0 from Phillip's and DoseWatch Explore from GE healthcare are similar technologies for dose management. These are web-based softwares to track, analyze and report practical data including patient radiation exposure and store it in one central application via web. [9] [13]

A built-in Dose Check alarm (Fig. 3) can be set in CT system to notify operators if an unsafe level of exposure is being requested while creating a protocol. In addition, the Radiation Exposure Monitoring Profile is available in the latest software. Its function is to automatically record all scanning data to accurately track the amount of dose for a particular patient or study. [8]

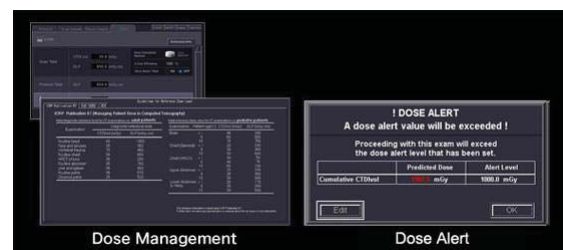


Fig. 3. Built in dose alarm system. [8]

3.2 Advances in Workflow

Artis Zeego system from Siemen's provides intelligent dose optimization. It adjusts to each individual patient and angulation. Other benefits are Automatic Exposure Control (AEC) which automatically adjusts the following five parameters depending on the C-arm angulation: tube current, exposure time, filtration, focal spot, and tube voltage. This maintains an optimal balance between image quality and dose – at all angulations. The robotic technology enables faster, smoother, swifter scanning thus resulting in lower dose. [16] SUREExposure 3D from Toshiba also provides automatic exposure control that can be programmed into every exam plan preset. Based on the user-specified level of image quality and the automatic attenuation measurements obtained from the patient scanogram, the tube current is automatically adjusted in the X, Y and Z planes to maintain image quality at a constant level. As a result, SUREExposure 3D alone can achieve a dose reduction of up to 40% depending on the individual patient and the anatomy to be scanned. [8]

Combining the benefits of helical scanning and ECG gated exposure control, SURECardio Prospective from Toshiba is able to rapidly pulse the x-rays on and off, thus exposing the patient only during the cardiac phase or phases required for the diagnostic task. In addition to achieving a reduction in patient dose of up to 80%, this proprietary multi-detector scanning technique also facilitates rapid, consistent acquisitions and shortens exam times. [8]

ECG gated scanning with slower pitch is performed for the heart, then smoothly switching to non-gated scanning with a faster pitch for the remainder of the chest. Variable Helical Pitch can achieve a reduction in radiation dose of up to 55% compared to a traditional scan. In addition to this, the amount of contrast medium can also be immensely decreased due to the shorter acquisition time. [8]

Spot Fluoroscopy allows fluoroscopy to be performed within an ROI while holding the last image outside the ROI. This reduces the patient input dose area and the scatter dose to the clinicians, and is particularly beneficial in applications requiring prolonged fluoroscopy. Spot Fluoroscopy is a unique feature in Toshiba with freely adjustable ROI sizes and collimators

that allows asymmetric collimation for off-center fluoroscopy. [8]

3.3 Advances in Hardware

The MegaCool x-ray tube (Fig. 4) used in CT systems by Toshiba, incorporates technology to reduce dose right at the x-ray source. It employs a proprietary PureFocus design that minimizes focal movement and virtually eliminates off-focal x-rays thereby reducing unnecessary radiation to the patient. This innovation features a durable copper alloy to absorb recoil electrons that may produce unwanted off-focal x-rays. Also, at both ends of the anode axis there is bearing supports, which adds stability and reduce variation in the beam, permitting high-quality imaging to be performed at much quicker speed with minimum additional patient dose from the penumbra. [8]

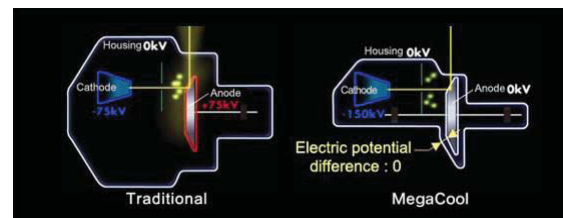


Fig. 4. Traditional x-ray tube vs Toshiba's MegaCool. [8]

CT systems can utilize Contour adaptive bowtie filters to shape the X-ray beam and remove lower energy photons before it passes through the collimators and reaches the patient. These low energy photons only contribute to patient dose and not to image signal, therefore dose efficiency of the scanner is improved. By shaping of the beam, bowtie filters can ensure the uniform distribution of photon flux along the detector and high image quality. [8]

The Quantum detector has the ability to obtain precisely machined 0.5 mm detector elements which enables the use of ultra-thin septa to optically isolate the elements resulting in an extremely high (greater than 90%) geometrical efficiency in the z-axis minimizing patient dose requirements. [8]

Easily removable grid on the flat detector makes it possible to visualize small anatomy and extremities with great image quality and excellent x-ray dose efficiency. [9]

Adaptive Dose Shield from Siemens eliminates over-radiation pre- and post-spiral to the patient. It is unique to the CT as the shield moves dynamically into place on the X-ray tube it blocks clinically irrelevant dose. The Adaptive Dose Shield dynamically opens at the beginning of a spiral range and then dynamically closes at the end. Therefore, all clinically irrelevant dose is eliminated.^[16]

Computer modelling and iterative design of gantry can ensure, that it operates with negligible vibration and with minimal electronic noise. Due to this, the potential for signal degradation from within the gantry is minimized. Specialized stealth paint can be applied to the gantry cover itself which works to shield against extraneous EMF interference. This practise of eliminating noise from the CT system increases the signal to noise ratio of the acquired images, allowing lower dose scans to be performed routinely.^[8]

3.4 Advances in Image processing technology

Toshiba has developed Boost3D, which employs an adaptive 3-dimensional algorithm which reduces pattern noise and streak artifacts. This reduction in noise and streak artifacts caused by photon starvation, the Boost3D software eliminates the need to increase the dose to obtain images of diagnostic quality.^[8]

AIDR 3D from Toshiba is an advanced iterative reconstruction algorithm. It adaptively removes photon noise in the 3D raw data domain, followed by model-based iterative noise reduction in the reconstruction process. AIDR is able to eliminate up to 50% of image noise, resulting in a dose reduction of up to 75%.^[8] Similarly, ADMIRE² (Siemens' Advanced Modeled Iterative Reconstruction) will improve the clinical images through higher resolution at organ borders and improved delineation of edges. Additionally, ADMIRE smoothly integrates iterative reconstruction in daily routine. Thick slices are now reconstructed at a more natural image impression, even from ultra-low dose scans. With this, iteratively reconstructed low dose datasets can now easily be stored in PACS or on film.^[16]

3.5 Training/Education programs

Siemens CT Dose Management Program – provides functionalities like CARE Analytics to report, document, and analyze dose. EduCARE is dedicated training program from Siemens that focus on key technologies of CT systems and their application in clinical practice. Exclusive tutorials, brochures, e-trainings, and webinars covering a wide range of topics related to achieving the right dose. Optimize CARE CT is a new consultancy program provided by Siemens Customer Service. Here, Siemens professionals guide users towards optimizing the use of radiation in order to reduce dose.^[16]

SIERRA – the Siemens Radiation Reduction Alliance Comprised of 15 international experts, creates recommendations for clinical practice around the globe for dose reduction in CT. The main objective of this alliance is to generate proposals or ideas for how manufacturers may continue to develop their technology and to help users better adapt their procedures in order to bring about further dose reduction in CT.^[16]

4. EFFECT OF NEW TECHNOLOGY

Introduction of new technology does not guarantee lower radiation doses as most interventionalists have a limited knowledge of the advanced technical features of current interventional X-ray systems. Recent introduction of Hybrid rooms which incorporate multiple imaging modalities and treatments, presents additional challenges and potential radiation hazards to the patient and staff. These rooms are typically staffed with large numbers of personnel, including surgeons, interventionalists, anesthesiologists, nurses, and radiographers. In most cases, only some members of the staff can use protective shields. Apart from that, these rooms have a limited safe space for the numerous operators as the operating table cannot be completely surrounded by ceiling-suspended or table-mounted shields. Therefore, having a better understanding of these new technologies will improve decision making during buying and using these systems.^[5]

When sophisticated and expensive equipment becomes available in hospitals and imaging

centers, there is an inevitable pressure to expand applications. This eventually leads to a rapid increase in the number of protocols and ultimately, to protocol variance and complexity. It is essential that all medical staff be educated in radiation management, trained in the complexities of the modern systems they use, and be aware of the imaging protocols and operating modes. It is also expected that simulation will play an important role in training new practitioners and maintenance of skills for current practitioners.^[15]

Another big challenge in dose management strategy is to track and monitor the dose. It is a problem as there is vast amount of data generated from imaging equipment throughout the organization. Additionally, these equipment are in multiple location as well as they are from different vendors. Therefore, an effective dose strategy has to cover more than just one type of equipment or procedure. It must be capable of automatically capturing accurate data from imaging equipment throughout the organization.^[13]

5. FUTURE SCOPE & CONCLUSION

Till recent years, the data collected from imaging equipment by hospitals, clinics or other healthcare providers were considered to be useless as 90% of generated data were discarded.^[13]

Regulating bodies such as Image Gently, Image wisely, European industry regulation and commission standards have forced health systems and radiologists to rethink their equipment, protocols, and tracking mechanisms in order to ensure full reimbursement and accreditation.^[4] And now monitoring radiation levels is of utmost importance for both providers and manufacturers, especially after The Joint Commission's new standards have been introduced in July 2015. This has led hospitals to establish stricter radiation dose

management processes and to begin focus on designing and implementing this new data into existing radiation safety programs.^[3] With the inventions of advanced technological tools for tracking, monitoring and recording of dose information, the healthcare providers needs to productively use these collected data in any meaningful way as a quality benchmarking tool.^[3] An integrated program of evidence-based best practices can aid them in capturing, tracking, reporting and monitoring radiation dose at the patient level, across the organization, integrated along with PACS and RIS.^[13] Therefore, the organizations will require enhanced interoperability and IT integration of both staff and patient dose data to accurately capture, track and measure information to assess quality for long term.^[3]

The time is now for manufacturers, regulators and healthcare providers to work together to develop and implement cost-effective, realistic and meaningful programs to monitor radiation dose. For hospitals to comply with the new standards introduced by the Joint and European Commissions, support is needed to develop and sustain these programs. Therefore, establishing partnerships, including education on best practices to manage dose data, as well as technical support in performance quality for improved dose optimization will become critical for the future success of radiation safety programs.^[3]

In the year ahead, imaging manufacturers will assist in data-driven decisions that are backed not only with innovative tools to effectively monitor and track radiation dose levels, but also with sustainable programs to further educate providers and improve radiation dose management, ultimately allowing for a safer future in diagnostic radiology.^[11] A New Radiation Dose Philosophy: "Understand, Integrate, Educate, Improve" will eventually help in reduction of dose in future.^[3]

6. REFERENCES

- [1] Authority of the Minister of Health Canada (2008) "Radiation Protection in Radiology— Large Facilities Safety Procedures for the Installation, Use and Control of X-ray Equipment in Large Medical Radiological

Facilities: Safety Code 35"; HC Pub. : 4000; Cat.: H128-1/08-545E; ISBN: 978-1-100-10289-4

- [2] X-ray, Interventional Radiology and Nuclear Medicine Radiation Safety (2016); <http://www.radiologyinfo.org/en/pdf/safety-radiation.pdf>

- [3] Dominik Siewko, Clinical Marketing Manager for DoseWise Solutions, Philips Healthcare; The Road Ahead : The future of Radiology needs Radiation Safety Programs; <http://www.philips.com/a-w/innovationmatters/blog/the-road-ahead-the-future-of-radiology-needs-radiation-safety-programs.html>
- [4] Miriam Sznycer-Taub (2016); When should the Image Gently campaign end? Two experts debate. ; <https://www.advisory.com/research/imaging-performance-partnership/the-reading-room/2016/09/future-of-image-gently-campaign>
- [5] Gabriel Bartal, Eliseo Vano et al Management of Patient and Staff Radiation Dose in Interventional Radiology: Current Concepts; Cardiovasc Intervent Radiol (2014) 37:289–298 DOI 10.1007/s00270-013-0685-0
- [6] H&HN research, (2013); "Radiation Dose Management : A patient safety priority"; <http://www.hhnmag.com/articles/6221-radiation-dose-management-a-patient-safety-priority>
- [7] Mary Alice Statkiewicz Sherer, Paula J. Visconti, E. Russell Ritenour; " Workbook for Radiation Protection in Medical Radiography
- [8] Toshiba Medical Systems Corporation; Low Dose Solution of X-ray; http://www.toshibamedicalsystems.com/products/dose/lowdose_xray/index.html
- [9] Philips Healthcare Systems; Dose management in OR; <http://www.usa.philips.com/healthcare/clinical-solutions/dosewise/dose-management-in-the-or>
- [10] Tracy L. Herrmann, et al (2012); Best Practices in Digital Radiography; American Society of Radiologic Technologists, 15000 Central Ave. SE, Albuquerque, NM 87123-3909
- [11] Mannudeep K. Kalra ; Strategies for CT Radiation Dose Optimization; (2004) DOI: <http://dx.doi.org/10.1148/radiol.2303021726>
- [12] Charles E. Chambers et al ; Radiation Safety Program for the Cardiac Catheterization Laboratory; Catheterization and Cardiovascular Interventions 00:000–000 (2011) DOI 10.1002/ccd.22867
- [13] General Electric Company; Dose management; http://www3.gehealthcare.com/en/products/dose_management
- [14] Stephen Balter ; Managing High-Dose Fluoroscopically Guided Interventional Procedures; http://www.imagewisely.org/~media/ImageWisely-Files/Fluoroscopy/Balter_High-Dose-Track.pdf
- [15] Rasu B. Shreshtha,; Enterprise Imaging: CT Radiation Dose Management; Appl Radiol. 2013;42(9):21-24
- [16] Siemens Healthcare GmbH; Right Dose Technology; <https://www.healthcare.siemens.com/computed-tomography/technologies-innovations/care-right/right-dose-technology>
- [17] MEDRAPET Project to Provide Radiation Protection Education; Volume 11 - Issue 2, 2011; <https://healthmanagement.org/c/imaging/issuearticle/medrapet-project-to-provide-radiation-protection-education>
- [18] Donald L. Miller, MD et al (2010); Clinical Radiation Management for Fluoroscopically Guided Interventional Procedures; DOI: <http://dx.doi.org/10.1148/radiol.10091269>
- [19] Perry sprawls, Physical Principles of Medical Imaging Online, Resources for Learning and Teaching, <http://www.sprawls.org/ppmi2/PATDOSE/>

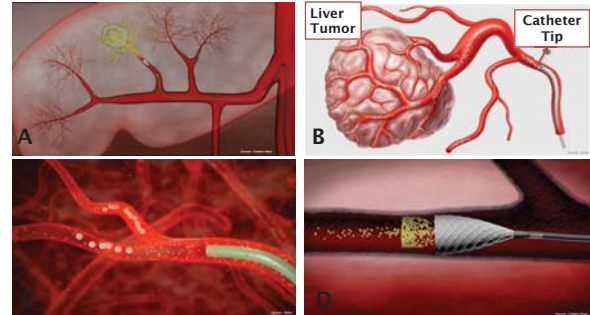
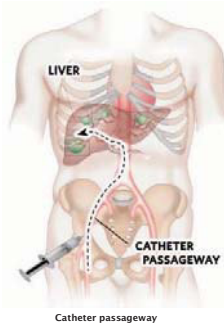


“Selective Internal Radiation Therapy”, Systems, Applications, Limitations and Future

Parisa Parsanejad
Medical Systems Engineering, Faculty of Electrical Engineering and Information Technology
Otto von Guericke University Magdeburg, January 2017
Parisa.parsanejad@st.ovgu.de

Introduction

Selective Internal Radiation Therapy (SIRT) is a promising treatment for primary or secondary liver tumor. In this method, radioactive particles (microspheres) deliver high dose of radiation via the hepatic artery, and lodge in the tumor blood vessels, where they emit their radiation locally and kill active tumor cells. Due to the fact that liver tumors are fed predominately from the hepatic artery and the normal liver is supplied by the hepatic portal vein the tumor can be selectively targeted and radiated while healthy tissues are relatively unaffected.




A: The catheter is guided through the artery into the liver; B, C, D: The microspheres are administered through the catheter.

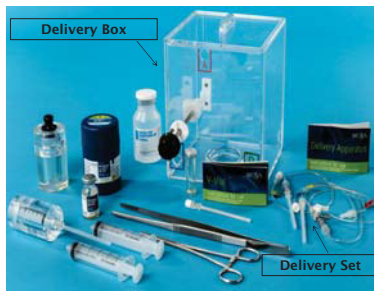Materials and Methods

Materials

- Y-90 microspheres
- administration tools
- Delivery box
- Radioisotope Materials



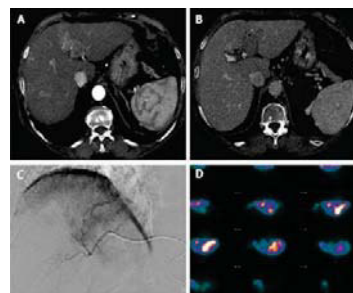

microscope's view of the tiny radioactive beads



Full delivery set of SIR-Spheres Y-90 resin microspheres and administration tools.

Candidates for SIRT

- Patients with liver tumor larger than 2 cm
- Capability to undergo diagnostic angiography and visceral catheterization
- Life expectancy less than 3 months
- Patients must have a sufficiently healthy liver
- women who are not pregnant or breast-feeding



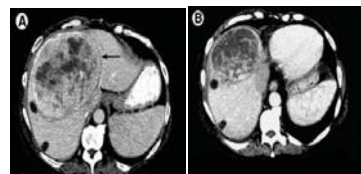
A and B: The pretreatment computed tomography (CT) showing infiltrative hepatocellular carcinoma in the IV segment; C: The pretreatment 99mTc-MAA single photon emission computed tomography image that reveal the corresponding uptake of MAA by the region of interest.

Pretreatment Evaluation

- Laboratory Test
- Triphasic Liver CT or MRI
- Angiography
- Technetium-99m Labeled (^{99m}Tc-MAA) Scan
- Dose Calculation for Microspheres

Post-Treatment Assessment

- Imaging triphasic CT or MRI, or diffusion-weighted imaging, or SPECT/CT, or PET/CT
- Laboratory Evaluation liver function studies complete blood count tumor markers

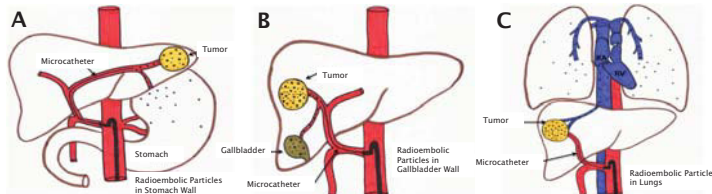


A: Pretreatment computed tomography (CT) shows a large central hypervascular lesion (black arrow); B: CT 3 months after SIRT showing a significant reduction in lesion size

Limitations, New Approaches, and Future

Main SIRT Limitation

- Occlusion of extrahepatic arteries that supply the liver with coil embolization



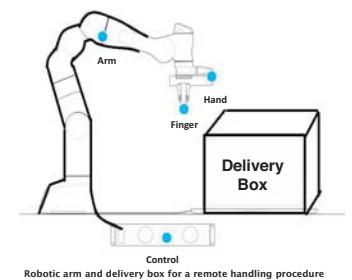
A: Schematic representation of aberrant microsphere deposition in the stomach/intestine; B: Schematic representation of aberrant microsphere deposition in the gallbladder wall; C: Schematic representation of aberrant microsphere deposition in the lungs.

Future Prospect

- better mapping of microspheres distribution
- quantification of radiological parameters
- remote handling equipment

New Approaches

- Single Session SIRT
- Radiation Segmentectomy



Conclusion

SIRT is an effective treatment for liver cancer due to the high dose of radiation that can be safely delivered to partial liver volumes. Even though the surgery is the preferred option for resectable liver cancer, SIRT can be used to shrink large tumors and make them resectable. The studies have provided data which prove that SIRT has a higher tumor response and less post-embolization symptoms in comparison to other treatments for liver cancer. The significant complications of this method mainly come from the inadvertent injection of the microspheres and if it is prevented then SIRT would be very safe procedure.

References

- [1] Smits, Maarten L.J., et al. "Radioembolization dosimetry: the road ahead." Cardiovascular and interventional radiology 38.2 (2015): 261-269.
- [2] Rhee, Thomas K., et al. "Tumor response after yttrium-90 radioembolization for hepatocellular carcinoma: comparison of diffusion-weighted functional MR imaging with anatomic MR imaging." Journal of Vascular and Interventional Radiology 19.8 (2008): 1180-1186.
- [3] Stubbs, R. S., and S. K. Wickremesekera. "Selective internal radiation therapy (SIRT): a new modality for treating patients with colorectal liver metastases." Hpb 6.3 (2004): 133-139.
- [4] Gates, Vanessa L., et al. "Outpatient single-session yttrium-90 glass microsphere radioembolization." Journal of Vascular and Interventional Radiology 25.2 (2014): 266-270.
- [5] Riaz, Ahsun, et al. "Radiation segmentectomy: a novel approach to increase safety and efficacy of radioembolization." International Journal of Radiation Oncology Biology Physics 79.1 (2011): 163-171.
- [6] Riaz, Ahsun, Rafia Awais, and Riad Salem. "Side effects of yttrium-90 radioembolization." Frontiers in oncology 4 (2014).
- [7] www.sirtex.com
- [8] www.franka.de

Selective Internal Radiation Therapy: Systems, Applications, Limitations and Future

Parisa Parsanejad

December 2016,

Medical Systems Engineering,

Faculty of Electrical Engineering and Information Technology,

Otto von Guericke University Magdeburg

Abstract—Selective internal radiation therapy (SIRT) also known as radioembolization is a targeted treatment for non-operable liver tumors, which delivers millions of radioactive microspheres directly to liver tumors. Biocompatible microspheres which are embedded with Yttrium-90 deliver beta radiation to the target area, and they are also small enough (about 32 microns in diameter) to flow through hepatic arteries. The treatment is well tolerated with high level of efficacy. The main complications are caused by traveling microspheres into the gastrointestinal tract, which pass from the liver. Novel approaches must be introduced to compensate the limitations in this method.

Index Terms—Selective internal radiation therapy; Radioembolization; Yttrium-90; Gastrointestinal tract

Abbreviations—SIRT, Selective internal radiation therapy; HCC, Hepatocellular carcinoma; ⁹⁰Y, Yttrium 90; CRC, colorectal cancer; HDE, Humanitarian device exemption; GDA, Duodenal Artery; RGA, Right gastric artery; MAA, Macro-aggregated albumin; SPECT, Single photon emission computed tomography; Lung shunting fraction, LSF; BSA, Body surface area; WHO, World health organization; RECIST, Response evaluation criteria in solid tumors; MRECIST, Modified response evaluation criteria in solid tumors; EASL, European association for the study of the liver; PRS, Post-radioembolization syndrome

I. INTRODUCTION

Sixty to eighty percent of patients with a history of colorectal carcinoma, breast cancer, neuroendocrine tumors, pancreatic carcinoma and other tumors will in the end progress liver metastases [1]. In addition, primary liver cancer, especially hepatocellular carcinoma (HCC), is one of the most common tumors which causes cancer related mortality. Since the liver is an essential organ and plays a vital role to manage the body chemistry, hepatic tumor has a direct effect on survival of patients with primary or secondary liver cancer [2]. Although resection of liver metastases can

result in long-term survival, only 10-20 % of patients with metastatic disease are suitable for resection [3, 4]. In addition, there are some limitations for the use of external beam radiation for the treatment of liver tumors. The most important limitation is that a radiation of at-least 70 Gy is needed for the destruction of solid liver tumors, while the tolerance of normal liver is only about 30 Gy [24].

During recent years, selective internal radiation therapy (SIRT) or radioembolization has been developed in the treatment of primary or secondary liver cancer. In this method, radioactive particles (microspheres) deliver high dose of radiation via the hepatic artery, and lodge in the tumor blood vessels, where they emit their radiation locally and kill active tumor cells [5, 6]. Liver tumors are fed predominately from the hepatic artery while the normal liver is supplied by the hepatic portal vein [1]. By using this preferential blood supply, the tumor can be selectively targeted and radiated while healthy tissues are relatively unaffected [6].

This review paper focuses mainly on the procedures, systems and applications of SIRT, and briefly describes dosimetry calculation and tumor response to this technique. The new concepts, limitations, and the future direction for SIRT have also been discussed.

II. PROCEDURES AND METHODES

A. Search Strategy and Study Selection

In this paper, the studies are based on database searches. The electronic databases such as PubMed, ELSEVIER, Springer, IEEE, and Google Scholar are used. All articles were in English without any restriction on the date of publication. Following key terms were used to search for articles: selective internal radiation therapy (SIRT), radioembolization, intraarterial radiation therapy, Yttrium-90, hepatocellular carcinoma, delivery system for microspheres.

B. Selective Internal Radiation Therapy

SIRT is a minimally invasive therapy which can be

used in treatment of patients with primary or secondary liver tumors that are basically unresectable by surgery [2]. Based on the published data, this technique usually is used for large tumors which blood supply predominantly grows activity rim of the tumor. The radioactive microspheres distribute to the activity growing rim and provide radiation within an average range of 2.5 mm; hence, cause the tumor to shrink [25].

C. Radiotherapeutic Applications

1. Radioisotope Materials

Microspheres consist of very small beads (20-40 μm in diameter). Today, commercial microspheres use yttrium 90 (^{90}Y), but a variety of radioisotopes can be used for embedding microspheres, including: ^{198}Au , ^{63}Zn , ^{51}Cr , ^{32}P , ^{153}Sm , ^{140}Ba , ^{46}Sc , ^{113}Sn , ^{125}I , ^{153}Gd , ^{166}Ho , ^{57}Co , and ^{90}Y [8].

Yttrium 90, a pure beta emitter, is an ideal intra-arterial liver-directed agent for the treatment of liver cancer due to its unique properties. It has a short tissue penetration (mean range of 3 mm in soft tissue), with the maximum and mean particle energies of 2.26 MeV and 0.94 MeV [7]. This allows delivery of high radiation doses to hepatic tumors with minimally affecting the non-targeted tissues [14, 15]. Moreover, ^{90}Y decays to stable ^{90}Zr and has a physical half-life of 2.67 days (64.2 h); therefore no activity will be remained after 1 month [8].

2. Microspheres Proper

Different materials have been used for the microspheres proper: glass, micropolymer, resin, starch, and poly lactic acid. But, there are only two commercial ^{90}Y microspheres available and use glass and resin materials [8]. SIRSpheRes® (Sirtex Medical Ltd., Lane Cove, Australia) and TheraSphere® (MDS Nordion, Ottawa, Canada). The main difference between glass spheres and resin spheres is their activity, which in glass sphere is much higher (about 2500 Bq) compared to resin sphere (about 50 Bq) [2]. The former, resin microspheres (SIRSpheRes®), were fully approved by FDA in the USA for use in colorectal cancer (CRC) liver metastases. The later, glass microspheres (TheraSphere®), is not fully approved by FDA but has a humanitarian device exemption (HDE) for the treatment of hepatocellular carcinoma (HCC) [13].

The available data would suggest that the two commercial types of microspheres are effective with equivalent targeting aims, despite the differences between them (table 1).

TABLE 1 [20]
DIFFERENCES BETWEEN ^{90}Y MICROSPHERES

Material	Resin	Glass
Brand name	SIR-Sphere	TheraSphere
Isotope	Attached to the surface	Incorporated into glass matrix
Average size (μm)	32.5	25
Specific gravity(g/ml)	1.6	3.6
Activity per sphere (Bq)	50	2500

GI= gastrointestinal, RUQ= right upper quadrant

D. Treatment Protocol

1. Patient Selection

Decision on performing SIRT is based on collaborative decision by the tumor board including medical and surgical oncologists, vascular and interventional radiologists, and nuclear medicine specialists [9]. The criteria for patient selections are: age at-least 18 years, liver tumor larger than 2 cm, capability to undergo diagnostic angiography and visceral catheterization, life expectancy less than 3 months, pregnancy, and laboratory findings [19].

2. Pretreatment Evaluation and Staging

Once a patient has been selected for Intra arterial radiation therapy, pre-treatment evaluation should be done to ensure that the therapy is successful. This pre-treatment evaluation is usually performed 1-2 weeks before the procedure [17].

2.1 Laboratory Test

Appropriate laboratory test including liver function test and tumor markers should be performed to ascertain baseline values. Furthermore, for patients with cirrhosis the Child-Pugh classification is commonly employed which includes test on serum bilirubin, serum albumin, encephalopathy, ascites, and the prothrombin time (PT)/the international normalized ratio [17].

2.2 Triphasic Liver CT or MRI

A triphasic liver CT or MRI is usually performed to evaluate extent and location of tumor, relative tumor hypervascularity, and variant vascular anatomy [17]. Also, CT scan is helpful to identify tumor margin, central hypervascularity pattern, and hepatopulmonary fraction (Figure 1, A and B) [14].

2.3 Angiography

An initial angiography is performed to document the hepatic arterial anatomy, evaluate the anatomic variants, and patency of portal vein [10, 11]. In

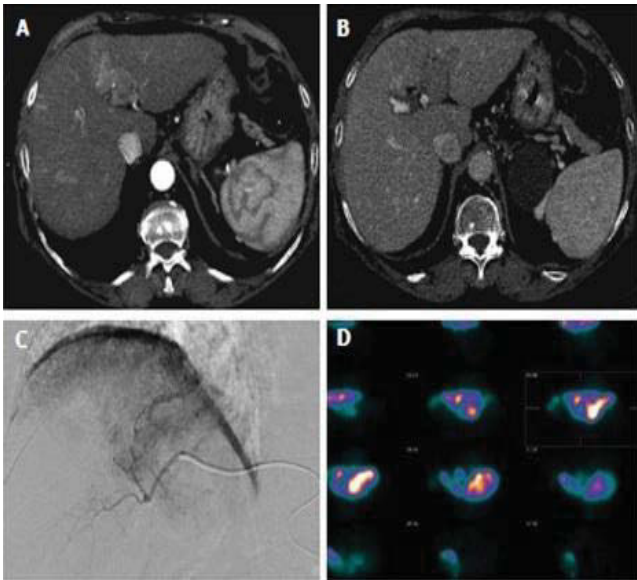


Figure 1: Treatment with Yttrium-90 of infiltrative hepatocellular carcinoma. A and B: The pretreatment computed tomography (CT) showing infiltrative hepatocellular carcinoma in the IV segment; C: The pretreatment angiogram carried out with selective catheterization of the left hepatic artery, arising from the left gastric artery, confirms the hypervascularization of the venous thrombus; D: The pretreatment ^{99m}Tc -MAA single photon emission computed tomography image that reveal the corresponding uptake of MAA by the region of interest [23].

addition, angiography is necessary for the occlusion of extrahepatic arteries that supply the liver, with coil embolization. The common extrahepatic arteries that may be coil embolized prior to therapy are the Gastro Duodenal Artery (GDA) and the Right Gastric Artery (RGA) [14].

The GDA runs along the posterior aspect of the first part of the duodenum, giving rise to the anterosuperior pancreaticoduodenal artery, next to the upper part of the pancreas and divides into the inferior pancreaticoduodenal artery and the gastro-epiploic artery, running to the inferior edge of the duodenum. This artery is always present and can be identified both on CT and arteriography. This is occluded by coiling (hydrocoils or metal coils) prior to the treatment because reflux of microspheres into the GDA causes a risk of pancreatitis and gastroduodenal ulceration [16]. The second commonly occluded artery is the RGA, which arises from the main hepatic artery [14]. Catheterization of RGA often can be performed by microcatheter (2.1/1.7 or 2.3/2.8 French)-microguides (0.014 in) couples, and 1.5 or 2 mm diameter coils. It is important to ensure about the occlusion of the most proximal part due to presence of dividing branches (Figure1, C) [16].

2.4 Technetium-99m Labeled (^{99m}Tc -MAA) Scan

In order to assess the presence of extra hepatic shunting, ^{99m}Tc -macro-aggregated albumin (MAA) is injected, and image of liver, lungs, and abdomen is

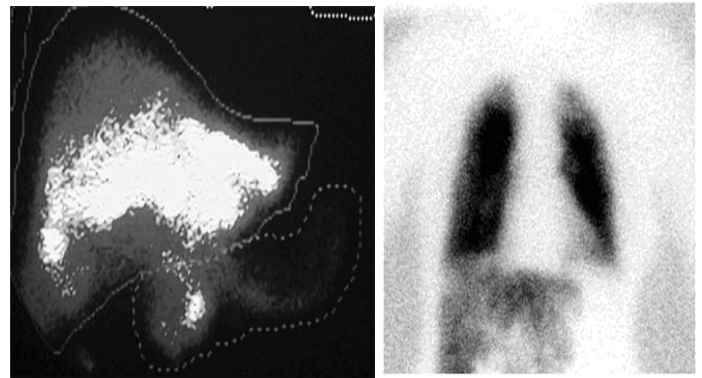


Figure 2: Tc-99m Macroaggregated albumin scan. A: Scan showing some isotope distribution to the duodenum and pancreas. This was due to pancreaticoduodenal artery that had not been ligated. Selective internal radiation therapy was not administered. B: Planar TC-99m scan demonstrating high LSF (76%) [13,17]

obtained with single photon emission computed tomography (SPECT) combined with computed tomography (CT) [6]. Because the MAA aggregates are of comparable size to the microspheres, their distribution after hepatic arterial delivery will be similar to that of administered micro-spheres (Figure 1, D) [13]. The material should not be administered if there was significant shunting to the lungs or other organs (Figure 2) [12].

In every patient, calculation of the lung shout is performed in order to prevent the deposition of critical level of activity in the lungs. By means of Lung Shunting Fraction (LSF), it would be possible to reduce the total administrated dose of microspheres to the liver so that the amount of radiation dose to the lungs is reduced [6]. If LSF is less than 10%, reduction in dose is not necessary. If it is 10-15%, the dose should be reduced by a factor of 20%, and for LSF 15-20%, the dose should be diminished by the factor of 40%. For LSF greater than 20%, treatment is not successful [17].

The cumulative absorbed radiation dose to the lungs (Gy) can be calculated as follows:

$$=50 \times \text{lung mass} \sum_{i=1}^n A \times LSF \quad (1)$$

A=activity infused, n= number of infusions, and total lung mass is assumed to be 1 kg. LSF (lung shunting fraction) can be calculated from total counts within regions of interest over the livers and both lobes, using the geometrical mean of the anterior and posterior projections [6].

2.5 Dose Calculation for Microspheres

First approach to quantify the radiation dose delivered via radioactive microspheres date back to the early 1950s using animal models. An important limitation for SIRT is the amount of dose to the liver because an excessive dose to the normal liver parenchyma may lead to liver failure. The spatial

distribution of the microspheres is crucial which is very different for the two types of spheres. For resin microspheres, the dose absorbed by the normal liver should be kept lower than 40 Gy to minimize the risk of liver failure [23].

2.5.1 Resin Spheres

There are two methods to calculate the dose for resin spheres. The first method is based on the extent of tumor burden which per 25% tumor burden the recommended activity is 0.5 GBq. The second method utilizes body surface area (BSA, is measured in square meters) [18]:

$$BSA (m^2) = 0.20247 \times \text{height (m)} 0.725 \times \text{weight (kg)} \quad (2)$$

The activity (A) of the resin spheres can be calculated as in (3):

$$A (GBq) = (BSA-0.2) + \frac{\text{tumor volume}}{\text{total liver volume}} \quad (3)$$

To obtain the liver volume, CT or MR imaging is performed [14].

2.5.2 Glass Spheres

The following equation can be used to calculate the activity of glass spheres:

$$A (GBq) = \frac{D (Gy) \times M (kg)}{50} \quad (4)$$

A is activity, D is target dose, and M is the target liver mass. The dose delivered to the tumor is not known by the above formula; hence, by supposing that tumors have a higher vascularity than normal parenchyma, the prescribed dose is a minimum dose which is absorbed by the tumor in order to prevent liver fibrosis [23]. It should be noted that intrinsic differences between the two types of microspheres such as their different numbers and specific activities are responsible for the different distribution of the microspheres inside the tissues, which is more uniform for resin than for glass microspheres [23].

3. Administration Set-Up

The administration of the SIR-Spheres Y-90 microspheres must be performed by an Interventional radiologist. This technique uses Y90 impregnated glass or resin microspheres, which are transferred to liver tumors by inserting a catheter into the hepatic artery on the X-ray guidance (figure 3). The diameters of the glass or resin microspheres (20-30 microns versus 20-60 microns, respectively) allow them to become permanently implanted in the terminal arterioles of the tumor [14].

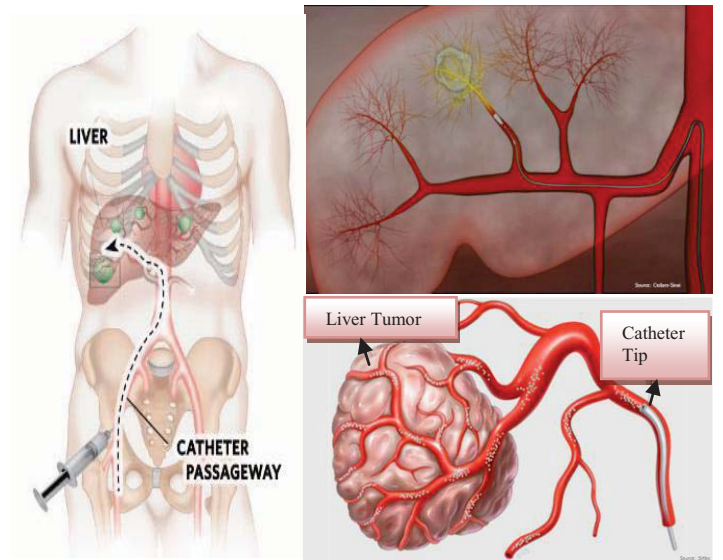


Figure 3: Administration of microspheres. A: catheter passage way; B: The catheter is guided through the artery into the liver; C: The microspheres are administrated through this catheter.

3.1 Delivery Apparatus

Delivery apparatus is a new system designed by SIRTEX company for delivery of SIR-Spheres ⁹⁰Y resin microspheres which provides a safe environment for the implant procedure. It consists of a delivery set, delivery box, a V-Vial holder, microspheres, and two 20 ml syringes filled with water for injection (figure 4) [3]. The delivery box with the V-Vial holder shields the operating room staff from beta radiation emitted by microspheres. The delivery set and V-Vial are used for the delivery of microspheres [25].

Microspheres can be administrated via the hepatic artery by one of two ways: a trans-femoral catheter, or an implanted hepatic artery port. If a needle is used to puncture an implanted hepatic artery port, the internal diameter of the needle should not be less than 0.65mm. If a port is used to deliver microspheres, the catheter must be placed correctly so that the microspheres go

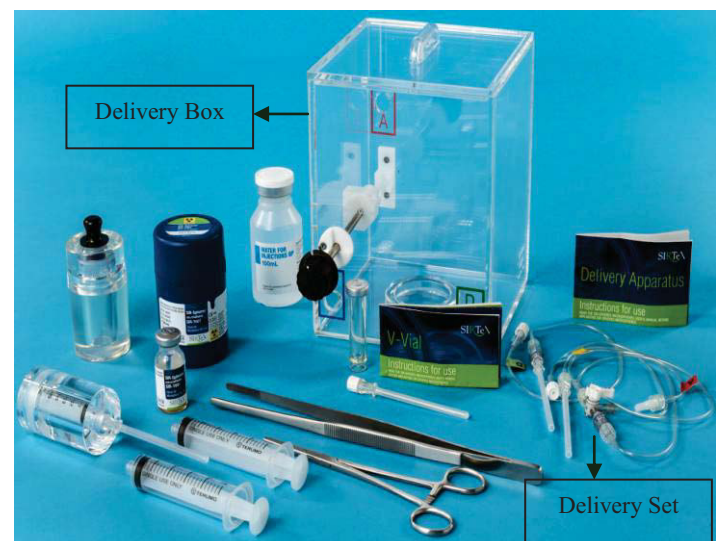

Figure 4: Full delivery set of SIR-Spheres Y-90 resin microspheres and administration tools.

only to the liver not to any other organs. If a trans-femoral catheter is used, its internal diameter should be large enough to prevent blocking. In most cases, use of micro-catheter is preferable [25].

The delivery apparatus should be assembled in close proximity to the patient. And each line is placed correctly in the delivery box. When the apparatus is fully assembled, the water from the syringe on the tube D is injected which cause the microspheres to agitate and pass into tube C and then into tube A that is connected to the patient. It is important to inject slowly at a rate of not more than 5 mL per minute, in order to reduce the possibility of the microspheres refluxing back down the hepatic artery and into other organs [25].

3.2 Trans-Femoral Implantation

In this method of implantation, the hepatic artery catheter is inserted via the femoral artery under X-ray guidance. When the catheter has been correctly placed in the hepatic artery, the end of the catheter is connected to the microspheres delivery set. Then SIR-Spheres microspheres delivered into the trans-femoral catheter. During procedure, the surgeon should periodically stop the delivery of microspheres and inject contrast agent through tube B and perform fluoroscopy. This is an important step to ensure the catheter remains correctly and no reflux is occurring [25].

3.3 Hepatic Artery Port Implantation

This method of implantation is used if the port were also to be used for other treatment, such as hepatic perfusion chemotherapy. This is commonly performed for patients with liver metastases and chemotherapy is added to enhance the effect of SIR-Spheres microspheres. For this method, the hepatic artery catheter is placed into the arterial supply of the liver so that all the liver is irradiated. Before implantation of microspheres, several factors should be noted. These may include removal of primary cancer elsewhere, removal of the gallbladder or the implantation of the port and catheter [25].

4. Post-Treatment Assessment

After treatment procedure, patients undergo post-treatment imaging and laboratory evaluation to assess the response to treatment [17]. The time interval for post-treatment assessment varies among authors and clinical institutions.

4.1 Post Treatment Imaging

Post treatment imaging usually shows any change in both the appearance of the tumor and the liver surrounding (figure 5) [23]. According to the study by Riaz, Awais, and Salem, cross-sectional enhanced

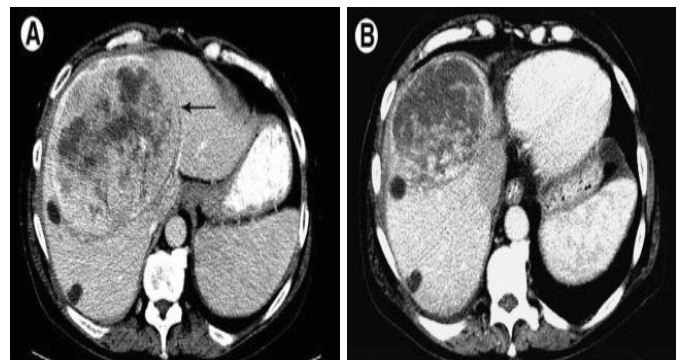


Figure 5: Post treatment assessment. A: Pretreatment computed tomography (CT) shows a large central hypervascular lesion (black arrow); B: CT 3 months after SIRT showing a significant reduction in lesion size [10].

imaging (triphase CT or MRI) is obtained at 1 month following treatment and at 3 month intervals following the first post-treatment imaging. This procedure is done to evaluate response to treatment, or lack thereof [17]. Usually, computed tomography is capable of identifying changes in the tumor size and alterations in vascularity; however, magnetic resonance imaging, especially diffusion-weighted imaging (DW-MRI) identify necrosis and cell death [23]. Furthermore, for evaluating post-treatment technical success and assessing treatment efficacy, Bremsstrahlung SPECT/CT and/or PET/CT are being investigated [17]. In a study conducted by Gupta et al. has reported a case of aberrant delivery of ^{90}Y to the duodenum identified on PET/CT which performed after intra arterial radiation therapy or radioembolization [18].

4.2 Post Treatment Laboratory Evaluation

Laboratory tests are usually performed 1 month following treatment which include liver function studies, complete blood count and tumor markers (alpha-fetoprotein for HCC) [17].

E. Tumor Efficacy

There are four guidelines to assess tumor response following therapy, World Health Organization (WHO), Response Evaluation Criteria in Solid Tumors (RECIST), Modified Response Evaluation Criteria in solid tumors (mRECIST), and the European Association for the Study of the Liver (EASL) [14]. The mRECIST which is an amended version of RECIST, suggests the concept of viable tumor and evaluate the tumor response after therapeutic strategy. The EASL guidelines fulfills the limitations of the both WHO and RECIST guidelines, which are based on systematic resulting in limitation for loco-regional therapies such as SIRT [14].

Rhee and Naik in their study investigated the use of diffusion-weighted imaging DWI application in early determination of the response or failure of Y-90-SIRT in HCC [19].

III. COMPLICATIONS OF SIRT

A. Clinical Complications

Even though the studies have shown that SIRT using ^{90}Y is a safe and efficient treatment for unresectable liver cancers, several complications after therapy may occur (table 2) [17]. For instance, patients may experience post-radioembolization syndrome (PRS) includes fatigue, nausea/vomiting, abdominal pain/discomfort, and cachexia [17]. Other complications include: hepatic dysfunction, biliary sequelae, radiation pneumonitis, gastrointestinal (GI) complications, acute pancreatitis, thrombocytopenia, radiation dermatitis, contrast induced nephrotoxicity, allergic reaction to iodinated contrast media and vascular injury [14].

B. Technical Limitations

Catheterization of the Right Gastric Artery (RGA) is the main problem in occlusion of extrahepatic arteries because of its narrow diameter, tight proximal angle, and a great number of anatomical variants [16]. To facilitate catheterization during arteriography, multiplanar CT reconstructions are helpful in some cases to identify its angle [16]. Current investigations suggest several technical options to occlude RGA, but they bring other complications such as ischemia cholecystitis [16].

IV. NEW APPROACHES

According to literatures description, the first work with radioactive microspheres dating back to the 1940s for the treatment of lung tumor. In addition, application of microspheres with a variety of materials and radioisotopes for hepatic malignancies dates back several decades. Clinical investigation of SIRT in this modern form dates back to the 1980s [21]. The use of SIRT has led to the discovery of several novel concepts for the liver cancer treatment.

A. Single Session SIRT

In a recently published method by Gates VL and Marshall KG, SIRT (pre-treatment angiography, Tc-99m MAA scan, and SIRT) was performed in one session which there were no reportable medical events. In this method, patients were administrated of Tc-99m MAA via a microcatheter in a hepatic artery supplying the tumor. Planar scintigraphy was performed after 2 hours of Tc-99m MAA administration and the lung shunt fraction was determined. The final dosimetry calculation was done while the patient was being transferred back from nuclear medicine to interventional radiology. The most important advantage of this new approach is decrease in cost and time between initial clinical assessment and SIRT [21].

TABLE 2 [12, 14, 17,]
SUMMARY OF POST- ^{90}Y SIRT COMPLICATIONS

Complications	Findings	Prevent/Treatment
HEPATIC		
<i>Hepatic dysfunction</i>	Hepatomegaly, ascites, jaundice, elevated serum transminases	Aggressive therapy to control symptoms from abdominal ascites
EXTRAHEPATIC		
<i>GI</i>	Nausea, vomiting, fatigue, abdominal pain/discomfort, and/or cachexia	Antiemetics for nausea, vomiting; steroids
<i>Biliary</i>	Fever, jaundice, RUQ	Coiling cystic artery, antibiotics, conservative management/ percutaneous drainage
<i>Pancreatic</i>	Severe epigastric or periumbilical pain	Conservative treatment
<i>pulmonary</i>	Radiation pneumonitis	Delivery of Y90 to lungs <30 Gy in one treatment
<i>Vascular</i>	Vascular injury	May prevent by stopping blood thinners appropriately
<i>Hematology</i>	Diffusion of microspheres in falciform artery Patient may have greater than 25% of their lymphocyte count decrease	May prevent by coiling artery
<i>Immunology</i>	Allergic reaction to iodinated contrast	Anti-histamine and/or steroids

GI= gastrointestinal, RUQ= right upper quadrant

B. Radiation Segmentectomy

Radiation segmentectomy is defined as radioembolization of two or fewer hepatic segments which allows for more focused delivery of radiation to a much smaller area. In this novel approach less amount of radiation is exposed to normal liver parenchyma which increases safety and efficacy of SIRT [22].

V. FUTURE PROSPECTS

Due to the high dose of radiation that can be safely delivered to partial liver volumes, SIRT is a valuable treatment technique for those tumors that are not suitable for ablation. Furthermore, SIRT has a good patient tolerance regarding to abdominal pain, length of hospitalization and post-embolization symptoms [20].

Effectiveness of SIRT, as other types of therapy, mostly depends on the cost and availability. SIRT is a

complicated therapy which requires a group of different specialists and surgeons. In addition, the high cost of radioactive microspheres, pre and post-treatment laboratory tests and imaging make SIRT a relatively expensive therapy. As a result, prospective evaluation should be done in this respect [20].

To limit the shunting dose to lung, GI, or other organs, future investigations are needed to improve methods for delivery of Y90 microspheres to tumor nodules. It may include better mapping of microspheres distribution and quantification of radiological parameters such as radiation dose and specific microspheres activity more accurately [6, 12].

Due to the radioactivity of this technique and the significant consequences of incorrect placement of the microspheres, more studies should work on the safety and effectiveness of microspheres in pregnant women, nursing mothers or children [25].

Surgeon and nuclear specialist who administer microspheres are absorbing the most radiation dose during the procedure. To decrease the radiation exposure, distance between staff and radiation source should be increased. Furthermore, beta emissions from yttrium-90 are absorbed by air; hence, the double distance rule reduces the radiation exposure to 25%. Use of remote handling equipment is the best way to increase the distance. For example, the delivery box can be designed such that the surgeon and nuclear specialist do not need to leave the monitoring room for the injection of microspheres. Instead a remote handled actuator controlled by the surgeon would do the job.

VI. CONCLUSION

Selective internal radiation therapy (SIRT) is an effective treatment for either primary liver cancer or secondary liver disease. Even though the surgery is the preferred option for resectable liver cancer, SIRT can be used to shrink large tumors and make them resectable. The studies have provided data which prove that SIRT has a higher tumor response and less post-embolization symptoms in comparison to other treatments for liver cancer. The significant complications of this method mainly come from the inadvertent injection of the microspheres and if it is prevented then SIRT would be very safe procedure. However, as mentioned by [20], the European Organization for research and Treatment of Cancer, and the American Association for the Study of Liver Diseases do not recommend Y90-SIRT as a standard therapy for intermediate or advanced HCC outside the clinical trial. SIRT may become widely accepted and incorporated into the treatment guidelines [20], if

further research improves the limitations in this technique.

REFERENCES

- [1] Salem, Riad, and Kenneth G. Thurston. "Radioembolization with 90 Yttrium microspheres: a state-of-the-art brachytherapy treatment for primary and secondary liver malignancies: part 1: Technical and methodologic considerations." *Journal of vascular and interventional radiology* 17.8 (2006): 1251-1278.
- [2] Prompers, L., et al. "Selective internal radiation therapy (SIRT) in primary or secondary liver cancer." *Methods* 55.3 (2011): 253-257.
- [3] Ettorre, Giuseppe Maria, et al. "Yttrium-90 Radioembolization for Hepatocellular Carcinoma Prior to Liver Transplantation." *World Journal of Surgery* (2016): 1-9.
- [4] Townsend, Amanda, Timothy Price, and Christos Karapetis. "Selective internal radiation therapy for liver metastases from colorectal cancer." *The Cochrane Library* (2009).
- [5] Jakobs, Tobias. "Selective internal radiation therapy for other liver metastases." *European Journal of Cancer Supplements* 10.3 (2012): 72-74.
- [6] Smits, Maarten LJ, et al. "Radioembolization dosimetry: the road ahead." *Cardiovascular and interventional radiology* 38.2 (2015): 261-269.
- [7] Goedicke, Andreas, et al. "Study-parameter impact in quantitative 90-yttrium PET imaging for radioembolization treatment monitoring and dosimetry." *IEEE transactions on medical imaging* 32.3 (2013): 485-492.
- [8] Welsh, James S., Andrew S. Kennedy, and Bruce Thomadsen. "Selective Internal Radiation Therapy (SIRT) for liver metastases secondary to colorectal adenocarcinoma." *International Journal of Radiation Oncology* Biology* Physics* 66.2 (2006): S62-S73.
- [9] Welsh, James S., Andrew S. Kennedy, and Bruce Thomadsen. "Selective Internal Radiation Therapy (SIRT) for liver metastases secondary to colorectal adenocarcinoma." *International Journal of Radiation Oncology* Biology* Physics* 66.2 (2006): S62-S73.
- [10] Geschwind, Jean Francois H., et al. "Yttrium-90 microspheres for the treatment of hepatocellular carcinoma." *Gastroenterology* 127.5 (2004): S194-S205.
- [11] Lewandowski, Robert J., et al. "Radioembolization with 90Y microspheres:

- angiographic and technical considerations." *Cardiovascular and interventional radiology* 30.4 (2007): 571-592.
- [12] Dancey, Janet E., et al. "Treatment of nonresectable hepatocellular carcinoma with intrahepatic ⁹⁰Y-microspheres." *Journal of nuclear medicine* 41.10 (2000): 1673-1681.
- [13] Stubbs, R. S., and S. K. Wickremesekera. "Selective internal radiation therapy (SIRT): a new modality for treating patients with colorectal liver metastases." *Hpb* 6.3 (2004): 133-139.
- [14] Stubbs, R. S., and S. K. Wickremesekera. "Selective internal radiation therapy (SIRT): a new modality for treating patients with colorectal liver metastases." *Hpb* 6.3 (2004): 133-139.
- [15] for Research, European Organisation, and European Association for the Study of the Liver. "EASL–EORTC Clinical Practice Guidelines: management of hepatocellular carcinoma." *Journal of hepatology* 56.4 (2012): 908-943.
- [16] Vesselle, G., et al. "Radioembolization with yttrium-90 microspheres work up: practical approach and literature review." *Diagnostic and interventional imaging* 96.6 (2015): 547-562.
- [17] Riaz, Ahsun, Rafia Awais, and Riad Salem. "Side effects of yttrium-90 radioembolization." *Frontiers in oncology* 4 (2014).
- [18] Gupta, Amit, et al. "Nontargeted Y-90 microsphere radioembolization to duodenum visualized on Y-90 PET/CT and Bremsstrahlung SPECT/CT." *Clinical nuclear medicine* 37.1 (2012): 98-99.
- [19] Rhee, Thomas K., et al. "Tumor response after yttrium-90 radioembolization for hepatocellular carcinoma: comparison of diffusion-weighted functional MR imaging with anatomic MR imaging." *Journal of Vascular and Interventional Radiology* 19.8 (2008): 1180-1186.
- [20] Sangro, Bruno, Mercedes Iñarrairaegui, and Jose I. Bilbao. "Radioembolization for hepatocellular carcinoma." *Journal of hepatology* 56.2 (2012): 464-473.
- [21] Gates, Vanessa L., et al. "Outpatient single-session yttrium-90 glass microsphere radioembolization." *Journal of Vascular and Interventional Radiology* 25.2 (2014): 266-270.
- [22] Riaz, Ahsun, et al. "Radiation segmentectomy: a novel approach to increase safety and efficacy of radioembolization." *International Journal of Radiation Oncology* Biology* Physics* 79.1 (2011): 163-171.
- [23] Mosconi, Cristina, et al. "Radioembolization with Yttrium-90 microspheres in hepatocellular carcinoma: Role and perspectives." *World J Hepatol* 7.5 (2015): 738-752.
- [24] Mahnken, Andreas H. "Current status of transarterial radioembolization." *World journal of radiology* 8.5 (2016): 449.
- [25] SIRTEX, "Medical Training Manual", www.sirtex.com
- [26] Figure3,4: <http://www.sirtex.com>

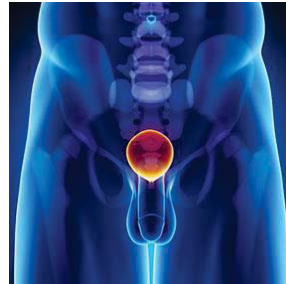


Bladder tumor treatment with IGP. How could we improve this?

Marco Ferrari – Medical Systems Engineering 2017 – OVGU Magdeburg, Germany

Introduction

Bladder cancer is a type of cancer that develops in the bladder. This poster introduces the cancer and explains the treatments available, especially the ones guided by imaging. It also highlights the advantages and deficits.



Quick Facts (U.S. 2016)[1]

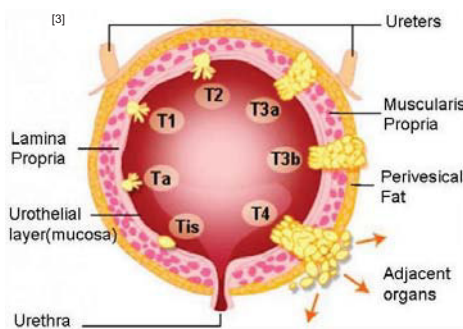
- 76,960 new cases of bladder cancer
- 16,390 deaths from bladder cancer
- 4th most common cancer in men
- 1/26 men's overall chance to develop bladder cancer

Cancer stages

Tis
Non invasive flat carcinoma.
Treatment: TURBT + intravesical therapy.

Ta
Non invasive papillary carcinoma
Treatment: TURBT + intravesical therapy

T1
the tumor has spread in the connective tissue
Treatment: TURBT + partial or radical cystectomy.



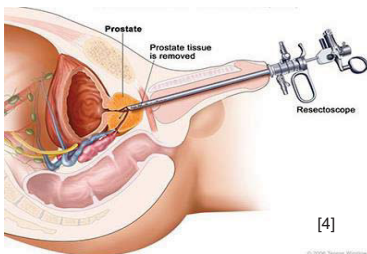
T2
the cancer has spread into the muscle layer
Treatment: radical cystectomy + chemotherapy

T3
the tumor has grown in the fatty tissue
Treatment: cystectomy and chemotherapy

T4
cancerous cells have spread outside the bladder, into nearby organs or structures.
Treatment: chemotherapy + other treatments

TURBT

Transurethral resection of bladder tumor



[4]



[5]

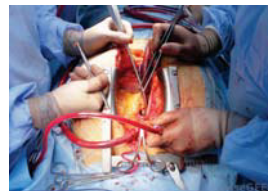Handle: rotatable handling

Optic: PDD and Narrow-band imaging

Improvement Ideas

Radical Cystectomy

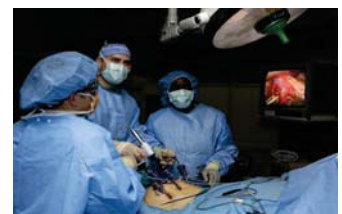Open Radical Cystectomy



[6]

- ✓ Gold standard for radical cystectomy
- ✓ Mortality < 4% in the biggest studies
- ✗ Large umbilical incision

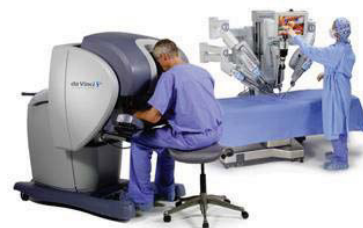Laparoscopic Radical Cystectomy



[7]

- ✓ Reduced scars
- ✓ Shorter hospital stay
- ✗ Steep learning curve

Robotic- Assisted radical cystectomy



- ✓ 3D vision
- ✓ Surgeon's comfortable and remote position
- ✓ Instrument's higher fluidity

- ✗ Costs
- ✗ Bulky instrument

Past

Present

Future

[8]

References

- [1] : <http://www.cancer.org/cancer/bladdercancer/detailedguide/bladder-cancer-key-statistics>.
 [2]: <http://www.healthline.com/health-slideshow/overactive-bladder-men>
 [3]: <http://diseasesdoctor.com/bladder-cancer-symptoms-causes-signs-treatment/>
 [4]: <https://www.linkedin.com/pulse/transurethral-resection-bladder-tumor-turbt-kapil-c>
 [5]: <http://www.medicalexpo.com/prod/richard-wolf/product-78958-490048.html>
 [6]: <http://chiropracticadvocate.com/subluxation-and-heart-disease-learn-the-truth-tell-the-truth/surgeons-performing-open-surgery/>
 [7] : https://en.wikipedia.org/wiki/Laparoscopic_surgery#/media/File:Laparoscopic_stomach_surgery.jpg
 [8]: http://my.clevelandclinic.org/ccf/media/Images/OB_GYN/da_vinci_1.jpg?la=en

Bladder tumor treatment with IGP

how could we improve this?

Ferrari Marco

Medical Systems Engineering

Abstract— Bladder cancer is a type of cancer that develops in the bladder. This article aims to give an overview of the cancer and the treatments available, especially the ones guided by imaging. The paper also proposes improvement ideas and gives an insight of what the future holds for these treatments.

Index Terms— minimal invasive surgery, cystectomy, laparoscopy, robotic assisted surgery.

I. INTRODUCTION

This year, in the US alone, an estimated 76,960 adults (58,950 men and 18,010 women) will be diagnosed with bladder cancer. Among men bladder cancer is the fourth most common cancer in the US and fifth in Europe [1]. Bladder cancer can be tackled using different methods. This paper will give an initial introduction to the bladder cancer in general and then will explain the image guided surgical procedures available, outlining advantages and problems.

II. BLADDER TUMOR

The bladder is a hollow organ in the pelvis with flexible and muscular walls. Its main function is to store urine before it leaves the body. Urine is produced in the kidneys and is carried to the bladder through tubes called ureters. When you urinate, the bladder contracts, and urine is forced out through a tube called urethra. As the image shows the bladder is composed by different layers. Most bladder cancers start in the innermost lining of the bladder. This layer is called transitional epithelium. If a cancer is only developed in this layer, it is then called “non invasive”. This type of cancer is

the most common and is usually referred to as urothelial carcinoma.

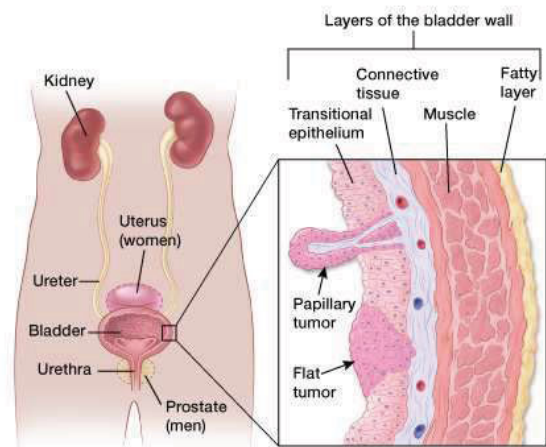


Fig. 1 – Urothelial Carcinoma [2]

However, cancer will tend to expand to the innermost layers and will therefore become harder to treat. This type of cancer is called “invasive”. As the cancer keeps growing, it will grow outside of the bladder and will eventually affect the nearby structures, especially lymph nodes, bones, lungs or liver. Lymph nodes are bean sized collections of immune system cells [2].

III. CANCER STAGES AND TREATMENTS

The stage of a cancer describes how far it has spread. It is a crucial factor when considering the most appropriate treatment. A staging system is a standard way doctors use to

describe how far the cancer has spread. One of the used systems is the **TNM**. According to this system, each letter (T, N and M) have an associated number which describes the condition of that specific parameter. **T** describes how far the cancer has spread. **N** indicates any spread of the patient into nearby lymph nodes. **M** indicates whether the tumor had metastasized in distant sites such as organs or lymph nodes.

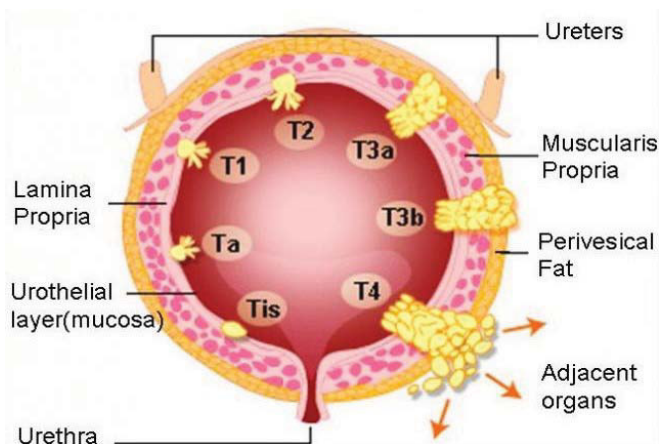


Fig. 2 – Cancer Stages [healthncare.info]

The T value describes the following conditions:

- **Tis**: Non invasive flat carcinoma. Cancer is in the innermost layer of the bladder lining. It tends to grow towards the inside of the bladder.

Treatment: Transurethral resection of bladder tumor (TURBT) and intravesical therapy. TURBT is a surgical procedure during which cancerous cells are resected from the inner layer of the bladder. It will be further explained in the following paragraph. Intravesical therapy consists in injecting liquid drug into the patient's bladder through a catheter. The drug will affect the innermost lining without having major effects on other organs [3].

- **Ta**: Non invasive papillary carcinoma. Cancer is in the innermost layer of the bladder lining however, in this case, the cancer tends to grow towards the outside.

Treatment: TURBT and intravesical therapy.

- **T1**: the tumor has spread in the connective tissue below the inner lining but it hasn't grown into the muscle layer.

Treatment: TURBT is initially performed to determine the extent of the cancer. If the cancer is low grade, then intravesical therapy will follow. If the cancer is high grade, a radical or partial cystectomy may be performed. Radical cystectomy is a surgical procedure during which the entire bladder, along with nearby lymph nodes, is removed. It will be further explained later on [3].

- **T2**: the cancer has spread into the muscle layer.

Treatment: radical cystectomy is the standard therapy. Chemotherapy is often given in order to prevent cancer from coming back. Chemotherapy is the use of drugs, in the form of pills or directly injected into the blood stream, to kill cancerous cells [3].

- **T3**: the tumor has grown in the fatty tissue surrounding that covers the external part of the bladder. T3a is a tumor that can be seen in the fatty tissue only through a microscope, while T3b cancer can be seen using the imaging tests or can be felt by the surgeon.

Treatment: cystectomy and chemotherapy are the standard treatments [3].

- **T4**: cancerous cells have spread outside the bladder, into nearby organs or structures.

Treatment: chemotherapy is the first usually treatment. Cystectomy or radiation therapy may follow [3].

I will now focus on the image guided therapies: TURBT, open radical cystectomy, laparoscopic radical cystectomy and robotic assisted radical cystectomy.

IV. TRANSURETHRAL RESECTION OF BLADDER TUMOR

TUMOR

The transurethral resection of bladder tumor (TURBT) is a procedure in which bladder tumor can be removed from the bladder wall. A first TURBT has three main goals:

- To obtain pathological material to understand which kind of tumor the patient has.
- To understand the extent of the tumor.
- To remove all the visible cancer.

During this procedure, the patient can be under general anesthesia or regional anesthesia. The surgeon inserts a resectoscope into the bladder through the urethra. The procedure doesn't require to cut the skin of the patient and therefore it's considered minimally invasive. For this reason it is typically performed as a day procedure. The surgeon is able to look into the bladder by looking through the scope of the resectoscope. The instrument injects sterile liquid in order to expand the bladder. The best resection is performed when the bladder is half full [4]. The resectoscope has a wire loop at the end that it's used to remove any abnormal tissue. After the removal of the tissue, some tissue at the base of the tumor is taken in order to perform a biopsy and ensure the complete removal of the cancer. However, the resectoscope is not effective for carcinoma in situ [4]. The picture refers to the transurethral resection of the prostate, which is performed in a similar manner. The second picture shows what the surgeon sees during this procedure.

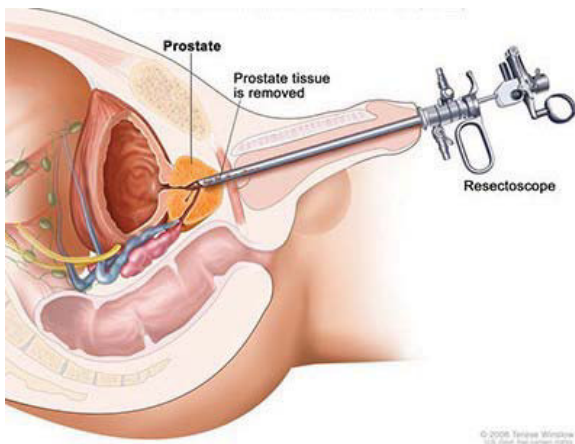


Fig. 3 – Transurethral resection [linkedin.com]

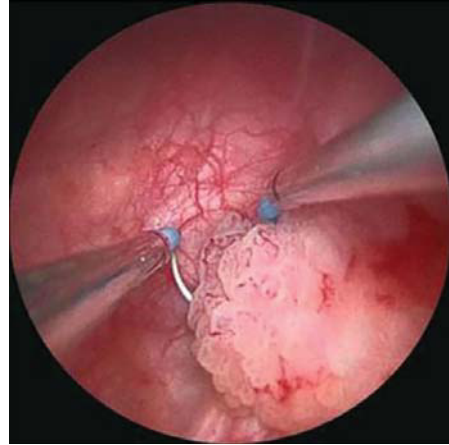


Fig. 4 - Resectoscopic view [youtube.com]

A. Problems faced during TURBT

The risks include:

- Bleeding [5]
- Infection [5]
- Bladder perforation [5]
- Ineffectiveness against non-visible lesions [6]
- Incomplete resection [6]

Bleeding is the most common risk because bladder has a rich blood supply. This is particularly good at the end of the procedure because it facilitates the recovery, however during the procedure the bleeding might disrupt the surgeon's operation. Infections will occasionally occur and patients are given antibiotics after the procedure to minimize the risk. Bladder perforation occurs in roughly 1% of the patients and is caused by the necessity to cut deeply inside the bladder wall [5]. Small holes heal by themselves and quickly. Unfortunately big holes require another surgery to be closed. The other three problems are responsible for the high recurrence rates of bladder tumor [6]. Some of these problems could be minimized by improving the instrumentation used in the surgery.

B. Resectoscope & its components



Fig. 5 – Resectoscope by Olympus [olympus-europa.com]



Fig. 6 – Resectoscope tip [medicalexpo.com]

The main instrument used in this procedure is the resectoscope. It is composed mainly by these parts:

- **Optic:** allows the surgeon to look inside the bladder of the patient. The lens can have different angles and the optic can be rotated in order to obtain a complete visualization of the inner lining of the bladder.
- **Working element:** it is used by the surgeon to control the wire loop that removes the tumor. It can be active or passive. A active working element results in a forward movement of the wire loop if the handles are pushed away from each other. A passive working element works the opposite way.
- **Sheath:** covers the working element and houses the tubes through which the irrigating solution is injected or withdrawn. The working element can be freely rotated inside the sheath or can be blocked if the surgeon needs it.
- **Wire loop:** it's element used to remove the cancerous cells and coagulate blood. It can have different shapes depending on the procedures that is performed using the

resectoscope. During TURBT for bladder cancer, a cutting loop as shown in the picture is most commonly used. The wire loop can be monopolar or bipolar. Monopolar wire loop is a loop that acts as one end of a dipole. The monopolar loop needs another patch to have a current flow. The sterile liquid needed for expanding the bladder must be hypotonic non-electrolyte. However, this kind of liquid is also linked with potentially fatal conditions such as hyponatremia, hypokalemia, hypocalcemia, and hypoosmolality [7,8]. The first bipolar resectoscope was introduced in 2008 to overcome these problems [8]. A bipolar wire loop generates a current between the two electrodes of the resectoscope, therefore the current flow is restricted to the end of the working element, under the visual control of the surgeon. The bipolar wire loop also offers the advantage of not having a neutral electrode on the patient's skin, so the risk of thermal injuries to distant tissues or organs is reduced [7]. Nowadays many medical companies offer bipolar loop resectoscopes.

C. Improvement Potential

1) Optic

The improvement in the optic field are the most promising. Photodynamic Diagnosis (PDD) is a technology that is evolving since the 1960s, but it is not widely available on the market [9]. According to this method, a photosensitive marker is injected inside the bladder and it's absorbed by the healthy cells but not by the tumor. If struck with fluorescent light, the tumor appears more clearly because of a difference in color compared to other tissue. This procedure allows the surgeon to clearly visualize the cancerous cells and perform a more precise resection and may avoid or lessens problems such as: ineffectiveness against non visible lesions and incomplete resection and therefore decrease the tumor's recurrence [10]. Despite the advantages, PDD is only available only for Olympus resectoscopes [11].

Narrow band imaging is also a promising imaging technology that was launched the first time in 2005 [12]. It uses two

bandwidths, 415 and 540 nm, which are preferably absorbed by hemoglobin in hypervascular neoplastic tissue. Despite the evidence that this system could prove itself useful to improve the detection of cancerous cells [13], still no company, according to my research, has provided the market with a resectoscope able to use Narrow band imaging technology.

2) Handle

The resectoscope is used by the surgeon with one hand. The other and is used to press the body of the patient to allow the rigid resectoscope to reach places where otherwise the resectoscope couldn't reach [5]. Sometimes however, the resectoscope design forces the surgeon to hold uncomfortable positions. A handling piece that allows the surgeon to rotate the loop without rotating his hand around the instrument would be ideal to improve surgeon's comfort. At the same time however, this new design might not deliver the same reliability current resectoscopes do.

V. CYSTECTOMY

When the tumor is invasive, all or part of the bladder has to be removed. It can be done through two different surgeries: partial cystectomy or radical cystectomy.

Partial cystectomy is surgical procedure during which part of the bladder is removed. The nearby lymph nodes are also removed and examined in order to determine if cancer has spread outside the bladder.

VI. RADICAL CYSTECTOMY

Radical cystectomy is a procedure during which the whole bladder and the nearby lymph nodes are removed. In men, prostate and seminal vesicles are also removed. In women, the ovaries, fallopian tubes (tubes that connect the ovaries and uterus), the uterus (womb), cervix, and a small portion of the vagina are often removed along with the bladder [2].

Radical cystectomy can be performed through three different kinds of procedure:

- Open surgery
- Laparoscopic surgery
- Robot assisted laparoscopic surgery

At the end of radical cystectomy, the patient will require another way to store and remove urine. Incontinent diversion, continent diversion and neobladder are three possible solutions.

VII. OPEN SURGERY

This procedure has been performed since the 1950s and it is still the gold standard to perform radical cystectomy [14,1]. A large incision as shown in the picture is necessary to allow the surgeon to perform the resection.

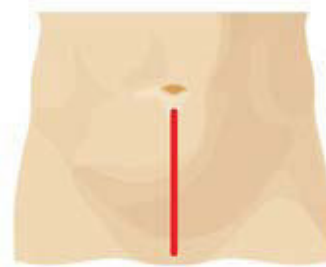


Fig. 7 - Open Surgical incision [davincisurgery.com]

The main parameters to evaluate open surgery are: mortality, morbidity, surgical margin status and number of lymph nodes retrieved. Mortality is lower than 4% in the biggest studies [15,16]. Morbidity and re-exploration rate doesn't exceed respectively 30% [17,15] and 17% [15,17].

New techniques applied by the surgeon aim to obtain the same benefits of a minimal invasive procedure: less need for analgesics, reduction in length of hospitalization, early recovery, and better cosmesis [14]. However, the large umbilical incision will never be avoided and intraoperative blood loss is a frequent event even when performed by experienced surgeons [1]. The instruments used for this kind of surgery are used for many other procedures: retractors, scissors, clamps etc. The instruments for open surgery will not be analyzed.

VIII. LAPAROSCOPIC SURGERY

Laparoscopic radical cystectomy (LRC) uses long and thin instruments that are inserted into the pelvis of the patient and therefore require only small incisions (generally 5 to 6 ports

are required [18]). The surgeon controls by hand these instruments and views the inside of the pelvis of the patient by using a video camera which is inserted inside the patient as well. Total surgery time depends by the type of chosen reconstruction method but in previous studies it ranges from 180 min to 12 hrs [18].

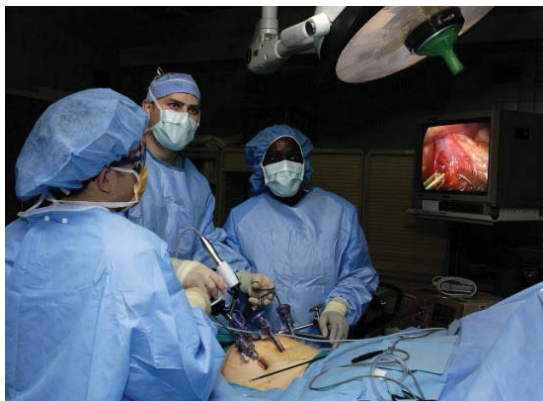

Fig. 8 - Laparoscopic Surgery [wikipedia.org]

Laparoscopic surgery has been performed since the 1990s [19]. At first, laparoscopy was used but the ileal conduit for urinary diversion was performed extra corporeally. The first complete intracorporeal ileal conduit diversion surgery took place in 2000 and two years later a purely laparoscopic orthotopic neobladder reconstruction surgery was performed [20].

A radical cystectomy that is performed without the need of the large surgical umbilical incision is called laparoscopic, however there are some variations regarding the methods applied during the surgery. For this reason, laparoscopic surgery can be divided in:

- purely laparoscopic : the urinary diversion construction is performed inside the patient.
- laparoscopic assisted : extracorporeal reconstruction of the urinary bladder.

Even though great progresses have been made with this kind of procedure, laparoscopic surgery is still not the best procedure for some patients. Presence of bulky lymphadenopathy, locally advanced disease, uncorrected coagulopathy and morbid obesity are contraindications for

LRC [19]. Also, the amount of publications referring to the follow up data is lacking or not sufficiently long [18,1].

A. The advantages of Laparoscopy

- Reduced hemorrhaging [21,1]
- Lower morbidity [18,1]
- Lower mortality [18,1]
- Lower surgical margins [18,1]
- Reduced postoperative pain [21,1]
- Faster recovery time [21,1,17]
- Reduced scars [21,1]
- Shorter hospital stay [18,1]

B. Problems during LRC

According to the scientific literature the problems include :

- Long time required for the procedure [18]
- Steep learning curves [18]
- Low number of researches analyzing follow -up [18]
- Worse comprehension of the surgical field [22]
- Lack of tactile feedback [22]
- 2D information of the 3D surgical field [22]
- Poor ergonomic position of the surgeon [23]
- Limited mobility of straight laparoscopic instruments [23]

C. Instruments used during LRC and improvement potential

In this chapter I describe the most important laparoscopic instruments: laparoscope, grasper and needle driver.

1) Laparoscope

A laparoscope generally looks like the one in the picture.



Fig. 9– Laparoscope [striker.com]

It's an instrument that acquires images of the peritoneal cavity of a patient. These images are viewed real time from the surgeon. This instrument enables the surgeon to operate the patient without having a direct sight into the patient. The two main components of a laparoscope are: image acquisition part and the illumination part [24]. The laparoscope is coupled with a digital camera that sends the images to a camera control unit, and then to a monitor [24]. One of the limitations of the view coming from the laparoscope is its 2D nature. However, recent systems include a laparoscope with 2 cameras at its end [25]. After combining the information from the two cameras, the surgeon is able to have a 3D view. However, the two cameras are very close to each other and the 3D image is still not optimal.

Improvement Potential

The laparoscope can nowadays give a high resolution image. The illumination system is also quite optimal for its purpose. The 3D information could be improved by creating a laparoscope that has the ability to spread once the instrument is inside of the patient. That would create a greater distance between the cameras and therefore a better 3D information.

One of the great problems with laparoscopic surgery is also the steep learning curve. Manipulating the patient with instruments without tactile feedback and without looking directly on the patient can be challenging. I think the greatest impact on the learning curve would be the use of augmented reality. Augmented reality in the surgical procedure means supplying the surgeon with additional information regarding the operating field. Visualization of critical structures that are not visible to direct sight and 3D information of anatomical structures is the aim of augmented reality. As shown by the work of Xin Kang et al [26], augmented reality by means of

laparoscopic ultrasound could be a viable option in the future of augmented reality in laparoscopy. Other intraoperative imaging techniques are being investigated. Preoperative images could also help the visualization of the surgical field, however, the biggest problem faced is the registration of the preoperative and intraoperative image. Augmented reality would decrease the time necessary for the training of a surgeon and ultimately, allow surgeons to perform without the need of good depth perception and, especially, extensive knowledge of internal organs.

2) Grasper



Fig. 10 - Grasper [27]

Laparoscopic graspers are instruments precisely designed to manipulate the delicate abdominal tissue during laparoscopic procedures. They are also used to perform less technical actions, such as moving bowel tissue away to facilitate access to the surgical field. Generally, the grasper is composed of three main components:

- Tip
- Shaft
- Handle

The tip can have different shapes and sizes to account for the different purposes. Bowel tissue is considered to be one of the most delicate tissues of the whole body, therefore, especially for laparoscopic cystectomy, the tip needs to securely grip the tissue, but without applying too much pressure. For this purpose grasper tips with “atraumatic design” are usually used in this kind of operations. This simply mean that the tip is especially design to not cause any trauma (dull end instead of pointed one for example).

The shaft is usually around 5 mm in diameter [28], the shaft is long enough to permit the control the instrument inside the patient from the outside. The shaft houses all the few internal components that allow the surgeon to open or close the tip.

The external part is coated with an electrical insulating layer (polymer) to protect the patient from possible electrical burns. In fact, the grasper can be supplied with electricity to perform electrical surgery.

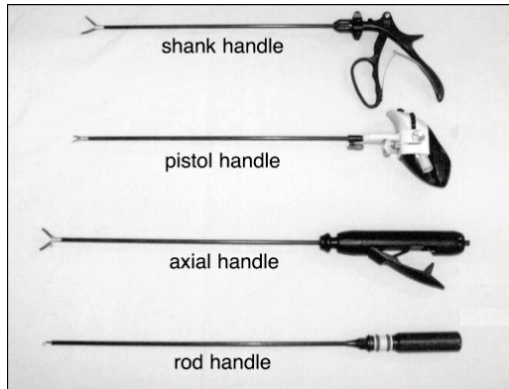


Fig. 11 - Grasper handle designs [openi.nlm.nih.gov]

Normally perpendicular to the shaft, the handle is usually controlled by the hands of the surgeon in a scissor like fashion: one ring loop is controlled by the thumb and the lower loop is controlled by the rest of the hand. However, handles change in design depending on the purpose of the grasper. Reusable grasper will often be modular, allowing the surgeon to use its preferred handle depending on his personal preference.

Improvement Potential

Lack of tactile feedback is the major problem current graspers have. During laparoscopic procedures, a surgeon can control the tip by means of a mechanical arrangement of cables and pulleys. Basically, the feedback is given by the resistance the surgeon encounters whenever he or she closes the tip of the grasper. This problem could be overcome by mounting a sensor at the tip of the grasper that sends an output signal proportional to the force it senses. The output signal of this sensor could be then transferred to the handle piece, where it would be converted to a vibration proportional to the force. The output of the sensor could also generate a vibration at the handle piece only whenever a certain force threshold is reached, warning the surgeon of possible risks for the handles tissue. The vibration could however disturb the surgeon while

performing the operation. Therefore a carefully chosen type and intensity of the vibration needs to be implemented.

Sometimes the surgeon needs to push the tissue or the organs out of the way. Currently the surgeon uses a grasper to achieve this operation, because, most of the time, the surgeon needs to pinch more frequently than any other operations. Substituting the grasper to perform this task wouldn't be ideal. A grasper that is able to turn into a spatula would solve this problem. However, an implementation of this idea would also mean increasing the complexity of the inner mechanism and the size of the grasper, which would be detrimental to the reliability of this instrument.

Another problem which could affect the outcome of the procedure is the uncomfortable positions the surgeon needs to maintain for a prolonged period of time. Especially considering that procedures can last up to 12 hours [18]. During a laparoscopic procedure, the physician not only has to carefully manage the tip of the grasper, but he also needs to maintain the grasper in a certain position. A system able to hold the laparoscopic instruments in position whenever the surgeon needs to let the instruments go, I think might be beneficial for the surgeon.

3) Needle Driver



Fig. 12 - Needle Driver [27]

The needle driver is the instrument used to control a needle inside the body to accomplish free hand surgery. The needle driver used in laparoscopic surgery is different compared to its open surgery counterpart, as it must be suitable for use inside the patient. Design doesn't change among laparoscopic needle drivers and generally it is composed of three main parts:

- Tip
- Shaft
- Handle

The needle jaw can have four configurations: straight (in line with the shaft), curved left(45°), curved right and self-righting[26]. Self righting needle is especially designed to force the needle to stay in a certain position, independently from the orientation the needle was pinched. More recently articulating tips have entered the market. They allow a greater maneuverability, however surgeon needs more time to be proficient in its handling.

The needle jaw must deliver a firm grip on the needle but at the same time don't deform the body of it. It is generally composed of tungsten carbide, but additional coating can be applied to improve grip [27].

The shaft is long and narrow and it is composed of surgical steel on the inside and a non conductive polymer on the outside. Length can vary, however 30 to 35 cm is considered the standard [27].

Unlike other laparoscopic instruments, the handle of a needle driver has a straight axial design, providing a more natural handling of the instrument [27]. Since the surgeon must open and close the tip many times, the handle is spring loaded: the grip is opened when squeezing and closed when at rest. A ratcheted mechanism in the handle allows the locking of the tip. This way the surgeon only needs to concentrate on the movement of the needle and not on the force applied at the tip of the instrument. An easy release mechanism is also very important as the tip must be continuously opened and closed.

Improvement Potential

The current needle drivers are carefully engineered to be reliable during the surgical procedure and I think no further research could improve it. The handling of the instrument however, is still not optimal. This could be detrimental to the learning curve of young surgeons, extend the operation time and make surgery more prone to errors. For these reasons, a more intuitive control of the laparoscopic instruments such as the one provided by the "DaVinci" system is, I think, the future of minimally invasive procedures. The major drawback that limits the expansion of this system is its price [29], but I will further explain robotic assisted surgery in a following chapter.

IX. Robotic Assisted Laparoscopic Surgery

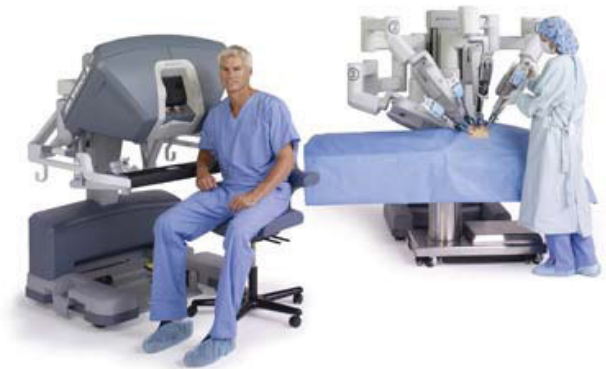

Fig. 13 - DaVinci Surgical System [intuitivesurgical.com]

Robotic assisted laparoscopic surgery (RALS) was developed at the end of the past century from the need to overcome the problems with conventional laparoscopic procedures. The only company that produces the robot needed to perform this kind of procedure, Intuitive Surgical, has received the approval from the Food and Drug Administration for its use in surgical procedures in 2000 [29]. This procedure involves the use of a robot especially engineered to perform cardiac surgery, which then evolved to perform also laparoscopic surgery. The robot is remotely controlled by the surgeon, that sits in a comfortable position. The robot is composed by multiple arms which are introduced into the patient's abdominal region. Each arm performs different tasks like during a laparoscopic surgery. However, the instruments are not directly controlled by the surgeon. The surgeon is seated away from the patient and, using his/her hands, controls the instruments in a much more natural way [29].

Despite its advantages, this technology is not spreading as fast as early reviews of this system have predicted [30]. Lack of clinical evidence proving the benefits of RALS and poor returns for hospitals that invested on this system, contributed also to the slow spread of this technique [31]. In the next paragraph I summarized advantages and drawbacks with respect to standard laparoscopic surgery.

A. RALS Advantages

- 3D vision of the surgical field [23]
- Higher fluidity of instrument's movement [23]
- Stable camera platform [23]

- Lower the time in the hospital [32]
- Surgeon's comfortable position [23]

B. RALS Problem

- Costs [29]
- Assembly time [23]
- Dimensions and weight of the system [23]
- Lack of tensile feedback [23]
- Large diameter of the instruments [23]
- Lack of data regarding the benefits [29]
- Long operative times [33]

X. FUTURE DEVELOPMENT

The DaVinci system entered the market 16 years ago and, up to this day, no other company has provided the medical market with a similar system. This lack of competition has been detrimental for the growth of this technology in many aspects: cost, technological progress and therefore the spread of this method. However, many Intuitive Surgical's early patents were filed 20 years ago [34], and therefore many other companies are expected to enter the market with new set ups. Google and Johnson&Johnson recently created "Verb Surgical" with the aim to create a robotic system that could be used in surgical procedures. Transenterix is another company that promises to challenge Intuitive Surgical with a robot similar to the DaVinci system.

Overall robotic systems are expected to grow and represents, in my opinion, the future of many surgical operations, especially in the laparoscopic field. The well established current laparoscopic procedure don't represent the future of laparoscopic surgery, however the robotic systems will take time to become the standard method, also because of its high costs. Therefore, I think, traditional laparoscopic technology will keep improving to satisfy the needs of clinics that don't have the necessary economical resources to fully embrace RALS.

XI. REFERENCES

- [1] Li H, Xia D, Hu Z, Zhuang Q, et al. Tang K, "Laparoscopic versus Open Radical Cystectomy in Bladder Cancer: A Systematic Review and Meta-Analysis of Comparative Studies.," *PLoS ONE*, 2014.
- [2] American Cancer Society. [Online]. <http://www.cancer.org/index>
- [3] American Cancer Society. (2016) Treatment of bladder cancer, by stage. [Online]. <http://www.cancer.org/cancer/bladdercancer/detailedguide/bladder-cancer-treating-by-stage>
- [4] Mark Schoenberg, Cora Sternberg Seth P. Lerner, *Textbook of bladder cancer.*: Taylor & Francis, 2006.
- [5] [Online]. <http://www.urologybook.com/transurethral-resection-of-bladder-tumor-turbt/>
- [6] Brett Carswell Pamela Ellsworth, *100 Questions & Answers About Bladder Cancer.*
- [7] Karl Storz. [Online]. https://www.karlstorz.com/cps/rde/xbcr/karlstorz_assets/ASSETS/2148670.pdf
- [8] Greenberg James, "21 Fr./7-mm PRINCESSTM Resectoscope. Review," *Obstetrics and Gynecology*, 2010.
- [9] Herbert Stepp, Raphaela Waidelich Dieter Jocham, "Photodynamic Diagnosis in Urology: State-of-the-Art," *European Association of Urology*, 2007.
- [10] Martin Sommerauer, Francesco Montorsib, Arnulf Stenzl, Didier Jacqmind, Patrice Jichlinski, Dieter Jochama, Andreas Ziegler, Reinhard Vontheinf Ingo Kauscha, "Photodynamic Diagnosis in Non-Muscle-Invasive Bladder Cancer: A Systematic Review and Cumulative Analysis of Prospective Studies," *European Association of Urology*, 2009.
- [11] Olympus Europe. OES Pro Resectoscope with PDD. [Online]. https://www.olympus-europa.com/medical/en/medical_systems/products_services/product_details/product_details_10307.jsp
- [12] Kazuhiro Gono, "Narrow Band Imaging: Technology Basis and Research and Development History," *Clinical Endoscopy*, 2015.
- [13] Carlo Introini, Franco Bertolotto, Bruno Spina and Paolo Puppo Angelo Naselli, "Narrow band imaging for detecting residual/recurrent cancerous tissue during second transurethral resection of newly diagnosed non-muscle-invasive high-grade bladder cancer," *BJU International*, 2009.
- [14] Anand Dharaskar, Rakesh Kapoor Anil Mandhani, "Technical steps of open radical cystectomy and orthotopic neobladder to achieve the goals of "minimally invasive surgery"?", *Indian Journal of Urology*, 2010.
- [15] Stein JP et al., "Radical cystectomy in the treatment of invasive bladder cancer: long-term results in 1,054 patients.," *J Clin Oncol*, 2001.

- [16] Lundbeck F., Overgaard J. Knap M., "Early and late treatment-related morbidity following radical cystectomy," 2004.
- [17] Novotny V et al., "Perioperative complications of radical cystectomy in a contemporary series," *European Urology*, 2007.
- [18] Paolo Puppo, Carlo Introini, and Angelo Naselli, "Surgery Insight: Advantages and Disadvantages of Laparoscopic Radical Cystectomy to Treat Invasive Bladder Cancer," *Nature Clinical Practice Urology*, 2007.
- [19] Sebastien Crouzet, Inderbir S. Gill Georges-Pascal Haber, "Laparoscopic and Robotic Assisted Radical Cystectomy for Bladder Cancer: A Critical Analysis," *European Association of Urology*, 2008.
- [20] Kaouk JH, Meraney AM, Desai MM, Ulchaker JC, Klein EA, Savage SJ, Sung GT. Gill IS, "Laparoscopic Radical Cystectomy and Continent Orthotopic Ileal Neobladder Performed Completely Intracorporeally: The Initial Experience," *The Journal of Urology*, 2002.
- [21] Carlos Arroyo, Francois Rozet, Eric Barret, Guy Vallancien Xavier Cathelineau, "Laparoscopic Assisted Radical Cystectomy: the Montsouris experience after 84 cases," *European Urology*, 2005.
- [22] Mahdi Azizian, Emmanuel Wilson, Kyle Wu, Aaron D Martin, Timothy D Kane, Craig A Peters, Kevin Cleary, Raj Shekhar Xin Kang, "Stereoscopic augmented reality for laparoscopic surgery," *Surgical Endoscopy*, 2014.
- [23] Esposito C, Cuccurullo D, Settembre A, Miranda N, Amato F, Pirozzi F, Caiazza P Corcione F, "Advantages and limits of robot-assisted laparoscopic surgery: preliminary experience," *Surgical Endoscopy*, 2005.
- [24] Olympus Europe. [Online]. https://www.olympus-europa.com/s/4k/en/index.php?olycmp=4Ksta&icid=GE_T_CLOSER_-_Four_Times_the_Resolution_of_Full_HDLearn_more_-_%28sta1-slides%29#Products
- [25] Olympus Europe. [Online]. https://www.olympus-europa.com/medical/en/medical_systems/products_services/rigid_endoscopy/imaging_systems_1/3d.jsp
- [26] Sukryool Kang, William Plishker, George Zaki, Timothy D. Kane, Raj Shekhar Xinyang Liu, "Laparoscopic stereoscopic augmented reality: toward a clinically viable electromagnetic tracking solution," *Surgical Endoscopy*, 2014.
- [27] [Online]. <http://www.laparoscopic.md/instruments/needle-driver>
- [28] [Online]. <http://www.laparoscopic.md/instruments/grasper>
- [29] [Online]. <https://www.technologyreview.com/s/418141/the-slow-rise-of-the-robot-surgeon/>
- [30] Esposito C., Cuccurullo D., Settembre A., Miranda N., Amato F., Pirozzi F, Caiazza P. Corcione F, "Advantages and limits of robot-assisted laparoscopic surgery: preliminary experience.," *Surgical Endoscopy*, 2005.
- [31] BARNABY J. FEDER, "Prepping Robots to Perform Surgery," *The New York Times*, 2008.
- [32] Schwentner et al., "Robot-assisted radical cystectomy and intracorporeal neobladder formation: on the way to a standardized procedure," *World Journal of Surgical Oncology*, 2015.
- [33] Tara Kirkpatrick and Chad LaGrange. (2016, February) Robotic Surgery: Risks vs. Rewards. [Online]. <https://psnet.ahrq.gov/webmm/case/368/robotic-surgery-risks-vs-rewards-#references>
- [34] [Online]. <http://www.mddionline.com/blog/devicetalk/could-patent-expirations-be-chink-intuitive-surgical%E2%80%99s-armor-08-25-16>
- [xx] [1]
- [36] [Online]. <http://www.laparoscopic.md/instruments/grasper>
- [37] C. Esposito, D. Cuccurullo, A. Settembre, N. Miranda , F. Amato, F. Pirozzi, P. Caiazza F. Corcione, "Advantages and limits of robot-assisted laparoscopic surgery: preliminary experience.," *Surgical Endoscopy*, 2004.



MRI Guided Interventions: A Review

Charusree Madhav, Otto-von-Guericke University, Magdeburg, Germany

Introduction

- MRI is emerging as an interventional device in the recent years
 - Interventional MRI can be used either for open surgery or for minimally invasive surgeries
 - Interventional MR imaging is a real time process and demands faster image acquisition, reconstruction and processing unlike diagnostic MRI.
- Advantages of MRI**

 - Good soft tissue contrast
 - Multi planar imaging capability
 - High vascular conspicuity
 - No ionizing radiation
 - Good temporal and spatial resolution
 - Temperature sensitivity

Contraindications of MRI

 - Requirement of MR compatible tools
 - Cannot be used for patients with electronic and dental implants
 - Not suitable for patients with claustrophobia
 - High cost
 - Limited patient access

MR Imaging, MR systems and MRI safety

MR Imaging

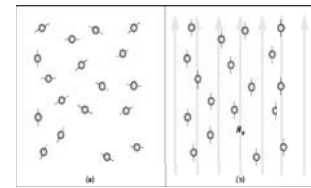
- In the presence of magnetic field, the hydrogen molecules in the body will align themselves in the direction of magnetic field(B₀)
- The frequency of precession of molecules called Larmor frequency is given by $\omega_0 = \gamma B_0$
- Application of additional RF pulse leads to the deflection of net magnetic moment from B₀.
- After the pulse is withdrawn, magnetic moment returns to original state resulting in the emission of MR signal

MR Systems

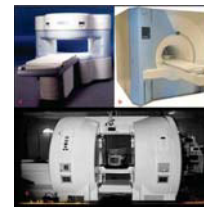- Closed bore
- Open bore
- Double donut configuration

MRI safety

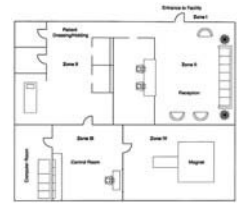- Damages are caused due to 3 types of magnetic field
- Static magnetic field
 - Gradient magnetic field
 - Radiofrequency magnetic field



a) Randomly aligned hydrogen molecules in the absence of magnetic field. b) Molecules aligned in the direction of B₀



Different MR systems. a) Open bore b) Closed bore c) Double Donut configuration



Different zones in MR room according to ACR

Clinical Applications

Prostate Cancer

- MRI guided cryosurgery and MRI guided focused Ultrasound are treatment options for prostate cancer
- MRI compatible robot system is developed for MRI guided needle intervention in prostate

MR Guided Biopsy

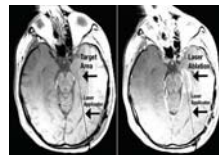
- It is the most frequent clinical application of MRI.
- High soft tissue contrast of MRI helps in unique visualization of both anatomy and physiology

MRI Guided Spine Injections

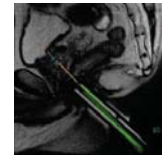
- MR imaging helps in visualizing spinal target and needle placement, monitor the injected drugs and detect spread to nearby structures

Other applications

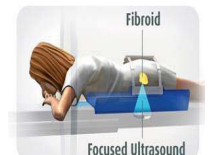- MR arthrography
- MRI guided thermal therapy
- Cardiovascular interventions
- Breast biopsy
- MRI guided focused ultrasound
- Musculoskeletal soft tissue interventions
- Neuroradiology
- Catheter tracking



MRI guided laser ablation



MRI guided biopsy



MRI guided focused ultrasound for uterine fibroid treatment

Conclusion

MRI is turning to be a prime imaging modality in spite of its contraindications. New developments are happening in this field mainly in the development of MRI compatible robots. Limited patient access is one of the major problems for using MRI as an interventional device. This can be improved by either using a machine which has a wider bore or by designing a new patient table which provides better access.

References

[1] Blanco Sequeiros, R. Ojala, J. Kariniemi, et al. (2005) "MR-Guided Interventional Procedures: A Review". *Acta Radiologica* 46.6, 576-586.
 [2] Jan Fritz, Roberto Blanco Sequeiros, and John A. Carrino. (2011) "Magnetic Resonance Imaging-Guided Spine Injections". *Topics in Magnetic Resonance Imaging* 22.4: 143-151.
 [3] Arjo J Loeve, Jumana Al-Issawi, Fabiola Fernandez-Gutiérrez et al. (2016) "Workflow And Intervention Times Of MR-Guided Focused Ultrasound – Predicting The Impact Of New Techniques". *Journal of Biomedical Informatics* 60: 38-48.
 [4] Adrienne E Campbell-Washburn, Anthony Z Faranesh, Robert J Lederman, et al. (2015) "Magnetic Resonance Sequences And Rapid Acquisition For MR-Guided Interventions". *Magnetic Resonance Imaging Clinics of North America* 23.4: 669-679.
 [5] Nour, Sherif G. and David K. Monson. (2011) "MRI-Guided Musculoskeletal Soft Tissue Interventions". *Topics in Magnetic Resonance Imaging* 22.4: 197-205.
 [6] Karl D Price, Vivian W. Sin, Charles Mougnot et al. (2016) "Design And Validation Of An MR-Conditional Robot For Transcranial Focused Ultrasound Surgery In Infants". *Medical Physics* 43.9: 4983-4995.

MRI Guided Interventions: A Review

Charusree Madhav
Otto-von-Guericke University
Magdeburg, Germany
charusreem@gmail.com

Abstract— Minimally invasive surgeries under image guidance are becoming popular in the recent years. The development of interventional MRI is a boon to these surgeries. The term interventional MRI covers a broad spectrum of procedures, ranging from biopsies to complex surgeries requiring performance of multiple tasks. The procedures can be done either as open surgery or percutaneous. This paper gives a review about the basic principle of MR imaging, MR safety, MR systems and various clinical applications of MRI.

Key Words—Interventional MRI, MR Imaging, MR safety

I. INTRODUCTION

Magnetic resonance imaging has emerged as a prime imaging modality in the recent years. In the past it was mainly used for diagnostic purposes. Now the use of MRI has shifted greatly from rather than a diagnostic device to an interventional device. Interventional MRI (IMRI) is used for diagnostic as well as for therapeutic purposes. Interventional MRI can enhance the scope and potential of minimally invasive therapies, interventional radiology and surgery [1]. Interventional MRI comprises all the procedures that are done under the guidance of MRI, whether it is an open surgery or a minimally invasive surgery. The introduction of IMRI has led to the development of new scanners, faster imaging sequences and software, and development of new tools that can be used in MR environment [1].

Image guided surgeries are gaining popularity in the recent days. The various imaging modalities used are MRI, Fluoroscopy, Computed Tomography (CT), Ultrasound, Positron Emission Tomography (PET) or a combination of these modalities. Image guidance is the key concept in modern and future surgery and it leads to better control and hence better treatment results. Better patient compliance and lower costs are another advantage since these procedures are mainly minimally invasive.

The use of MRI for interventional procedures can be attributed to the introduction of high field and wide bore MR systems [2]. High field MRI provides more signal compared to low field open systems. The radio frequency pulses, static magnetic field and gradient magnetic field characterize MR interventions [2]. MRI is a valuable imaging modality for intervention planning, target definition and closed loop control of acoustic energy deposition [3]. Interventional MRI is used for real-time dynamic procedural guidance and intra-procedural imaging during therapeutic or diagnostic procedures such as tissue biopsy, surgery, endovascular procedures, ablation therapy and device placement.

Interventional MR imaging is a real time process. Unlike diagnostic MR imaging which takes long scan time and offline image reconstruction and processing, interventional MR imaging demands much faster image acquisition, reconstruction and processing. It also requires interactive parameter control and simultaneous visualization of tissue and interventional devices [4].

Advantages of MRI

MRI has many advantages compared to other imaging modalities that are used for intervention. One of the most important aspects for image guided intervention is good soft tissue contrast and thus the ability to distinguish between different tissue types. Although CT provides good soft tissue contrast compared to X-Ray, MRI has better contrast among all [1]. This feature of MRI is further enhanced by the multi planar imaging capability and the high vascular conspicuity inherent to MRI. This high diagnostic performance of MRI renders it the suitable tool to guide certain diagnostic and therapeutic interventions [5]. MRI uses magnetic field for imaging and thus it is free from ionizing radiation. So interventional MRI complies with ALARA (as low as reasonable achievable) principle which indicates to keep the ionizing radiation to the patient and staff as low as possible and thus it can be used for small children and pregnant women. MRI also provides good temporal and spatial resolution. With or without the help of contrast medium, high intrinsic contrast can be achieved in tissue. Another advantage of using MRI is the temperature sensitivity which helps in evaluating temperature changes in tissue [1].

Contraindications of MRI

The contraindications of MRI are mainly due to the presence of magnetic field. While designing a device for use in MR environment, special considerations should be taken into account. Common material such as steel is incompatible for use in magnetic environment. Other non-ferromagnetic materials although they are MR compatible, can cause imaging artifacts. As a result of these, standard operating room equipment and surgical instruments cannot be used in MR room [6]. The instruments used should be MR compatible as well as MR safe. Other than these, patients with any metallic implants or pacemaker cannot enter the MR room due to the presence of magnetic field. MRI is also not suitable for patients with claustrophobia. Yet another disadvantage associated with MRI is its high cost. One major reason which constraints the use MRI for interventional procedures is the

limited patient access. Doctors have much difficulty in operating patients within this limited space

II. MR IMAGING

Magnetic Resonance Imaging uses the magnetic properties of body to produce an image. This is possible because of the abundant presence of water in the body. Water is composed of two molecules of hydrogen and one molecule of oxygen. The change in alignment of hydrogen is used for the imaging. The hydrogen nucleus spins on its own axis like earth. Usually they spin within the body randomly. Once it is placed in an external magnetic field, it will align itself in the direction of magnetic field and precess about the magnetic field with a frequency proportional to the magnetic field strength (Fig 1). This behavior is known as Larmor precession. Larmor frequency is given by the equation:

$$\omega_o = \gamma B_o \quad (1)$$

γ is the gyromagnetic ratio which is 42.6MHz/T for hydrogen and B_o is the magnetic field.

When additional energy in the form of radio frequency pulse which is perpendicular to the magnetic field is applied, the net magnetic moment will deflect from B_o . When this pulse is withdrawn, the magnetic moment will return to its original state which causes emission of a signal. The signal thus emitted is used to create MR images. Different tissues relax at different rate when RF pulse is switched off. This is measured in two ways. The time taken for the magnetic vector to return to its resting state is called T1 relaxation and the time needed for the axial spin to return to its resting state is called T2 relaxation [7].

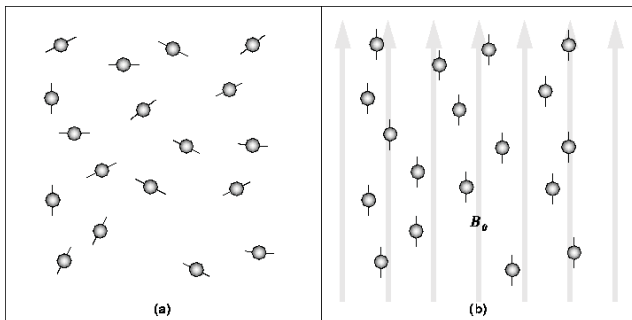


Fig 1: a) Randomly aligned hydrogen molecules in the absence of magnetic field. b) Molecules aligned in the direction of B_o

III. MR SYSTEMS

MR systems are classified into open and closed bore systems. Closed bore systems generate the magnetic field by passing current through a solenoid kept at superconducting temperatures (Fig 2b). In open bore systems, there is an air gap between two magnetic poles (Fig 2a). They use permanent magnets or electromagnets for magnetization. In closed bore systems, the coils are kept in liquid helium to create a homogeneous field of 1T or higher. The open bore systems generally operate in field strengths ranging from 0.2T to 0.7T.

So typically closed bore systems are high field MRI and open bore systems are low field MRI.

Imaging with high field MRI provides better image quality and faster imaging. It also allows functional imaging, spectroscopy and thermal monitoring. Restricted patient access is a problem with these kinds of systems. In low field MRI, it provides better access with the patient. So these types of systems are better suited for interventions than closed ones. The image quality in low field systems is low, but it is quite sufficient for interventional use [1].

Another model which provides access to patient is double donut configuration. It is designed by Signa SP system (General Electric Medical Systems, Milwaukee, Wis) for interventional applications (Fig 2c). This design allows access of the patient from the sides and top at the isocenter of the imaging system. The improvement in access to the patient is achieved by decreasing field strength at the isocenter as compared to the field generated by each individual superconducting half, and compromises magnetic field homogeneity [8].

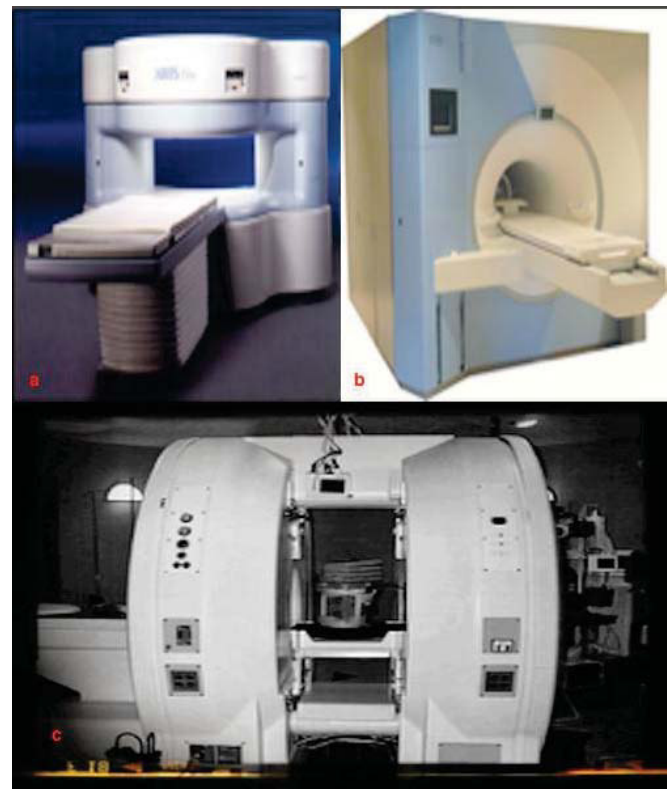

Fig 2: Different MR systems. a) Open bore b) Closed bore c) Double Donut configuration

IV. MRI SAFETY

The use of MRI scanner for interventional purposes possesses challenges in ensuring safety to both patient and staff. The hazards caused by MRI include damage caused by ferromagnetic particles, radiofrequency heating of equipment, electromagnetic interference between the scanner and other electronic equipment, and acoustic noise levels which can affect the communication between staffs or damage their

hearing ability. These have to be taken care of by not compromising the effectiveness of interventional procedure [9].

Three types of magnetic field are present in the MRI room and damages are caused by them [10]

1. The static magnetic field
2. Gradient magnetic field
3. Radiofrequency magnetic field

Effect of Static Magnetic Field

The two main effect caused by static magnetic field is attraction of ferromagnetic material and biological changes. Devices such as surgical implants made of ferromagnetic materials will be attracted towards the magnet and cause damages. Other devices such as pacemaker can completely stop working in the magnetic field. So care should be taken so that no ferromagnetic materials and patient with any implants are brought inside the MRI room. It is reported that in organs such as retina, pineal gland, and some cells in paranasal sinuses may be affected due to static magnetic field [10].

Effects of Gradient Magnetic Field

The main damage caused by these is biological changes and acoustic noise. Time varying magnetic fields can induce electric currents in the tissues which can affect the normal function of nerve cells and muscle fibers. The noise produced by gradient coils can affect the communication between the staff and may damage their hearing if precautions are not taken.

Effect of RF Field

Radiofrequency pulses can interact with tissues and foreign bodies and cause heating in the human body.

According to American College of Radiology (ACR), in order to take precautions against these damages and to maintain safety, the MRI room is divided into four zones: [11] (Fig 3)

Zone 1: These are the areas that can be accessed by the public. This is located outside the MR environment.

Zone 2: This is the interface between zone 1 and zone 3 and 4. Here although the public are allowed, they are under the supervision of MR personnel.

Zone 3: In this zone, the access is strictly restricted. Here the free access by MR personnel or ferromagnetic material or implants can lead to serious injuries or death.

Zone 4: This is where the MR scanner is located. Zone 4 is included within the zone 3.

Other than these measures, the staff operating the MRI should be given proper training. Also the patients should be

screened completely for ferromagnetic materials or implants before allowing them to enter the MR room.

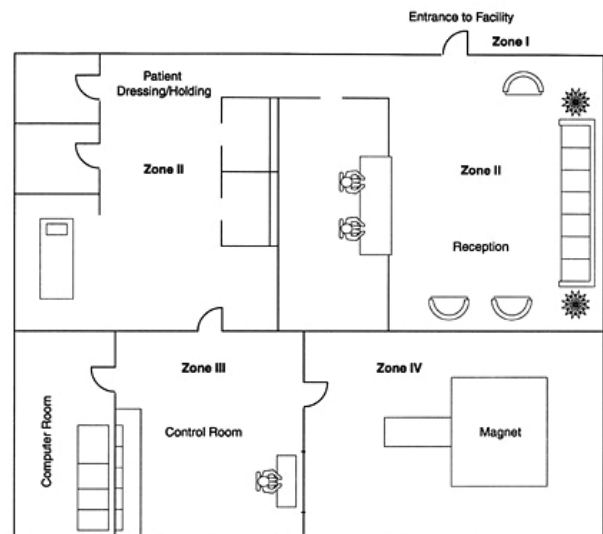


Fig 3: Different zones in MR room according to ACR

V. CLINICAL APPLICATIONS

Prostate Cancer

Prostate cancer is the most frequently diagnosed cancer and second major cause of cancer death in men. Cryosurgery, high intensity focused ultrasound and laser induced thermal therapy is used as treatment options for prostate cancer. All these types of treatments require image guidance. MRI is the most sensitive and specific treatment for prostate cancer compared to ultrasound or CT. MRI guided cryosurgery is technically feasible but contrast enhanced MRI is more suitable to predict tissue damage after cryosurgery [12]. Temperature mapping below 0 degree is not feasible in current MR systems but ice ball formation in cryosurgery is visible in real time in MRI. In laser ablation, the fiber used does not cause any disturbance in electromagnetic field and thus no image artifacts occur. Due to inherent high spatial and temporal resolution, MRI guided laser ablation is a promising technique for prostate cancer treatment. MRI guided focused ultrasound is another technique which is highly promising for prostate cancer treatment [12]. Researchers have developed an MRI compatible robot system for MRI guided needle intervention in the prostate. It was found that the needle targeting accuracy of the system is sufficient for sampling clinically significant prostate cancer [13].

MRI Guided Spine Injections

Spine injections are usually given as treatments for people suffering from low back pain. These are traditionally given under X-ray fluoroscopy or CT guidance. But these have the disadvantage of using ionizing radiation. In MR guided spine injections, MR imaging is used to visualize spinal targets and needle placement, monitor the injected drugs, and detect spread to potentially nearby structures. The visualization of

injectants was done with the help of T1 or T2 weighted MR imaging. Passive visualization was used for localization and display of needle tip on MR images. Magnetic resonance fluoroscopy, similar to CT fluoroscopy, which provides continuous acquisition and display of MR images, was used for interactive determination of the skin entry site, interactive needle placement and for real time monitoring of injections. Following are the six steps for MR imaging guided injections:

1. Focused MR imaging of the target region for anatomical evaluation and planning of the needle path.
2. MR fluoroscopy for a suitable skin entry point.
3. Needle placement navigated by MR fluoroscopy.
4. Confirmation of adequacy of location of needle tip using TSE MR imaging.
5. Monitoring of injection by MR fluoroscopy or intermittent MR imaging.
6. Final MR imaging for the visualization of the injectant, spatial relationship to the target structure, and detection of potential spread to adjacent structures [2].

MR Guided Biopsy

Biopsy is the most frequent clinical interventional application of MRI. This is because of the replacement of surgical biopsies by less invasive and effective image guided percutaneous biopsies. Now a day, surgical biopsies are used only in cases where the pathology is at a difficult anatomical position and is thus inaccessible through image guided procedures due to difficulty in visualization of lesion or surrounding structures. Because of the high soft tissue contrast of MRI, it can be used to provide unique visualization of both anatomy and physiology (Fig 4). In musculoskeletal systems, MRI can be used to detect bone lesions which are not visible in any other imaging modalities due to its high sensitivity. MR guided percutaneous biopsies are safe, accurate and feasible procedures. There are no significant complications associated with these procedures. It can be used to perform biopsies which are not feasible with other imaging modalities [1].

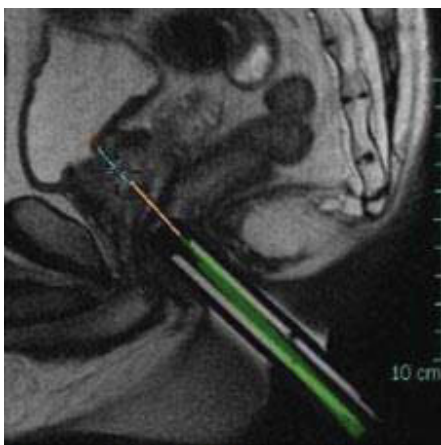


Fig 4: MRI guided biopsy

MR Arthrography

Joint interventions are used for joint disorders with pain, inflammation or effusion. Magnetic Resonance guided interventions of large and small joints are practically possible with several advantages compared to standard techniques. The excellent soft tissue contrast and multi planar are the advantages of MRI in joint interventions. With the help of multi planar capacity, areas with complex anatomy can be approached by adapting the right imaging plane. Magnetic resonance guidance allows all in one MR arthrography with performance of image guided joint punctures and the following imaging for arthrography in the same unit. MR arthrography provides more detailed information of hip and shoulder compared to non-contrast MRI and indirect arthrography. Intra articular corticosteroid injection, which is used for joint treatments, showed variable effects when different techniques were used [14]. The accuracy of injection with better pain relief and functional improvement was found while using image guidance. For joint interventions, MR guidance offers precise targeting. This is important to increase effectiveness of injections, to prevent damage of surrounding tissues, to overcome anatomic difficulties by obesity or disease process.

MRI Guided Thermal Therapy

Similar to MR guided biopsies, it can be used for thermal therapies such as laser ablation (Fig 5), cryoablation, radiofrequency ablation (RFA) and microwave ablation. MRI can be used to guide the probes to the lesion, monitor the tissue temperature and delineate ablated tissue. With the help of temperature monitoring, user can make sure that ablation zone covers the targeted lesion and adjacent structures are not affected. MRI guided laser interstitial thermal therapy (LITT) is a minimally invasive procedure that destroys cells using the thermal energy delivered by laser light. It is found to be feasible and safe in primary and recurrent gliomas [15]. It can also be used for treatment of prostate cancer and liver cancer. The use of MR thermometry as feedback enables the use of MRI guided LITT for safe treatment of critical organs such as brain.

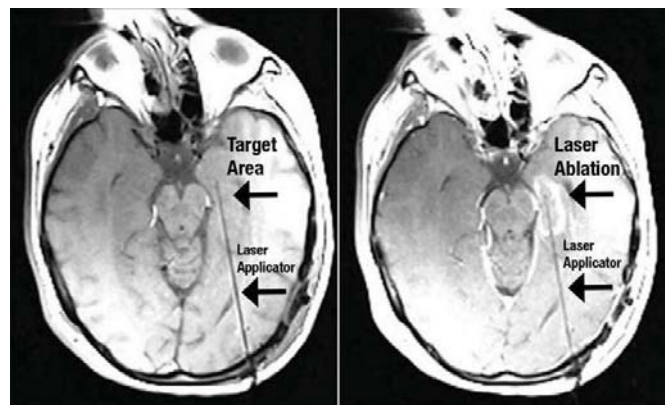


Fig 5: MRI guided laser ablation

Radiofrequency ablation is another application which induces thermal injury by percutaneous application of an electromagnetic field. It is usually done under CT or ultrasound guidance, but developments are done in the field of MRI guided RFA. In MRI guided LITT, images are acquired simultaneously with ablation, whereas in RFA radiofrequency interferes with imaging and hence it requires switching between imaging and application of radiofrequency energy. In cryoablation, tissues are frozen to achieve a lethal effect. On conventional MRI sequences, frozen tissue appears as a signal void due to short transverse relaxation time, which creates high contrast between frozen and unfrozen tissue that is superior to that of CT or ultrasound [15]. Temperature mapping inside the frozen tissue is needed because of the importance of achieving a lethal temperature in the tumor and different organs showing different temperature profiles during freezing.

Cardiovascular Interventions

MRI can be used in endo-myocardial biopsy and many other cardiovascular interventional procedures. Cardiovascular magnetic resonance (CMR) combines excellent soft tissue contrast, multi planar views, and dynamic imaging of cardiac function without ionizing radiation exposure. In endo-myocardial biopsy, MRI significantly improves the diagnostic yield even for smaller specimen volumes compared to X-ray fluoroscopic guidance. This process could be of particular value in disease that affect myocardium in a non-uniform distribution [16]. In case of occluded vessels, where contrast cannot enter the lumen for other imaging modalities, CMR can help to depict the mural contour of occluded vessel and thus help avoid perforation [17]. In case of children it is of great help as it will prevent them from being exposed to unwanted radiation.

Breast Biopsy

Breast MRI has a very high sensitivity and a variable specificity for detection of breast cancer [18]. An MRI guided biopsy is recommended when lesions detected on previous MR scans is not visible or palpable on other imaging modalities [19]. MRI guided vacuum assisted breast biopsies is a quick, safe and accurate alternative to surgical biopsy. Although this provides many advantages, it is an extremely challenging process. The standard practice for MRI-guided breast biopsies involves freehand intervention, with limited mechanisms to ensure coaxial alignment between anesthesia and biopsy tool insertion and no control over the final position of the needle tip. The application of robotic technology to biopsy procedures can significantly increase positional accuracy and operator proficiency [19]. Researchers have invented an image guided automated robot (IGAR) which can perform breast biopsy under image guidance. It demonstrates MRI compatibility and maintains safe operation, adequate shielding, high image quality, and accurate robotic control [19]. Another improvement in this field is the introduction of vacuum assisted breast guidance by using open 1.0T MRI technology which will be useful for obese people and for people with claustrophobia [20].

MRI Guided Focused Ultrasound

Focused ultrasound is the non-invasive focal delivery of energy into soft tissues. MRI guided focused ultrasound allows the elimination and modification of tissues for therapeutic purposes while the energy is delivered under MRI guidance [21]. The thermal feedback provided by the MRI allows intervention monitoring by immediate evaluation of temperature in the target volume and thus helping to minimize the damage done to adjacent tissues [3]. This method is used for treatment of uterine fibroids (Fig 6) and various tumors. Another application of this method is treatment of intra-ventricular hemorrhage in infants. Usually it is treated by cerebral shunt replacement or invasive brain surgery. By using MRI guided focused ultrasound, brain of pediatric patients can be treated in non-invasive manner. Scientists have developed a MR conditional robot with 5 DOF which can be used to perform this surgery [6]. A major constraint in using MRgFUS is the organ motion. As the organ motion increases, the intervention time increases and thus with currently available technologies, MRgFUS is clearly infeasible for treating moving abdominal organs [3].

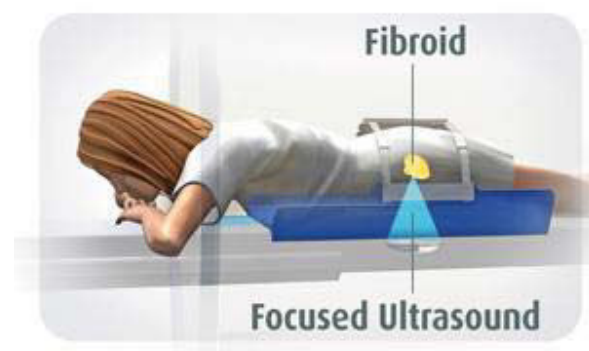

Fig 6: MRI guided focused ultrasound for uterine fibroid treatment

Other Applications

MRI is used widely for the musculoskeletal soft tissue interventions. The high soft tissue contrast of MRI promotes its application in this field. MRI is used to provide minimally invasive treatments for lesions that are not approachable by traditional radiology methods. It has various applications such as percutaneous biopsy, percutaneous cyst aspiration, and percutaneous tumor ablation [5]. Another application of interventional MRI is in the field of neuroradiology. It can be used for the aspiration and biopsy. The spatial resolution, tissue contrast and multi planar capabilities of MR are useful for these applications [8]. The application of this technology to pediatric neurosurgery allows real-time assessment of the anatomical consequences of surgical and anesthetic interventions, accountability of brain shifts, precise intraoperative localization of pathology, confirmation of the exact site of biopsy or completeness of lesion removal, and immediate identification of some intraoperative and early postoperative complications [22]. Yet another application of MRI is for catheter tracking. With the help of catheter tracking, many endovascular interventions can be done. Some

applications of catheter tracking are cardiac electrophysiology, angioplasty, and stenting of renal arteries, carotid arteries and aortic aneurysms [23]. In addition to these developments, studies are being conducted for creation of MR conditional robot which can be helpful in various fields.

VI. CONCLUSION

MRI is becoming a primary imaging modality for image guided procedures. Although it has many contraindications, it is a safe tool for use in many cases. It has a lot of applications in medical field ranging from open surgery to minimally invasive procedures. Many developments are taking place in the field of interventional MRI. One of the major developments is the introduction of MR compatible robots. Robots are being developed to assist doctors in various procedures. The robots used should be highly accurate in operation and should not deteriorate the quality of images acquired.

One of the major limitations of high field interventional MRI is the limited patient access. New systems have to be developed which provides better access to the patients. This could be done either by widening the bore of the MRI or by creating a new patient table which provides better patient access. This will be really helpful for patients with claustrophobia and also for doctors to do the interventional procedures comfortably. Research has to be done in these areas to make it possible.

REFERENCES

- [1] Blanco Sequeiros, R. Ojala, J. Kariniemi, et al. (2005) "MR-Guided Interventional Procedures: A Review". *Acta Radiologica* 46.6, 576-586.
- [2] Jan Fritz, Roberto Blanco Sequeiros, and John A. Carrino. (2011) "Magnetic Resonance Imaging-Guided Spine Injections". *Topics in Magnetic Resonance Imaging* 22.4: 143-151.
- [3] Arjo J Loeve, Jumana Al-Issawi, Fabiola Fernandez-Gutiérrez et al. (2016) "Workflow And Intervention Times Of MR-Guided Focused Ultrasound – Predicting The Impact Of New Techniques". *Journal of Biomedical Informatics* 60: 38-48.
- [4] Adrienne E Campbell-Washburn, Anthony Z Faranesh, Robert J Lederman, et al. (2015) "Magnetic Resonance Sequences And Rapid Acquisition For MR-Guided Interventions". *Magnetic Resonance Imaging Clinics of North America* 23.4: 669-679.
- [5] Nour, Sherif G. and David K. Monson. (2011) "MRI-Guided Musculoskeletal Soft Tissue Interventions". *Topics in Magnetic Resonance Imaging* 22.4: 197-205.
- [6] Karl D Price, Vivian W. Sin, Charles Mougnot et al. (2016) "Design And Validation Of An MR-Conditional Robot For Transcranial Focused Ultrasound Surgery In Infants". *Medical Physics* 43.9: 4983-4995.
- [7] Martin Leach. (2007) "PRINCIPLE OF MAGNETIC RESONANCE". *Physics for Medical Imaging Applications*, 25–36.
- [8] Jonathan Lewin. (1999) "Interventional MR Imaging: Concepts, Systems, And Applications In Neuroradiology". *AJNR Am J Neuroradiol* 20:735–748
- [9] Mark J White, John S. Thornton, David J. Hawkes, et al. (2014) "Design, Operation, And Safety Of Single-Room Interventional MRI Suites: Practical Experience From Two Centers". *Journal of Magnetic Resonance Imaging* 41.1: 34-43.
- [10] Kwan Hoong, Azlan C Ahmad, MS Nizam et al. (2003) "Magnetic Resonance Imaging: Health Effects and Safety". <http://www.who.int/pchemf/meetings/archive/en/paper04ng.pdf>
- [11] E. Kanal, A. Barkovich, C. Bell, et al (2013) "ACR guidance document on MR safe practices: 2013", *Journal of Magnetic Resonance Imaging*, vol. 37, no. 3, pp. 501-530
- [12] Joyce G. R Bomers, J. P. Michiel Sedelaar, Jelle O. Barentsz et al. (2012) "MRI-Guided Interventions For The Treatment Of Prostate Cancer". *American Journal of Roentgenology* 199.4: 714-720.
- [13] Axel Krieger, Sang-Eun Song, Nathan Bongjoon Cho et al. (2013) "Development And Evaluation Of An Actuated MRI-Compatible Robotic System For MRI-Guided Prostate Intervention". *IEEE/ASME Transactions on Mechatronics* 18.1: 273-284
- [14] Marietta Garmer and Dietrich Grönemeyer. (2011) "Magnetic Resonance-Guided Interventions of Large And Small Joints". *Topics in Magnetic Resonance Imaging* 22.4: 153-169.
- [15] Elena A Kaye, Kristin L. Granlund, Elizabeth A. Morris et al. (2015) "Closed-Bore Interventional MRI: Percutaneous Biopsies And Ablations". *American Journal of Roentgenology* 205.4: W400-W410.
- [16] Toby Rogers, Kanishka Ratnayaka, Parag Karmarkar et al. (2016) "Real-Time Magnetic Resonance Imaging Guidance Improves The Yield Of Endomyocardial Biopsy". *Journal of Cardiovascular Magnetic Resonance* 18.Supp 1: Q69.
- [17] Christina E Saikus and Robert J. Lederman. (2009) "Interventional Cardiovascular Magnetic Resonance Imaging". *JACC: Cardiovascular Imaging* 2.11: 1321-1331.
- [18] Boo-Kyung Han, Mitchell D. Schnall, Susan G. Orel et al. (2008) "Outcome Of MRI-Guided Breast Biopsy". *American Journal of Radiology* 191.6: 1798-1804
- [19] Chan, Kathryn G., Tim Fielding, and Mehran Anvari. (2016) "An Image-Guided Automated Robot For MRI Breast Biopsy". *The International Journal of Medical Robotics and Computer Assisted Surgery* 12.3: 461-477
- [20] Barbara Krug, Martin Hellmich, Angela Ulhaas et al. (2016) "Vacuum-Assisted Breast Biopsies (VAB) Carried Out On An Open 1.0T MR Imager: Influence Of Patient And Target Characteristics On The Procedural And Clinical Results". *European Journal of Radiology* 85.6: 1157-1166.
- [21] Hynynen, Kullervo. (2010) "MRI-Guided Focused Ultrasound Treatments". *Ultrasonics* 50.2: 221-229.
- [22] John A Lancon, Kevin R. Killough, Gurmeet Dhillon et al. (1999) "Interventional Magnetic Resonance Imaging Guided Aspiration And Biopsy Of A Cystic Midbrain Tumor". *Pediatric Neurosurgery* 30.3: 151-156.
- [23] Wei Wang. (2015) "Magnetic Resonance-Guided Active Catheter Tracking". *Magnetic Resonance Imaging Clinics of North America* 23.4: 579-589.
- [24] Hans Peter Klotz, Renata Flury, Peter Erhart et al. (1997) "Magnetic Resonance-Guided Laparoscopic Interstitial Laser Therapy Of The Liver". *The American Journal of Surgery* 174.4: 448-451.
- [25] Remko van der Weide, Karel J. Zuiderveld, Chris J. G. Bakker et al. (1998) "Image Guidance Of Endovascular Interventions On A Clinical MR Scanner". *IEEE Transactions on Medical Imaging* 17.5: 779-785.
- [26] Christian Wybranski, Ilya Adamchic, Friedrich-Wilhelm Röhl et al. (2016) "Freehand Direct Arthrography Of The Shoulder Using Near Real-Time Guidance In An Open 1.0-T MRI Scanner". *Skeletal Radiology* 46.1: 51-58.

[27] Joachim Kettenbach, Daniel F. Kacher, Angela R. Kanan et al. (2006) "Intraoperative And Interventional MRI: Recommendations For A Safe Environment" *Minimally Invasive Therapy* 000:000; 1–13

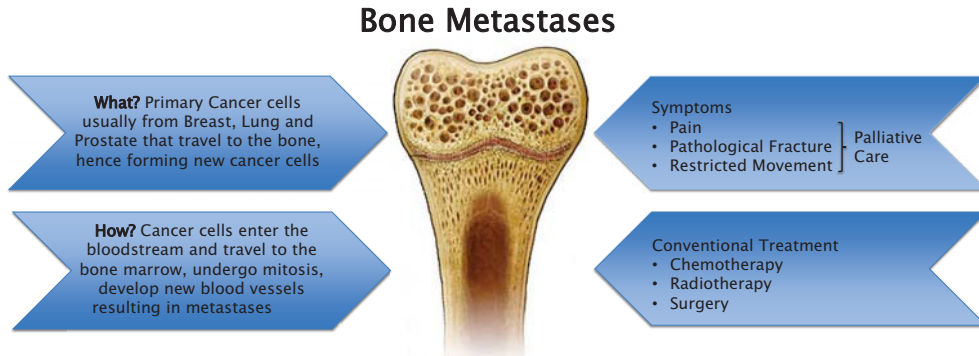
[28] Christoph Hennersperger, Bernhard Fuerst, Salvatore Virga et al. (2016) "Towards MRI-Based Autonomous Robotic US Acquisitions: A First Feasibility Study". *IEEE Transactions on Medical Imaging* : 1-1.

[29] Stephen G Hushek, Alastair J. Martin, Michael Steckner et al. (2008) "MR Systems For MRI-Guided Interventions". *Journal of Magnetic Resonance Imaging* 27.2: 253-266.

Interventional Palliative Treatment for Bone Metastases

Ashwith Chandrahas Kottary, Medical Systems Engineering, Fakultät Für Elektrotechnik Und Informationstechnik, Otto-von-Guericke Universität, Magdeburg

Introduction



Palliative Treatment

Due to the vulnerability of cancerous cells to extremely high or low temperatures, the use of different techniques to treat metastatic diseases are available. Several image-guided thermal ablation techniques have become evident as minimally invasive and productive therapeutic options in the management of painful bone metastases.

Figure 1: Percutaneous Radiofrequency Ablation

- Uses high temperature to kill cancer cells, (60-100°C)
- CT or Ultrasound is used for image guidance

Figure 2: Percutaneous Cryoablation

- Uses extremely low temperatures to kill cancer cells, (-100°C)
- CT, MRI or Ultrasound is used for image guidance

Figure 3: Microwave Ablation

- Uses alternating EM field to bring about dielectric heating in the tissue to achieve high temperatures to kill cancer cells.
- CT or Ultrasound is used for image guidance

Figure 4: High Intensity Focused Ultrasound

- Uses the principle of heating tissue between 65°C and 85°C by focusing high intensity ultrasound energy onto the target tissue
- MRI or Ultrasound is used for image guidance

Figure 5: Laser Ablation

- Uses highly coherent, monochromatic light to induce heat energy in the tissue leading to denaturation of proteins that leads to cell death.
- MRI is used for image guidance.

Thermal Ablation

Palliative Care

Cementoplasty

Transcatheter Arterial Embolization

Future Outlook

Figure 6: Vertebroplasty

- Used to relieve pain caused by vertebral body compression fractures.
- Polymethylmethacrylate (PMMA) cement is inserted via a hollow needle into the fractured site that hardens to provide stability to the vertebra.
- X-ray is used to ensure accurate positioning of the needle.

Figure 7: Kyphoplasty

- Used to relieve pain caused by vertebral body compression fractures.
- A balloon is inserted via a hollow needle which is then inflated on reaching the fractured site creating a cavity for the cement, hence restoring the height of the vertebra.
- Polymethylmethacrylate (PMMA) cement is inserted to provide stability to the vertebra.
- X-ray is used to ensure accurate positioning of the needle.

Figure 8: Transcatheter Arterial Embolization

- Used to treat Hypovascular Bone Tumour which poses a risk of excessive bleeding during any procedure.
- Used as a pre-procedure to Thermal Ablation and Cementoplasty techniques.
- X-ray Fluoroscopy is used for image guidance and Angiography is performed to study the nature of vessels feeding the tumour.
- Permanent solid particles like Polyvinyl Alcohol (PVA) is used to block arteries supplying the tumour and temporary solid particles like Gelfoam is used to block proximal feeding arteries.

Figure 9: Magnetic Chemotherapy

- Magnetic Nanoparticles are combined with cancer killing drugs in the same Nanoformulation.
- Combination of these two entities can be used for the application of hyperthermia along with chemotherapy.
- Magnetic Chemotherapy helps in achieving localized treatment of cancer while avoiding damage to the healthy tissue.

Figure 10: Gene Therapy

- Immune system can be altered with Cancer killing Genes in-vitro and can be returned to the body where they can fight cancer more effectively.
- Cancer cells are removed and altered genetically in a way that the immune system holds a strong defense mechanism.
- A gene is introduced into the tumour making it more vulnerable to chemotherapy and other cancer killing agents while making bone marrow and other organs resilient to chemotherapy.

Conclusion

- Variety of treatment options are available for palliative care but selection criteria should be based on the nature of the disease and the systemic condition of the patient
- Minimally invasive procedures have gained recognition and are being preferred over conventional methods due to its advantages like high efficacy, fast recovery time, lower rate of trauma and minimal risk of complication
- As a cure to cancer, Palliative Treatment could be an option with the evolution of techniques such as Magnetic Chemotherapy and Gene Therapy

References

[1] Javier Nazario, MD et al; Thermal Ablation of Painful Bone Metastases; Techniques in Vascular and Interventional Radiology ,Volume 14, Issue 3, September 2011; DOI: 10.1053/j.tvir.2011.02.007
 [2] Deanna Cross, PhD et al: Gene Therapy for Cancer Treatment: Past, Present and Future: Clin Med Res. 2006 Sep; 4(3): 218-227
 [3] Alessandro Napoli, MD, PHD: INSIGHTECH: Insightech for oncology; Available[Internet]; http://www.insightech.com/us/clinical/oncology
 [4] Kamran Afrar, MD et al; Magnetic Resonance Imaging-Guided Laser Ablation of Bone Tumors; Tech Vasc Interv Radiol. 2011 Sep; 14(3):177-82; DOI: 10.1053/j.tvir.2011.02.010
 [5] Chuanxing Li MD et al; Noninvasive treatment of malignant bone tumors using high-intensity focused ultrasound; Cancer. 2010 Aug 15; 116(16):3934-42; DOI: 10.1002/cncr.25192
 [6] Akhihiro Uemura et al; Transcatheter arterial embolization for bone metastases from hepatocellular carcinoma; Radiol (2001) 11: 1457; DOI:10.1007/s003300000792
 [7] Christina Janko et al; Magnetic Drug Targeting Reduces the Chemotherapeutic Burden on Circulating Leukocytes; Int. J. Mol. Sci. 2013, 14(4), 7341-7355; doi:10.3390/ijms14047341
 [8] Well Cornell Brain and Spine center: Spinal Compression Fractures; Available[Internet]; http://wellcornellbrainandspine.org/condition/spinal-compression-fractures/surgery-spinal-compression-fractures

INTERVENTIONAL PALLIATIVE TREATMENT FOR BONE METASTASES

ASHWITH CHANDRAHAS KOTTARY

Otto-von-Guericke University Magdeburg

ashwithkottary78@gmail.com

ABSTRACT

Bone metastases is the most common type of cancer that causes debilitating pain which in turn results in a poor quality of life for a patient. Palliative treatments are the ones which are done to relieve the symptoms (primary goal) or sometimes even cure the symptoms. Conventional procedures like chemotherapy and radiotherapy can be used with a palliative intent but it has its own limitations regarding the damage to the healthy cell and exposure to radiation respectively. Minimally invasive procedures are being preferred over conventional techniques because of their gains like accuracy, efficacy, minimal risk and improved quality of life. The main aim of this review article is to summarize various types of minimally invasive procedures available for patients with bone metastases with a palliative intent and new evolving treatment which may be available in the near future.

Keywords: Metastases, Minimally invasive, Palliative, Thermal ablation

Abbreviation: CT computed tomography, MR magnetic resonance, RFA radiofrequency ablation, MWA microwave ablation, LITT laser interstitial thermal therapy, HIFU high intensity focused ultrasound, TAE transcatheter arterial embolization

1. INTRODUCTION

Tumours are abnormal cells which group together to form a lump or a growth. They can be classified as benign tumour (non-cancerous), premalignant tumour (may develop into a cancer) and malignant tumour (cancerous). Malignant tumour is made up of cancer cells which continue to multiply destructively and grow in size, resulting the tumours to invade into nearby tissues and organs, which can cause damage. ^[1] Cancer is often named after the part of the human body where it first started to grow. This is known as the primary site or the primary cancer. When the cells from the primary cancer spreads to the other part of the body, they undergo mitosis and form a new type of cancer called a secondary cancer or metastases. ^[2]

Bone is one of the usual metastatic area for a cancer patient and bone metastases is a complication and the most common type of pain related to cancer. Bone metastases occur when cancer cells enters the blood stream, travel to the bone marrow, undergo mitosis and then grow new blood vessels to obtain oxygen and food, which in turn results in the cancer cells to grow more rapidly and spread. It results in decreased quality of life in patients due to acute pain, restricted movement, and pathological fracture. Pain is one of the most recurring and most feared consequences of cancer that debilitates the quality of life. It is seen that more than 70% of patients with advanced cancer report pain at some stage of their disease and about 75% of those sufferers describe their pain as moderate to very severe. ^[3]

Conventional treatment of metastatic bone tumour includes chemotherapy, radiation therapy, surgery to reduce pain and prevent bone destruction, the use of bisphosphonate and denosumab. Radiation therapy is the most frequently used mode of treatment.^[4] When a cancer is recurring after one kind of treatment, there is a possibility that another mode of treatment may be successful, or at least shrink it. But the cancer tends to become resistant to all treatment, it is then important to weigh the possible benefits of a new treatment against the possible downsides. No matter what kind of treatment patient decides to go with, one has to make sure that the treatment is given to relieve the symptoms. This type of treatment is called palliative treatment. Palliative care helps relieve symptoms, but is not expected to cure the disease. It can be given along with cancer treatment, or can even be cancer treatment.^[5] Minimally invasive procedures are preferred over conventional methods due to its high efficacy, fast recovery time, lower rate of trauma and minimal risk of complications.

In this paper, we are going to discuss some of the interventional treatments available as a palliative treatment for bone metastases and suggest future direction for better management of patients with metastatic bone tumour.

2. PALLIATIVE TREATMENT OF BONE METASTASES

Conventional Treatment for cancer is either done systemically with chemotherapy or can be locally performed with surgery and radiotherapy. With the evolution in the field of minimally invasive procedures, new tools and innovative methods are made available for the treatment of cancer.^[6] Three main factors must be taken into account prior to any image-guided interventions that is to be performed. 1) Adequate imaging of the affected site is essential for planning the procedure. Because plain radiographs are rarely adequate, cross-sectional imaging with computed tomography (CT) or magnetic resonance (MR) imaging is necessary for evaluating the extent of disease and the proximity of the lesion to vital structures. 2) The location and severity of the pain must be determined by physical examination and validated pain scales

respectively. 3) The patient's use of opioid analgesics must be inventoried as it can be translated into a morphine-equivalent dose for outcome analysis and future comparisons.^[3]

2.1 Thermal ablation techniques

Due to the vulnerability of cancerous cells to extremely high temperatures, the use of different techniques to treat metastatic disease are available.^[7] Several image-guided thermal ablation techniques have become evident as minimally invasive and productive therapeutic options in the management of painful bone metastases. Different types of ablative technologies have been used for the treatment of bone metastases which include radiofrequency ablation (RFA), cryoablation, microwave ablation, laser ablation, and focused ultrasound.^[8]

2.1.1 Percutaneous Radiofrequency Ablation

Percutaneous RFA has gained acceptance over the past decade as the primary treatment for extra spinal osteoid osteomas, replacing the once-popular practice of removing these lesions surgically. Over the past few years RFA has been applied to treatment of painful bone metastases, with promising early results. RFA is reserved for patients with painful osteolytic bone metastases who are not suitable candidates for or have not benefited from other standard forms of therapy.^[3]

Image guidance is an important factor for the success of this treatment as it contributes at every stage of the procedure. Computed tomography (CT) is used for image guidance. During the pre-procedure stage it is used to evaluate the configuration and volume of the tumour, to select size of the electrode tip and for planning a safe path to the lesion. During the procedure, it is used to guide the needle and make sure that the non-insulated active tip of the electrode are localised. During the post-procedure stage, it is used for the confirmation of the success of the procedure and for patient follow up. Due to good anatomical resolution of bone tissue and faster image acquisition time CT is preferred over other imaging modalities.^[6]

Certain indications must be satisfied to consider a patient as a suitable candidate for RFA treatment. The patient's pain must be correlated

to one or two site of metastatic disease in bone and it must be moderate to severe focal pain, rating 4 or higher on a pain scale from 0 to 10. Osteolytic, osteoblastic lesion and soft tissue metastases are complaint to percutaneous ablation techniques. A bone biopsy device or drill may be required in the case of osteoblastic lesion to establish an access tract for the ablation probe. A few contraindications to ablation technique include that the tumours that are less than 1cm away from the spinal cord, motor nerves, arteries, bowel and bladder cannot be treated by RFA. In case of Lesions present in weight bearing bones, they can only be treated if there is no risk of an impending fracture. Patients who have undergone prior surgical stabilization with metallic hardware and have recurrence of tumour at the surgical site are not eligible for RFA. Large hypervascular bone metastases are not suitable for RFA. [3][8]

Radiofrequency ablation of a cancerous bone tissue depends on its electrical conductivity. A device setup is made up of a RF generator which consists of an alternating energy of high frequency radiowaves (450 to 600 kHz). It is further connected to the electrode or the probe and the grounding pads (monopolar). A complete electrical circuit is created through the body. The RF current passes through the tissue because of the presence of excess ionic fluid. Since tissue is not a perfect conductor, it provides resistance against the RF current which causes heating of the tissue eventually leading to apoptosis. Two different operating modes are available for RF current application i.e. monopolar or bipolar modes. Monopolar mode consists of a single electrode which is used to deliver current at the site of the tumour, while ground pads acts as a surface electrode to complete the electrical circuit through the body. In bipolar mode, current flows between the two electrodes. Grounding pads are not required. [9][6]

During the RFA procedure, the patient is under conscious sedation or local or in some case general anaesthesia. Insulated biopsy needle is inserted to the site to provide a path and give coaxial placement of the electrode. RFA electrodes metal electrodes ranging from 14 to 17 gauge is inserted through the cannula to the lytic component of the bone metastases. Electrodes can be straight or having an

expandable array design with varying active tip length 0.7-3cm. Selection of the type of electrode and the size of the active depend on the size of the tumour to be ablated. On accurate insertion of the electrode, the cannula is withdrawn back so that it is not in contact with the active tip of the electrode. A high frequency alternating current is applied through the electrode which raises the temperature within the tissue to 60 to 100°C leading to immediate cell death. Ablations are usually performed for 5-10mins depending on the size of the tumour and overlapping RFA ablations are performed at bone-tumour interface for pain palliation process. RF electrodes follow various strategies to restrict reaching high temperatures by including internal cooling with chilled water or diffusion of water along the electrode tines before, during or after the ablation. On completion of the procedure, RF electrode is withdrawn and a dressing is applied to the skin. [3][8][6][10]

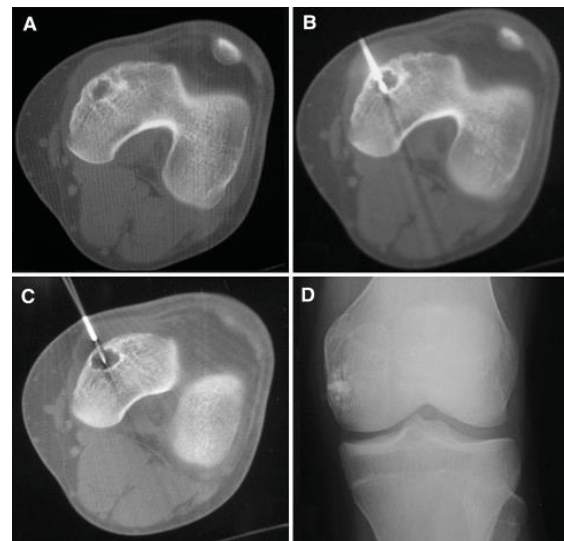


Fig.1. A) CT scan showing tumour in the distal femoral epiphysis B) Biopsy needle within tumour C) Electrode within the tumour D) Image after RFA and cementation [6]

RFA in bone tumour is mainly intended to use for palliative care to reduce the pain, improve functionality and quality of life for patients with painful bone metastases. But rarely, RFA can be used as a curative procedure for patients with single metastases restricted in size.

2.1.2 Percutaneous Cryoablation

On the contrary to RFA, Cryoablation uses extremely low temperatures to kill the tumours. It is one of the oldest thermal ablation technique with a high success rate of treatment for neoplasms in different organs. Early cryoablation procedures were restricted to intraoperative use as only large diameter and uninsulated probes were available. In this case liquid nitrogen was directly applied to the surgical field. Due to the advancement and development of miniaturised cryoprobes, percutaneous cryoablation was made feasible. Computed tomography CT, MR imaging and ultrasound can be used as an imaging modality for this procedure. But in the case of bone metastases CT is preferential over other modalities. Although real time monitoring is not possible, its fast image acquisition is sufficient for this process. ^{[11][12]}

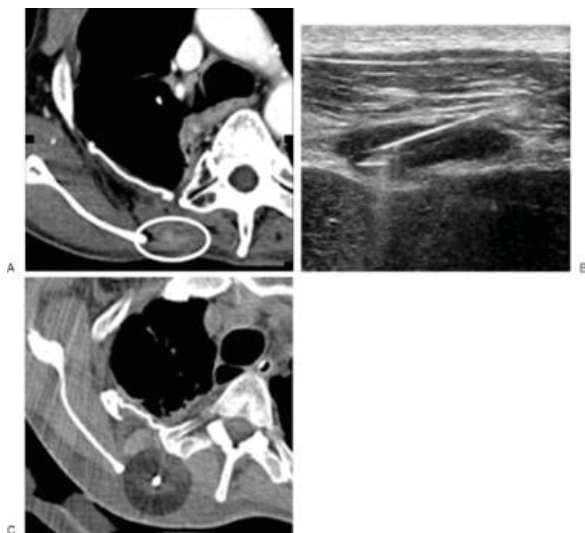


Fig.2. A) Contrast enhanced CT image shows metastatic esophageal sarcoma at the scapula B) Ultrasound image shows cryoprobe placement into the metastases C) Unenhanced CT image shows ice ball encompassing the metastases ^[10]

Cryoablation follows the principle of freezing the tissue to critically low temperatures which leads to injury in the cell by crystallization of water molecules and also by intrusion of the microcirculation of the tissue being treated. ^[12] Certain indications must be satisfied to consider a patient as a suitable candidate for RFA treatment. The patient's pain must be correlated to one or two site of metastatic disease in bone and it must be moderate to severe focal pain, rating 4 or higher on a pain scale from 0 to 10.

Osteolytic, osteoblastic lesion and soft tissue metastases are complaint to percutaneous ablation techniques. A bone biopsy device or drill may be required in the case of osteoblastic lesion to establish an access tract for the ablation probe. A few contraindications to ablation technique include that the tumours that are less than 1cm away from the spinal cord, motor nerves, arteries, bowel and bladder cannot be treated by this method. ^{[3][8]}

Patient is under conscious sedation or local anaesthesia (in some cases general anaesthesia) may be used for this procedure. In certain cases, a biopsy needle is essential to create an access path for the cryoprobe to reach the lesion. Cryoprobe, usually in the range of 11 to 17 gauge and 1.2 to 2.4mm ^[10] in diameter is inserted into the target tissue. Needle is withdrawn from the active tip of the cryoprobe so as to avoid the unnecessary transmission of ice to various locations. Then, room temperature argon gas is delivered through the cryoprobe. Due to the rapid expansion of the high pressure gas as it flows through the distal tip of the cryoprobe, the temperature drops down around -100°C in a few seconds. An ice ball of 3.5cm in size is generated. Multiple cryoprobes (upto 25) may be used simultaneously to generate larger ice balls which depends on the size of the target tumour. In the case of multiple cryoprobes, the distance between them within tumour should be approximately 2cm and 1cm away from the tumour margin. Helium gas is then passed through the cryoprobe to attain the thawing effect. Repeated freeze and thaw technique is necessary to avoid unnecessary cell death between temperatures 0 to -20°C . In the first freezing phase, the ice crystals are formed outside the cell. When thawing phase commences, the water formed diffuses inside the cell due to the difference in the osmotic gradient across the cell membrane. Duration of this phase directly determines the extent of cell damage caused. The presence of water within the cell causes the formation of ice crystals within the cell during the second freezing phase eventually leading to rupture of the cell membrane and cell death. ^[13] The freeze-thaw-freeze was performed for 10min-8mins-10mins respectively. ^[14] The variations in these times depend on the state of the lesion covered by ice and its presence to the critical nearby structures. Apoptosis occurs at a temperature of -40°C or

lower, which is in turn at a depth of 3 mm from the edge of the ice ball margin. Cryoprobes are finally thawed for few minutes until they attain a temperature of approximately 25°C before removing them from the patient and a dressing is applied to the skin. [8][10][7]

2.1.3 Microwave Ablation

Microwave ablation (MWA) uses the same principle as RFA i.e. deploying high temperatures to kill the tissue. However, MWA uses a different mechanism to attain cytotoxic temperatures. Tissues in the human body are dielectric materials. An alternating electromagnetic (EM) field is applied to these tissues resulting in dielectric heating. Since the water molecule present in the tissues are polar by nature, they tend to oscillate rapidly out of phase with the applied EM field. During this process when the water molecule oscillates back and forth, they absorb some of the EM energy and thus converting them to heat energy. Tissues with high percentage of water molecule absorb more EM energy, resulting more heating and vice versa. Hence the EM microwaves heat the tissue by disturbing the water molecules which leads to the production of friction and heat, in turn leading to cell death. [15][9]

	Units	Liver	Lung (aerated)	Kidney	Bone
RF conductivity (@ 480 kHz)	S/m	0.148	0.122	0.226	0.022
Relative permittivity (@ 2.45 GHz)		43.3	20.5	52.8	11.4
Effective conductivity (@ 2.45 GHz)	S/m	1.68	0.804	2.43	0.394
Wavelength (@ 2.45 GHz)	cm	1.8	2.5	1.5	3.6
Thermal conductivity	W/m K	0.564	0.302	0.54	0.4
Density	kg/m ³	1050	260	1050	1990
Specific heat capacity	J/kg K	3600	2500	3890	1300
Perfusion rate	ml/min kg	1000	200	3000-4000	50

Fig.3. Tissue properties at RF and microwave frequencies at 37°C [9]

Percutaneous microwave ablation is performed under conscious sedation or local anaesthesia and general anaesthesia in some cases. Both, Ultrasound and CT can be used for image guidance but CT is the most preferred choice of imaging modality used for the localization of the tumours. The setup consists of a microwave generator which delivers energy in the frequency range of 915MHz-2.45GHz. A thin

microwave antenna ranging from 14-11 gauge is inserted into the tumour. In some cases, a biopsy needle is necessary to pierce through the bone and provide a coaxial access path for the microwave antenna. The cannula is further withdrawn from the active non insulated part of the antenna in order to avoid unnecessary dissipation of heat and burns. A single antenna can treat tumours less than 3.5cm in diameter. For treating tumours larger than 3.5cm in size multiple antenna can be used simultaneously, each connected to its own generator. An electromagnetic microwave is emitted from the exposed non insulated part of the antenna thus killing the tissue. It is possible to achieve high intra tumour temperature, larger ablation zone and faster procedure time using percutaneous microwave ablations. No grounding pad is required during this process as it does not depend on electrical current. On completion of the tumour the antenna is withdrawn and a dressing is applied on the skin. [16][17][15][9]

Microwave ablation even though it's proved to be effective, not many clinical study has been performed. Based on a study by Claudio Pusceddu et al microwave ablation is proved to be minimally invasive, safe, effective and well tolerated by patients. As per the study, during the 3 month clinical follow up, out of 18 patients 13 of them were symptom free. 4 of the patients were symptomatic with considerably lower pain score. Only 1 patient experienced reoccurrence of symptoms. However the study demonstrates the palliative effects of microwave ablation but it was limited by the short life expectancy of the patients. Further studies with longer follow up period is necessary to replicate the results and prove its efficacy. [17]

2.1.4 Laser Ablation

Laser ablation is also known as laser photocoagulation or laser interstitial thermal therapy (LITT). It uses the highly coherent, monochromatic light to induce heat energy in the tissue which leads to denaturation of proteins further killing it. Neodymium yttrium aluminium garnet (Nd:YAG) type of laser is often used for this procedure with a wavelength of 1,064nm. Whole procedure can be done under intermittent and real time image guidance of magnetic resonance (MR) imaging. [18]

Percutaneous Laser ablation is performed under conscious sedation or local anaesthesia (general anaesthesia may be used in some cases). Low power (2W) light energy is directed through a thin quartz fiberoptic with disperse tip which is usually 400 μm in diameter. Each fiber is expected to ablate $\sim 1.6\text{cm}$ diameter of tissue in the bone. For ablation of larger volumes of the tissue, multiple fibers may be used which is placed 2cm apart from each other in the lesion. If the lesion is surrounded by a thick cortical bone, a bone drill needle (18gauge) is inserted to create an access path through which the fiber is inserted coaxially. The needle is withdrawn to expose the active tip of the fiber. Once in place the laser is activated at low power for about 6mins to 10mins depending on the size of the target. Target temperature thresholds (thermometry) can be placed on the vital structures like vertebra, neural elements, paraspinal tissues or pelvis to provide real time feedback. When the temperature reaches the threshold temperature, the target temperature threshold sends a feedback causing the laser to shut down automatically thus protecting the vital structures. Overlapping ablations may be necessary if the target is large in size. [13][19]

Laser ablations shows high success rate and the extent of pain after the procedure is considerably reduced thus improving the quality of life. It is proven to be safer option to treat cases such as metastases present in the spine over other thermal ablation technique. Even though the result is promising, further research is required to prove its efficacy.

2.1.5 High Intensity Focused Ultrasound

High intensity focused ultrasound (HIFU) is a type of non-invasive thermal ablation technique. It uses the principle of heating a tissue between 65°C and 85°C by focusing high intensity ultrasound energy on to the target tissue. Either MR imaging or Ultrasound can be used as an image guiding modality. MR guided focused ultrasound (MRgFUS) has an advantage over treatment guided by ultrasound like better soft tissue imaging which gives us good demarcation between two tissues and the possibility to monitor the heat produced accurately during the procedure. Criteria for HIFU include that the tumour must be visible on the MR imaging, must not be blocked by bowel and scarring and target bone should be

minimum 1cm away from the bone. It can be used for the treatment of ilium, pelvis, sternum, limbs, ribs, shoulders and posterior part of the lower lumbar spine. Persons with metallic implants, unstable or stabilized bone and extensive scarring cannot be treated. [20]

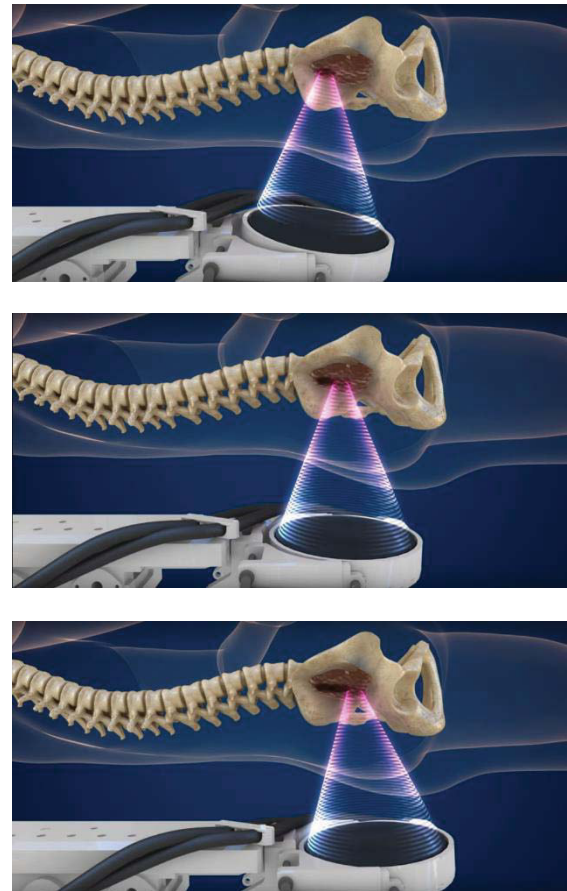


Fig.3. Ultrasound treating tumour inside the MR scanner [30]

HIFU is performed with the patient lying inside the MR imaging scanner. Usually conscious sedation or local anaesthesia. After accurate planning of the treatment based on preoperative images the patient was positioned accordingly in reference to the ultrasound. Initially only low power sonifications were performed to ensure accuracy. Contrast enhance MR imaging scans were performed to ensure ablation zone and that there was no damage to other tissues. [21] According to a study by Chuanxing Li et al, using ultrasound as image guidance, it is seen that a patients experienced fever, swelling in the target area, burns and numbness. All symptoms were normalized within a week. HIFU can be used

as treatment option for palliative care and in adjuvant to chemotherapy as well. [22]

2.2 Cementoplasty

Spinal metastases are seen in patients with advanced stages of cancer. It leads to abnormalities in the posterior margins of the vertebral body causing fracture, which in turn causes pain and decreases the quality of life. Vertebroplasty and kyphoplasty are minimally invasive procedures used to treat fractures and relieve the symptoms. [23]

2.2.1 Vertebroplasty

Vertebroplasty takes place with local anesthesia or conscious sedation, under the guidance of x-ray fluoroscopy. A biopsy needle (11-13 gauge) is inserted into the fractured vertebra percutaneously and x-ray images are taken to ensure accurate positioning. Bone biopsy can be performed coaxially with a needle. Polymethylmethacrylate (PMMA) cement is inserted into the fractured site via the hollow needle, which hardens in 5-10 mins providing an internal cast like support to stabilize the vertebra. Needle is removed and the incision on the skin is covered with a bandage. [24]

2.2.2 Kyphoplasty

Kyphoplasty is used to restore the height of the vertebra in addition to relieve pain. It is also performed under the guidance of x-ray fluoroscopy. Patient, under general anesthesia or conscious sedation is pierced with biopsy (8 gauge) needle, which is inserted into the fractured vertebra. Bone biopsy can be performed coaxially with a needle. A balloon is inserted via the needle which is then inflated on reaching the fractured site to create a cavity for the cement and restore the normal height of the vertebra. Balloon is deflated and removed. Polymethylmethacrylate (PMMA) cement is inserted into the cavity, which hardens in 5-10 mins, stabilizing the vertebra. Needle is removed and the incision on the skin is covered with a bandage. Kyphoplasty is 5-10 times more expensive compared to vertebroplasty. [24]

Vertebroplasty and kyphoplasty shows similar rate of pain reduction and increase in quality of life. Both the procedures pose the same complications like pain around the injection site, allergic reaction to the cement and

infection. Leakage of the cement into the epidural space and neural foramina leading to spinal cord compression or nerve root compression, pulmonary embolism and venous embolism is feared to be the main issue. These procedures can be performed after thermal ablation technique to stabilize the bone in case of impending fracture and these combination of procedures is widely being used with a palliative intent to treat painful bone metastases. [29]

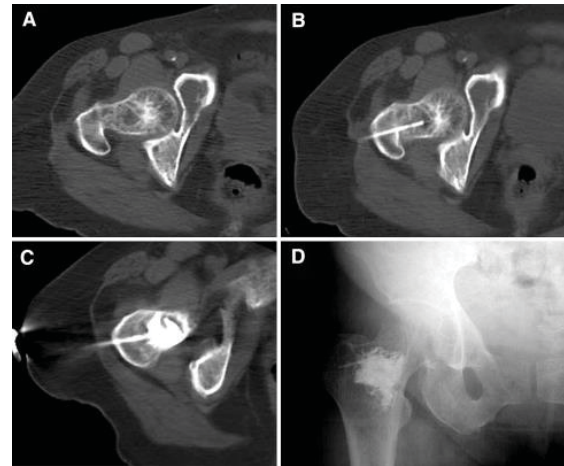


Fig.4. A) CT scan shows lytic lesion in the femoral neck B) Electrode in place C) CT scan during cementation D) Image after ablation and cementation [6]

2.3 Transcatheter Arterial Embolization

Transcatheter arterial embolization (TAE) procedure is used to treat hypervascular bone tumour which pose risk of excessive bleeding during any procedure. X-ray fluoroscopy is used for image guidance and angiograph is performed to study the nature of the vessels feeding the tumour. Artery is catheterized. Catheter is selected based on the size of the vessel and can vary from 4-6F catheter. Microcatheter of 2.7F is inserted coaxially through the larger catheter to reduce the risk of false embolization. [25] Selective embolization agents can be delivered to occlude the vessels. Permanent solid particles like polyvinyl alcohol (PVA) is used to block arteries supplying the tumour and temporary solid particles like gelfoam is used to block proximal feeding arteries. Generally only conscious sedation is used during the procedure, but in case of patients with severe unbearable pain general anaesthesia may be required. A study was

conducted by Kassamali RH et al on 33 patients with bone metastases. They were treated with TAE, TAE combined with radiotherapy and radiotherapy alone. Study showed that TAE alone resulted in immediate pain relief. However 75% of these patients experienced symptomatic reoccurrence in comparison to 20% of those who were treated with combined TAE and radiotherapy. [24] Preoperative transcatheter arterial embolization can be performed in combination with other treatment thereby reducing the risk of bleeding from the tumour site. [3] [25]

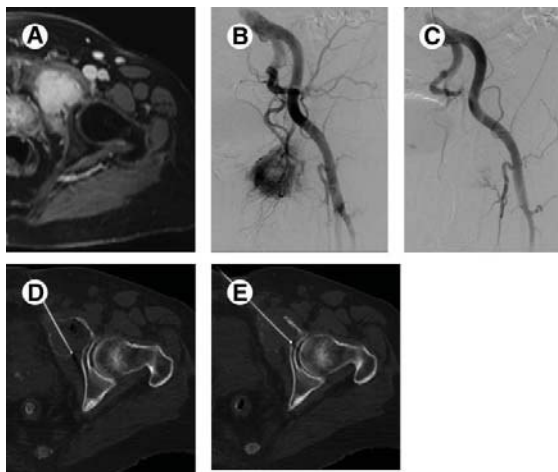


Fig.5. A) MR image shows hypervascular metastases of the left pubic ramus B) Angiogram of the common iliac artery shows hypervascular mass supplied by the obturator branch of the internal iliac artery C) Post TAE angiogram of the common iliac artery showing D) and E) Axial, non-contrast enhanced CT images showing RFA [8]

3. FUTURE OUTLOOK

Research is on progress to aid the development of more effective treatment for cancer in the future and interventions have a major role in it. Several procedures are currently in research phase which deals with innovative approach to betterment of cancer management.

3.1 Magnetic Chemotherapy

Magnetic nanoparticle, which acts as an intermediate of heat is combined with cancer killing drugs in the same nanoformulation which can be used for the application of hyperthermia in combination with chemotherapy. This is can be used as an effective tool in the treatment of cancer. The blood vessels feeding the tumour is infused with the combination of drug-magnetic nanoparticles with the help of a catheter. A

patient is positioned with the tumour site directly under the presence of a rare earth magnet so that the magnet attracts the combination of drug-magnetic nanoparticles out from the blood vessels and lodge them on to the tumour. This helps in achieving localised treatment of the cancer while avoiding damages to the healthy tissue and other symptoms as in the case of conventional chemotherapy. [27]

3.2 Gene therapy

Gene therapy is an essential tool of the future which is expected to provide new innovative approach to the treatment of cancer which aids the survival of cancer patients. Patient's immune system can be altered with cancer killing genes in vitro and can be returned to the body where they can fight cancer more effectively. Or a cancer cell itself is removed from the patient and is altered genetically in such a way that the patient's immune system holds a strong defence mechanism against it. In this case genetically altered cells acts as a cancer vaccine. Another way of approach would be to introduce a gene in to the tumour which makes them more vulnerable to chemotherapy and other cancer killing agents and making bone marrow and other organs resilient to chemotherapy. With the variety of approaches available in gene therapy, introducing the genetically altered cells is an issue. Interventions play a vital role to overcome this obstacle with the help of image guidance to guide catheters and other tools. Gene therapy even though in its early blooming stage, creates a hope that an effective treatment of cancer can be achieved in the near future. [28]

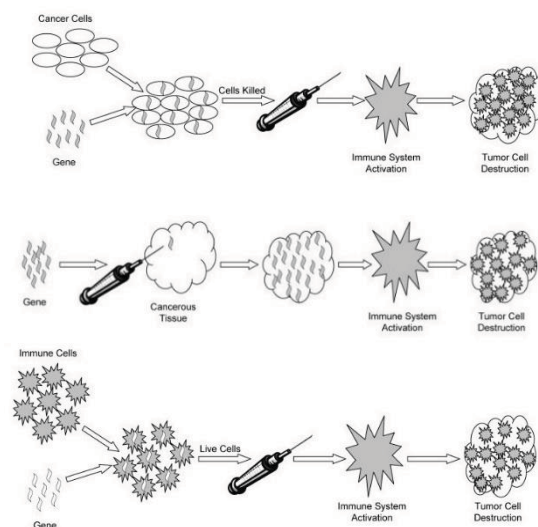


Fig.6. Different approaches of gene therapy [28]

4. CONCLUSION

Due to the ongoing evolution in the treatment methods of cancer, the survival rate of the patients suffering from bone metastases is increasing. A variety of treatment options are available but the selection criteria should be based on the nature of the disease and the systemic condition of the patient. Minimally invasive procedures have gained recognition and are being preferred over conventional methods due to its advantages like high efficacy, fast recovery time, lower rate of trauma and minimal risk of complications. In case of benign tumours its use for curative purpose however it is mostly intend for the palliative treatment for painful bone metastases. [23]

The primary goal of palliative treatment of painful bone metastases is the symptomatic pain relief which is achieved by ablating the interface between the tumour and pain sensitive periosteum. RFA is most commonly used thermal ablative technique for treatment of bone cancer. Cryoablation can also be performed which shows the similar result and offers advantages like using low temperatures to ablate the tumour and the ability to monitor the ice ball formation with help of image guidance like CT or MR imaging to avoid damage to tissue present in the vicinity. [13] Other thermal ablation technique microwave ablation, laser ablation and HIFU also shows significant reduction in pain and improve the quality of life. Bone consolidation in case of weight bearing bone may be necessary which can be achieved by cementoplasty. It is a quick, cost-effective procedure that can be performed in combination with other procedures. Preoperative Transcatheter arterial embolization can also be performed in combination to avoid excessive bleeding from the tumour site where hypervascular structures are concerned.

A better understanding of available procedure is necessary to obtain the optimum results. Collaboration of different treatments is often required for complex cases, but preference should always be given to one with the lower risk of complication. Also, knowledge about thermal protection techniques is necessary to avoid complications when performing thermal ablation in the vicinity of the neural structures.

With the evolution of new techniques like magnetic chemotherapy and gene therapy at the horizon, there is a possibility for developing new treatment methods to cure or improve the quality of life of people suffering from the dreadful disease, so called cancer.

REFERENCES

- [1] Dr, Roger Henderson; Primary bone cancer; <http://patient.info/health/primary-bone-cancer>
- [2] Macmillan Cancer Support (2014); What are primary and secondary cancers; <http://www.macmillan.org.uk/cancerinformation/cancertypes/unknownprimary/aboutcup/primarysecondarycancers.aspx>
- [3] Alda Tam,MD et al; Palliative Interventions for Pain in Cancer Patients; *Semin Intervent Radiol.* 2007 Dec; 24(4): 419–429, DOI: 10.1055/s-2007-992330
- [4] Hyun Guy Kang et al; Minimally invasive surgery for metastatic bone tumour; *Tumor Metastasis*; Spetember 2016; DOI: 10.5772/64341
- [5] American cancer society (2014); If treatment for bone cancer stops working; <http://www.cancer.org/cancer/bonecancer/detailguide/bone-cancer-after-no-longer-working>
- [6] Fernando Ruiz Santiago et al; Treatment of bone tumours by radiofrequency thermal ablation; *Curr Rev Musculoskelet Med.* 2009 March; DOI: 10.17925/EOH.2008.04.2.92
- [7] Meena bedi et al; Minimally Invasive Local Treatments for Bone and Pulmonary Metastases; *Minim Invasive Surg.* 2014; 2014: 719394; DOI: 10.1155/2014/719394
- [8] Javier Nazario, MD et al; Thermal Ablation of Painful Bone Metastases; *Techniques in Vascular and Interventional Radiology*, Volume 14, Issue 3, September 2011; DOI: 10.1053/j.tvir.2011.02.007.
- [9] Christopher L. Brace, PhD, Assistant Scientist; Radiofrequency and microwave ablation of the liver, lung, kidney and bone: What are the differences; *Curr Probl Diagn Radiol.* 2009 May–Jun; 38(3): 135–143. DOI: 10.1067/j.cpradiol.2007.10.001#
- [10] A. Nicholas Kurup et al, MD; Image-Guided Percutaneous Ablation of Bone and Soft Tissue Tumors; *Semin Intervent Radiol.* 2010 Sep; 27(3): 276–284; DOI: 10.1055/s-0030-1261786
- [11] Matthew R. Callstrom et al; Image-guided ablation of painful metastatic bone tumors: a new and effective approach to a difficult problem; *Skeletal Radiology*, 2006 Jan; 35(1):1–15; DOI: 10.1007/s00256-005-0003-2
- [12] Peter S. Rose et al; Cryosurgery/cryoablation in musculoskeletal neoplasms: history and state of the art; *Curr Rev Musculoskelet Med.* 2015 Dec; 8(4): 353–360; DOI: 10.1007/s12178-015-9307-6

- [13] Afshin Gangi, MD, PhD et al; Percutaneous Bone Tumor Management; *Semin Intervent Radiol.* 2010 Jun; 27(2): 124–136; DOI: 10.1055/s-0030-1253511
- [14] Matthew R. Callstrom MD PhD et al; Percutaneous image-guided cryoablation of painful metastases involving bone; 2012 oct12; DOI: 10.1002/cncr.27793
- [15] Caroline J. Simon, MD et al; Microwave Ablation: Principles and Applications; *Radiographics.* 2005 Oct; 25 Suppl 1:S69-83; DOI:10.1148/rg.25si055501
- [16] Evanthia Botsa et al; CT image guided thermal ablation techniques for palliation of painful bone metastases; *Ann Palliat Med.* 2014 Apr;3(2):47-53; DOI: 10.3978/j.issn.2224-5820.2014.04.02
- [17] Claudio Pusceddu MD et al; Treatment of Bone Metastases with Microwave Thermal Ablation; *Journal of Vascular and Interventional Radiology,* 2013 Feb;24(2):229-233; DOI: 10.1016/j.jvir.2012.10.009. Epub 2012 Nov 30
- [18] Bernhard Gebauer, Per-Ulf Tunn; Minimally Invasive Tumor therapies; *Thermal Ablation in Bone Tumors;* http://link.springer.com/chapter/10.1007%2F3-540-28137-1_10#page-1
- [19] Kamran Ahrar, MD et al; Magnetic Resonance Imaging–Guided Laser Ablation of Bone Tumors; *Tech Vasc Interv Radiol.* 2011 Sep;14(3):177-82; DOI: 10.1053/j.tvir.2011.02.010
- [20] Stanford School of medicine; Treatment of Painful Bone Metastases; <https://bodymri.stanford.edu/TreatmentofPainfulBoneMetastases#>
- [21] Boaz Liberman et al; Pain Palliation in Patients with Bone Metastases Using MR-Guided Focused Ultrasound Surgery: A Multicenter Study; *Ann Surg Oncol* (2009) 16: 140; DOI:10.1245/s10434-008-0011-2
- [22] Chuanxing Li MD et al; Noninvasive treatment of malignant bone tumors using high-intensity focused ultrasound; *Cancer.* 2010 Aug 15;116(16):3934-42; DOI: 10.1002/cncr.25192.
- [23] Xuefeng Liu et al; Advances in the clinical research of the minimally invasive treatment for the posterior edge of vertebral-body defects by spinal metastases; *Biomed Rep.* 2015 Sep; 3(5): 621–625; DOI: 10.3892/br.2015.483
- [24] Kassamali RH et al; Pain management in spinal metastases: the role of percutaneous vertebral augmentation; *Ann Oncol.* 2011 Apr;22(4):782-6; DOI: 10.1093/annonc/mdq605. Epub 2010 Oct 21
- [25] Pankaj Gupta et al; Preoperative transarterial Embolisation in bone tumors; *World J Radiol.* 2012 May 28; 4(5): 186–192; DOI: 10.4329/wjr.v4.i5.186
- [26] Akihiro Uemura et al; Transcatheter arterial embolization for bone metastases from hepatocellular carcinoma; *Radiol* (2001) 11: 1457; DOI:10.1007/s003300000792
- [27] Aziliz Hervault et al; Magnetic nanoparticle-based therapeutic agents for thermo-chemotherapy treatment of cancer; *Nanoscale.* 2014 Oct; 6(20):11553-73; DOI: 10.1039/c4nr03482a
- [28] Deanna Cross, PhD et al; Gene Therapy for Cancer Treatment: Past, Present and Future; *Clin Med Res.* 2006 Sep; 4(3): 218–227
- [29] Huy M. Do, MD; Vertebroplasty Procedures; *Spine health;* <http://www.spine-health.com/treatment/back-surgery/vertebroplasty-procedure>
- [30] Alessandro Napoli, MD, PHD; INSIGHTECH; Insightech for oncology; <http://www.insightec.com/us/clinical/oncology>



“Exponential technologies in Healthcare – Possible impact on Future”

Mahurshi Parikh, Medical Systems Engineering, Otto-von-Guericke Universität, Magdeburg. mahurshi.parikh@st.ovgu.de

Introduction

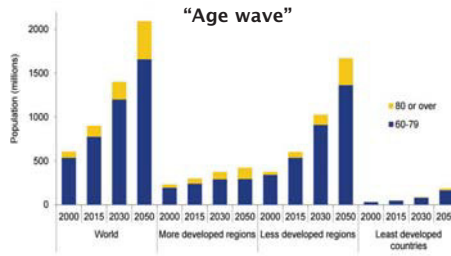
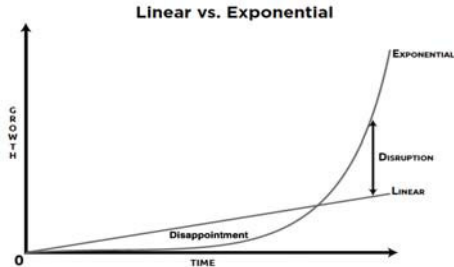
Exponential Technologies: “Technologies that doubles in power or processing speed every year, while their cost halves.”

Why?

- Upcoming age wave
- Increase the quality, effectiveness and efficiency

How?

- With disruptive technologies such as:
- Artificial Intelligence (AI)
 - Wearable Sensors and systems
 - Robotics
 - 3D Printing
 - mHealth
 - Diagnostic Scanner

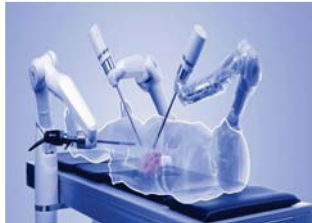

The success of medicine is based on above mentioned technology driven innovation. In the past few decades we have increasingly seen breakthrough improvements in medicine that were induced or supported by new technologies, and that were unthinkable without them, leading to better and often revolutionary new ways to detect or solve health problems.

Exponential Technologies

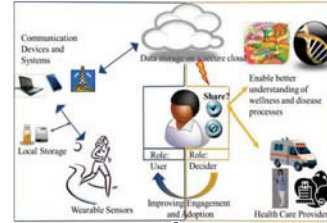
Computer system performs tasks without instructions from Humans for:

- Diagnosis
- Classify future data
- Generating alerts
- Therapy planning
- Image recognition



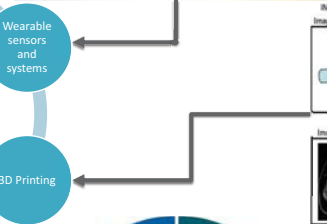
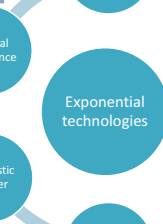
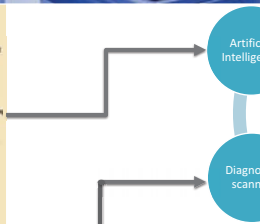
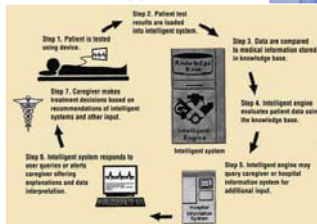
Reprogrammable Machines:

- Patient safety
- Rehabilitation
- Assistance



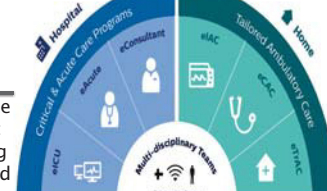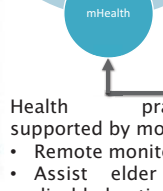
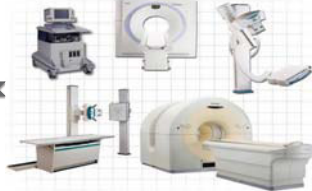Shift of “Hospital centred Healthcare” to “Patient centred Healthcare”:

- Real time processing
- Alert medical team
- Monitor symptoms
- Assess outcomes of interventions



Redesigning of major traditional procedures:

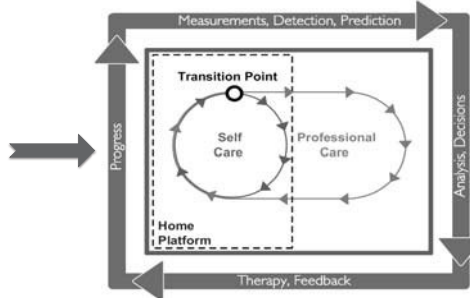
- Speed
- Resolution
- Access to imaging data



Future Trends and Challenges

Future trends:

- Concentration on prevention
- Assess of risk profile
- Integration of technologies for accurate diagnosis
- Local drug delivery
- Cheap transplant
- Developing country and third world country oriented healthcare system
- General care to personal care
- Home care centre for elderly people
- Improve patient outcomes at lower overall cost



Future challenges:

- **Security:** Confidential and sensitive patient health data
- **Data privacy and regulation:** Data protection and legislation differs greatly between countries
- **Simple user experience:** The technology needs to be user friendly and fit seamlessly into familiar workflows
- **High performance and High quality solutions:** Performance and quality of service are essential for launching new solutions

Conclusion

This poster has just touched up on some important new trends in healthcare technology which is showing exponential trends. Each of these new technologies is developed to bring more comfort to the patient and improve the efficiency and cost of diagnostics and treatment. Informatics has made a big impact on healthcare over the last decade and will continue to do so. Telemedicine, wearable-sensors and 3D Printing will shift the medical care to personalized care, while Artificial intelligence, Robotics and Diagnostic scanner development will offer better and faster diagnosis whilst lowering cost. Although, there are some challenges with these developments, the future will be bright as exponential technology is coming in sight.

References

[1] World Population Ageing Report (2015) Economic and social affairs, United Nations, http://www.un.org/en/development/desa/population/publications/pdf/ageing/WPA2015_Report.pdf
 [2] Cemal H. Guvercin (2015) The general structure of an AI application in medicine, Ethical Issues in Artificial Intelligence Applied to Medicine Presentation to MedRes 5th World Congress.
 [3] Mary M. Rodgers, Vinay Pai, Richard N. Conroy (2014) Recent Advances in Wearable Sensors for Health Monitoring, in IEEE Sensor Journal 2014, DOI: 10.1109/JSEN.2014.2357257
 [4] F. Rengier, A. Mehndiratta, H. von Tengg-Koblik et al. (2010). 3D printing based on imaging data: review of medical applications, CARS, pp 335-340, DOI 10.1007/s11548-010-0476-x
 [5] PHILIPS iCUI Program Telehealth for intensive care unit. Clinical Transformation in the ICU: saving lives and reducing costs
 [6] Robert Gossink and Jacques Souquet (2006) Advances in Healthcare Technology Shaping the Future of Medical Care, Phillips research book series Volume 6, pp 1-14, Springer Netherlands, DOI 10.1007/1-4020-4384-8_1
 [7] Meeta Dash (2016) Key technology challenges for the Healthcare Industry, TokBox blog, Healthcare industry news

Exponential Technologies in Healthcare

Possible Impact on Future

Review Paper – Image Guided Surgery

Mahurshi Parikh

Medical Systems Engineering,
Fakultät für Elektrotechnik und Informationstechnik,
Otto-von-Guericke Universität, Magdeburg
mahurshi.parikh@st.ovgu.de

Abstract— Exponential technologies are making its way in Healthcare since past few years. This disruption and transformation is bringing innovation which can change entirely healthcare system. While these innovations have produced some stunning results, they have been relatively narrowly focused and mostly incremental in nature. We are in the middle of a medical revolution driven by exponential technology: Artificial Intelligence (AI), Sensors, Robotics, 3D Printing, mHealth and Diagnostic Scanners. This review paper is mainly focused on exponential technology advancement of healthcare in recent years and outcome in upcoming years. It is important to promote technology development because some of developing countries as well as third world countries are facing problem with delivering some of basic medical care. So, the future of exponential technology in the medical will be promptly very useful to make the world to access basic needs. On the other hand, Challenges like security, privacy and high quality delivery to this new innovation is a critical issue. However, the future of healthcare is ready to make changes with considering challenges within technological innovations.

Keywords—Exponential technology; Artificial Intelligence; Robotics; Wearable sensors; mHealth; Diagnostic Scanner

1. INTRODUCTION

Staying healthy and getting appropriate medical care is certainly one of the most important issues in our society. In a certain way, enormous investments are made to improve the delivery of the health management system. Among the different ways to optimize healthcare, technology plays an important role. As a human being we thinks linearly in terms of what we experience, that is how our minds are wired. “Thirty linear steps is thirty steps, but thirty exponential steps is a billion” [1]. So, some of medical technologies are/will accelerating to exponential rate. It will not only help to increase the quality, effectiveness and efficiency of health related procedures,

but it will enable new ways to practice medicine. In the coming years, the so-called ‘age wave’ (Fig 1) will also magnify the problem, if no solutions to reducing incidence or costs are found. Apparently, the success of medicine is to a large extent based on technology driven innovation. In the past few decades we have increasingly seen breakthrough improvements in medicine that were induced or supported by new technologies, and that were unthinkable without them, leading to better and often revolutionary new ways to detect or solve health problems.

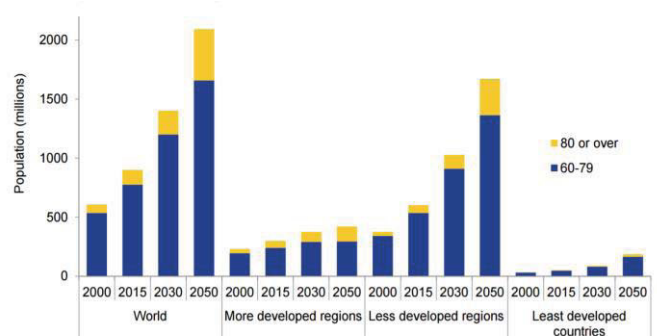


Fig 1 Population aged 60 -79 years and aged 80 or over by development group, 2000, 2015, 2030, 2050 [23].

The concept of AI in medicine has enable the capacity to store and process data in an intelligent manner, and translate that information into functional tools. Advances in imaging technology, with the invention of computed tomography (CT) or magnetic resonance imaging (MRI) about three decades ago, have certainly marked disruptive change for many procedures in diagnosis and therapy. Smart sensors are for accurate detections and early warning of health conditions for users in interactions with different living scenario. Upcoming future in healthcare, with Robotics in surgery

room and rehabilitation center, can lead us into new frontier. 3D printing, also known as additive manufacturing, provides the freedom to produce custom-made medical products and equipment. mHealth is becoming a popular option in underserved areas where there is a large population and widespread mobile phone usage. Which can be helpful in developing countries, where physicians cannot be accessed easily.

With all the benefits of innovations in healthcare, risks also come with along it. A group of experts discuss what those dangers are and how to deal with them. Despite these risks, it seems the healthcare industry has accepted the fact that technological reformation is coming. In order to prepare and remain as safe as possible, there are steps that providers and manufacturers can take. It is the general intention of this paper to present a collection of innovative and valuable contributions to healthcare technology that can grow exponentially. The topics were selected to cover different application areas ranging from hospital to home, and to create different views on how technology influences critical aspects of patient care.

2. EXPONENTIAL TECHNOLOGIES IN HEALTHCARE

“Technologies that doubles in power or processing speed every year, while their cost halves.” Fig 2 shows how the exponential growth disrupt in accordance with time.

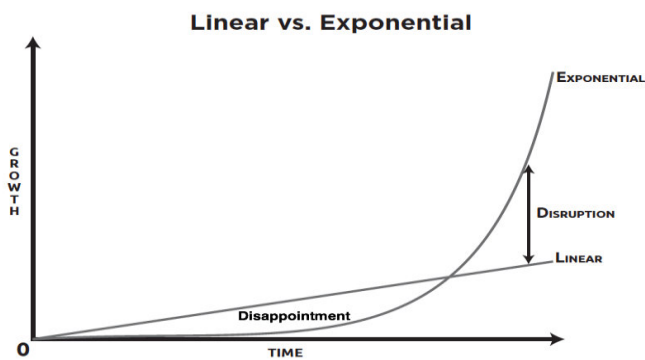


Fig 2 Linear vs. Exponential growth

Some of the exponential technologies in healthcare that are showing their way of development are discussed further in a broad way:

2.1 ARTIFICIAL INTELLIGENCE:

Artificial Intelligence is defined as the science and engineering of creating intelligent computer systems that are able to perform tasks without receiving instructions directly from humans. AI can support a wide

range of applications and services including automated diagnosis, personalized medicine, patient monitoring, location based medical services, emergency response and management, access to medical data, and home monitoring. The objective of computer-assisted decision making in medicine aims to allow the medical experts to use the computer as a tool in the decision process. In general, the term intelligent electronic healthcare systems refers to automated systems that process medical data such as clinical examination or medical images and provide estimated diagnoses. The estimations are often based on the analysis of details that avoid the human visibility as well as large amounts of medical history that humans cannot possibly consider or analyzing non-visual characteristics of medical data. Although such systems typically do not reach 100% success, which means that they cannot substitute the working physician. However, IBM Watson is a one of its kind of example. Many scientist and researchers believe that it will redesign the healthcare system [4]. Fig 2 describes the example of use of AI in the fully integrated medical system to improve the delivery of services.

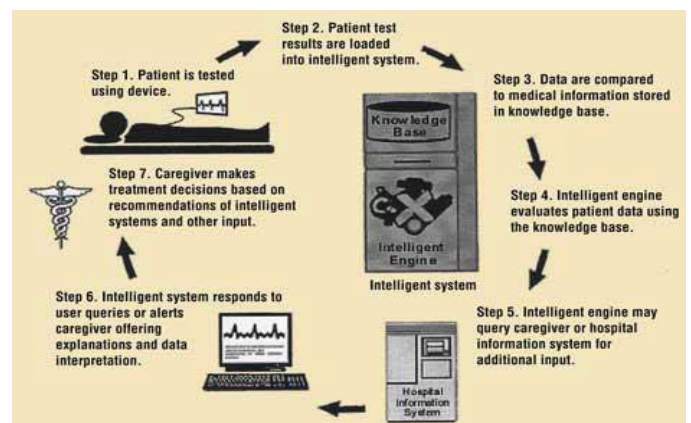


Fig. 2 A fully integrated medical AI application [3]

The most examinations or important processes in the development and operation of Medical Decision Support Systems are (i) the Acquisition of information regarding the diagnosis classes and (ii) the actual classification of a given case to a diagnosis. The two steps are actually closely related to each other, as the type of classifier chosen in most cases also indicates the training methodology to use [2]. The most well-known and widely applied approaches can be briefly summarized and categorized as follows:

- The examined case is compared directly to other cases and similarities are used in order to provide a most probable diagnosis.
- Different types of classifiers are trained based on available health records, so that the underlying data

patterns are automatically identified and utilized in order to provide more reliable classification of future data.

- Information extracted automatically from medical history, or provided manually by human experts, is organized so that diagnosis estimation is provided in a dialogical manner through a series of question/answer sessions.
- Multiple simple classifiers are combined in order to minimize the error margin.
- Information provide by human experts in the form of simple rules is utilized by a fuzzy systems in order to evaluate the case in hand.

In conclusion, there are various use of AI in clinician practice such as: Generating alerts and reminders, Diagnostic assistance, Therapy critiquing and planning, Image recognitions and interpretation, which can help to improve the future assistance for patients as well as for physicians.

2.2 WEARABLE SENSORS AND SYSTEMS:

The increase of aging population, the shift from the classical “hospital centered healthcare” to “patient centered health,” and the remarkable advances in science and technology has started an evolution in personalized biomedical devices for healthcare applications. A personalized biomedical device is typically wearable, portable, implantable, or swallowable based on the need for individual patients. Personal biomedical devices can be divided into two major categories: non-intrusive and intrusive. Nonintrusive devices normally fit onto the patient body with some additional outfit. Intrusive devices are those going into the body that may stay for certain duration [6]. It will help the delivering of healthcare services to the patient in a timely, precise and cost-effective manner. The types of devices, just to name a few, range from sensors, robotic sensing systems, and haptic devices.

There are many research prototype and commercial products available in healthcare. The typical example includes smart watches like Apple watch series 2 and Moto 360, Tech Fabric like Samsung smart clothing which monitors biometric data, Fitness and health trackers like Fitbit Charge 2 and Garmin Vivosmart HR for automatic activity and sleep tracking etc [7]. In general, wearable sensors and systems takes the following main functions in terms of health monitoring:

- To measure a real-time bio-signal for local processing,
- To alert the medical emergency system if vital signs drop below certain threshold,

- Monitoring symptoms to facilitate medication measurement,
- Assessing the outcomes of therapeutic interventions for maximize patient benefits.

2.2.1 WEARABLE SENSORS:

Sensor gathers data from the wearer and pass on the information to a processing unit. The design of sensors to detect wearer’s motion and the sense of touching works on the basic principle of mechatronics. Fig 3 shows the sensors with passive monitoring, interfacing it with local input and communication networks can be beneficial for connecting the wearer [8]. One area of great promise is the integration of diagnostic and therapeutic systems into theranostic devices. Recently a multifunctional wearable device has been developed that records muscle activity and is integrated with a controlled transdermal delivery system for releasing nanoparticles [9].

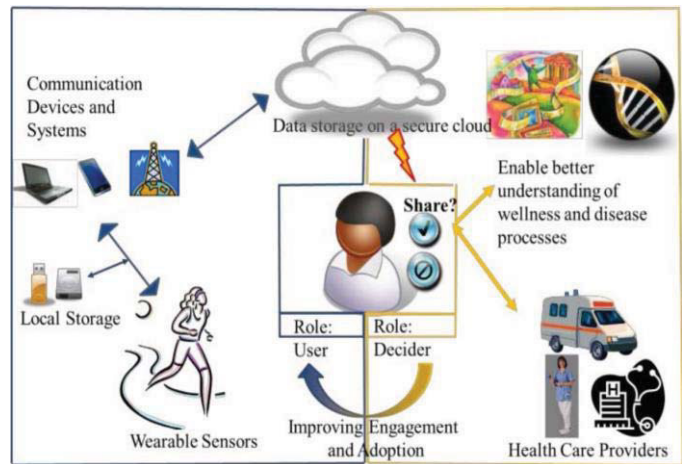


Fig 3. The view of wearable sensor’s role in healthcare [8]

2.2.2 WEARABLE HAPTIC DEVICES:

On the medical front, wearable haptic devices have tremendous impact as a tool in assisting rehabilitations. Markow et al. [10] put forward an interesting system as the Mobile Music Touch (MMT) for hand rehabilitation. It is a lightweight, wireless haptic glove design for passive haptic learning. Preliminary tests show that the system is capable of assessing the improvement in patients with tetraplegia. Tele-rehabilitation is much needed for post-stroke patients where they can perform exercises at the comfort of their home.

2.2.3 INGESTIBLE MEDICAL CAPSULE:

These devices could be swallowed by patient and offer non-invasive alternatives compared to traditional endoscopy or surgery for diagnosis or treatment of gastrointestinal disorders. Wireless capsule endoscope is a good example of such devices. The future advancement of wireless capsule can replace traditional procedures by active locomotion, body fluids/tissue sampling, and drug delivery.

2.3 ROBOTICS:

The definition of Robot is as a “Reprogrammable machine”, Researchers predicted that it will replace human workers in near future and next application of robots is medical and healthcare field. Nowadays, surgery is changing its way of conventional way to minimally invasive procedures, which provides fast recovery, low risk of pain and infection, and less psychological pressure, and hence are used widely in various field of medical. However, the technique is more difficult due to limited working space, the difficulty of using image-guide equipment as CT and MRI in interventional procedures and require much more time and effort to achieve relevant skill for doctors. Robotics can provide solutions for these limitations as well as manual procedure through integration of electromechanical devices. For example the Da Vinci surgical system by Intuitive Surgical in the U.S., which is a predominantly used system at present, is a laparoscopic surgical robot with 7 degrees of freedom, and allows the doctors to perform detailed laparoscopic surgery through dexterous movements of surgical instruments with high degree of freedom and stereo endoscope system with high resolution [11].

Fig 4 shows different categories and important keywords relating to Medical Robots [12]. Therefore, Robotics systems can effectively facilitate the procedure augmenting the dexterity and more accurate medical imaging information handling for the clinician. On the basis of categories the Robots can be explained as follows:

1) Robotics for patient safety

As mentioned above, due to difficulties related to minimally invasive surgery, Robotics can help a lot in healthcare. Medical simulation with robotics can make patient safety up to its level because in surgery the sense of the touch has been reduces. Researchers and medical simulation industries working on the development of versatile force feedback, cost effective tactile feedback etc., which can make the upcoming future of the Robotics very reliable. On other hand, despite the Success of Da Vinci, there are many procedures awaiting advanced

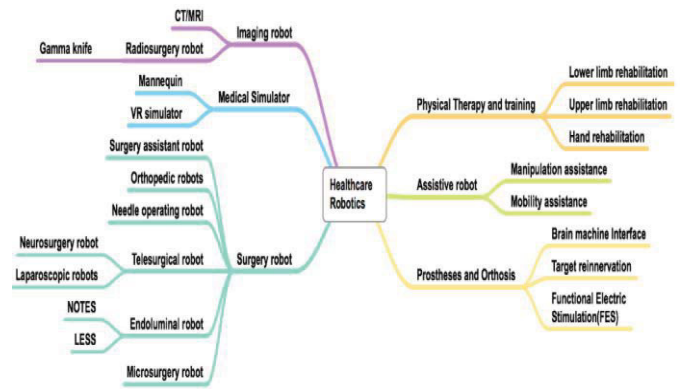


Fig 4 Major categories of Healthcare Robots [12]

technologies. This development will change the future of the hospitals as well as operating rooms.

2) Rehabilitation and Assistive Robots

To meet the demands of aging society, number of therapist is less compared to patients. Robotic rehabilitation is expected to support a therapist, allowing more intensive and repetitive training, and to assess patient’s recovery quantitatively, measuring changes in movement kinematics and forces. Many kinds of robotic rehabilitation systems have been developed but not clinically evaluated thoroughly.

Thus, aging society which would be a big part of population in upcoming future, will be benefited by this technologies to overcome the shortage of clinicians and therapists.

2.4 3D PRINTING:

Personalized and precision medicine is the future of the current medical innovations. 3D printing or rapid prototyping has intersected both medicine to enable both purposes. Today image guided surgeries become integrated in a therapeutic team together with different surgical specialist. However, we are limited by the use of flat screens for the visualization of three-dimensional imaging data. An emerging technique, referred to as 3D printing or rapid prototyping, overcomes this limitation by producing three-dimensional objects [14].

2.4.1 GENERATION OF 3D OBJECTS

Source data acquired from an imaging modality which is visualized in two dimensions. With post processing tools and algorithms, it is possible to produce multiplanar reformations and three-dimensional views of the anatomy. The process chain involved from image acquisition to production of a three-dimensional rapid prototype model consists of three steps: “Image

acquisition”, “Image post-processing” and “3D printing” [15].

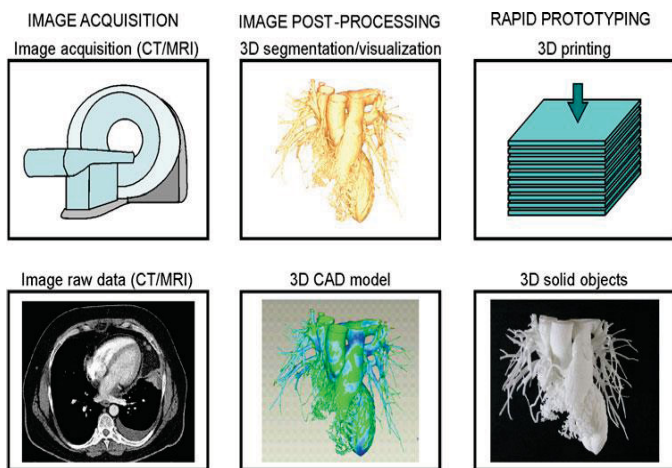


Fig 5 The process chain involved from image acquisition to production of a rapid prototype model [15]

2.4.2 MEDICAL APPLICATION 3D OBJECTS:

In last decades, rapid prototyping has been used in a variety of medical application like individual patient care in surgical planning, implant and tissue designing, medical research and medical education and training. Nowadays, FDA approved drug manufacturing using 3D printing technology for epilepsy by APRECIA pharmaceuticals is available in the US [16].

With help of 3D printed objects, we can reduce operation time, cost of tissue or organ implants, and increase the availability of simple organs like kidneys, ear with increased capability compare to natural organ or tissue. Although, the main advantage stated by many authors are reduced surgery time, improved outcomes, less radiation exposure and handle complex surgeries with less experienced surgeons [17]. The breakthrough of rapid prototype will change the future for patients with disabilities due to organ malfunction.

2.5 mHEALTH (TELEMEDICINE):

Information technology is integral to people’s life deeply, and will be evolving and expanding continuously. People who are unable to go to the hospital to see doctors could also enjoy healthcare with medical service at home by taking advantage of the technology. With remote monitoring devices and wireless sensor networks, doctors and carers can check the status of patients at anytime, anywhere. Information technology has certainly advanced healthcare systems in the way that patient data is stored and retrieved. As a result, health information services on administration including paperwork and workload of health professionals have been largely reduced [25].

It is challenging to ensure the delivery of healthcare services to everyone who needs the service, especially people who live in remote and rural regions. Many research projects are ongoing, especially in developing countries such as Iran and Malaysia, with an aim to extend healthcare systems to rural areas away from modern cities. Telemedicine and telemonitoring technology is not only used to help in emergency situations, but also with patients who have chronic diseases. When patients are unwell to travel but do need medical services, telemedicine provides great advantages to them. Some patients, especially the elderly, feel more comfortable to stay at home rather than hospital. Telemonitoring can then provide health services to them. The state-of-the-art applications used in telemedicine and the systems that are designed for telemedicine, such as smart home or remote monitoring using robots, smart phones, or wireless sensors that can be placed in the patient’s home. Fig 6 shows the future of the telehealth for patients for intensive care [18].

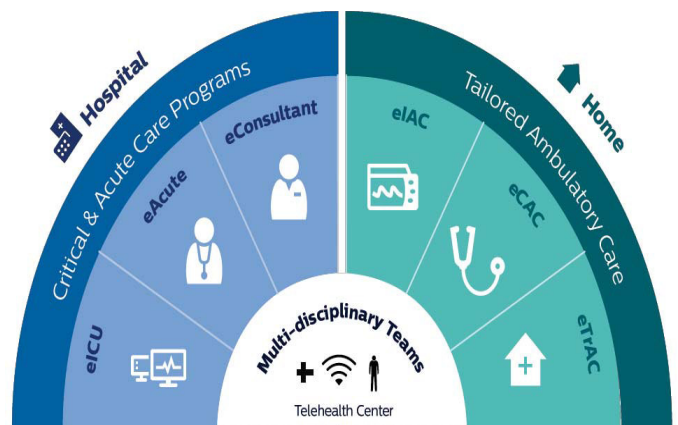


Fig 6 The future of Telehealth interconnected with hospital to home for intensive care [18]

With special applications, smart phones can also be used to assist in capturing unusual sounds, for example, crying for help, or the user’s movement from one place to another to detect wandering of aged people at early stage. Researchers have pointed out role will be played by telemedicine in the future healthcare industry [24]:

- Smart systems that are designed to prevent risks associated with specific diseases (e.g. chronic illnesses).
- Develop and improve technologies that monitor and assist elderly and disabled people.
- Focus on how to manage emergency situations

In general, Telemedicine will improve health care cost, improve access to care, more productive workforce, and better patient experience.

2.6 DIAGNOSTIC SCANNER:

The power of exponential growth is more evident in computational speed as suggested by “Moore’s Law”- as predicted in 1965, computational speed doubles on an annual basis [19]. This also applied on today’s state-of-the-art CT scan, which completes scan in 30 seconds with 2400 slices in 20 GB, and in five years CT scanners would be able to obtain 1 terabyte of information per scan. We are now in the era of real-time functional MRI (fMRI), enabling researchers and new companies (like Omneuron) to delve into the brain and address issues, personalize drug regimens, enable real-time biofeedback, and show efficacy in the treatment of ailments from chronic pain to addiction [20].

Hybrid imaging, the combination of two modalities (positron emission tomography with CT scan: PET-CT), and the addition of molecular imaging has enhanced, for example, the location and qualities of a particular tumor. Increasingly improved CT scan and layered MRI reconstruction enables a resolution, not only for diagnosis but also down to the neuronal level, for understanding of normal and diseased pathways and insights into possibilities for reverse engineering neural circuitry. This convergence has led to far higher levels of precision, but also presents a challenge in terms of the ability to store, read, and interpret the images and extract in a useful way the massive amount of digitized data contained within. In addition, scanners are getting smaller and are more mobile. For example, relatively portable CT and MRI scanners down to hand-held ultrasounds (at less than a \$5K price point) entered the clinical arena [21].

The speed, resolution, and access to imaging data are now enabling the redesign of major traditional medical procedures. With the addition of artificial intelligence (AI) algorithms, a higher degree of sensitivity and specificity is being gained for the detection of pathologic lesions that may have been missed by standard radiologist reading. A Stanford University spinout called Heart Flow is leveraging image data through high-speed CT scan and cloud-based data analysis. Using computationally intensive cloud-based fluid dynamic calculations, their technology can measure and indicate to the cardiologist the rate at which blood is flowing before and after a coronary artery lesion, and determine which patients require invasive cardiac-diagnostic procedures (including placement of coronary stents) and which patients do not. This technology has the potential to save money, prevent almost half of the unnecessary angiograms performed each year, and improve patient outcomes at lower overall cost.

We could say, in the future, the diagnostic scanner will play an important role in early diagnostic of coming threats to the patients.

3. FUTURE TRENDS IN HEALTHCARE

How will medical care look like in a few decades from now? The physician and the hospital concentrate much more on prevention and aftercare, instead of having their focus on the acute phase of medical care. As the exponential technology are hitting the door of medical industry, the change in future of the healthcare is obvious. The sum of technology which are discussed in this paper will have higher impact on the revolution in the medicine.

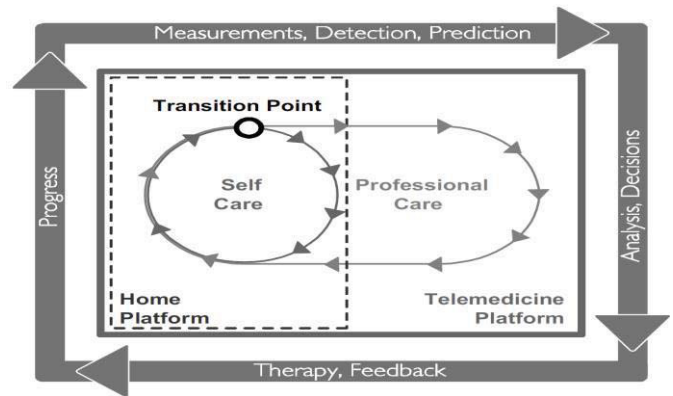


Fig 7 Interconnected technologies will shift the care from hospital platform to home platform [22]

The risk profile of the patient for acute or chronic disease is assessed by life style, family history, and genetic predictions with help of wearable sensors. All this data are stored with the help of electronic patient record. Artificial Intelligence will help to predict the data with comparing similar data from another patient and will give approximate accurate diagnosis. The patient carries this information in his/her smart card with a large memory. The patient, depending on his/her risk profile, is regularly screened for the possible onset of acute disease or to follow the course of a chronic disease. If the onset of a disease has been detected by molecular diagnosis, the extent and the location of the disease is assessed by molecular imaging using a contrast agent specifically targeted to the disease. If surgical intervention is needed, this is done using an image-guided minimal-invasive procedure by Robotics.

Pharmaceutical treatment is individually adapted to the patient in terms of the pharmaceutical. The dose in which the drug is delivered depends on a feedback system based on continuous measurement of the drug concentration at the targeted site in the body and the effect it has there. If relevant, the drug is only delivered at the

site where it is needed ('local drug delivery'), e.g. by focused ultrasound and Ingestible capsule. Patients with organ or tissue malfunction can be benefited by the innovation in 3D printing which will reduce cost to transplant of simple organs like Kidneys. Telemedicine will change the healthcare in developing countries and third world countries with the help to access to experienced surgeons. Personal healthcare systems allow elderly people with chronic disease to stay at home instead of regularly visiting or staying at a care center. This can also help to improve fitness of people like young and old people. Fig 7 shows the future shift from general care to personal care with interaction of technologies. In general, we would be able to see totally new healthcare trends in the future.

4.FUTURE CHALLENGES

There are several challenges due to new innovative technologies. Some of the challenges are discussed as below [22]:

4.1 SECURITY:

Security is a primary concern in healthcare applications since they often deal with confidential and sensitive patient health data. To build a compliant telehealth application, specific encryption algorithms and data security standards need to be followed. Additionally, service needs to be completely secure with comprehensive data protection, access control, business continuity rules and procedures in place. Even if the information is protected, the attacker may blindly modify this encrypted information turning the information into counterfeit false data and deceive the recipient into believing that they come from a different originator. Medical industry should consider these threats.

4.2 DATA PRIVACY AND REGULATION:

There are a number of privacy laws and regulations that surround patient document rights, in particular how providers share information. Inevitably, such regulatory measures put a burden on data fluidity and make it more difficult to adopt new technologies that involve data. For the communication of patient information through the communication channel should be properly secured to protect patient confidentiality. The regulations aren't just one size fits all, data protection and legislation differs greatly between countries.

4.3 SIMPLE USER EXPERIENCE:

User experience is of utmost importance when organizations are considering changing or adding new technology or working methods. This suggests that many

healthcare professionals are reluctant to change their existing methods and systems that they're accustomed to. Much like clinicians, doctors and nurses, patients have tended to be slow adopters of new healthcare services as well. In order for the medical community and their patients to use it, the technology needs to be user friendly and fit seamlessly into familiar workflows.

4.4 HIGH PERFORMANCE AND HIGH QUALITY SOLUTIONS:

Vinod Khosal, founder of Khosla Ventures, had shared his view at a conference in exponential medicine 2016 that "Nowadays death cause due to fault in medical technologies is more than the road accident in USA". So, Application performance and quality of service are essential for launching new solutions for the healthcare industry.

With the appropriate solutions to these challenges, we can make sure upcoming technologies in a more secure way, which will not improve the patient care but also make the healthcare delivery more feasible.

5.CONCLUSION

This paper has just touched up on some important new trends in healthcare technology which is showing exponential trends. Each of these new technologies is developed to bring more comfort to the patient and improve the efficiency and cost of diagnostics and treatment. Informatics has made a big impact on healthcare over the last decade and will continue to do so. Telemedicine, wearable-sensors and 3D Printing will shift the medical care to personalized care, while Artificial intelligence, Robotics and Diagnostic scanner development will offer better and faster diagnosis whilst lowering cost. Although, there are some challenges with these developments, the future will be bright as exponential technology is coming in sight.

REFERENCES

- [1] Technologies of Transcendence at Singularity University, Margarita Boenig Liptsin and J. Benjamin Hurlbut.
- [2] Introducing Intelligence in Electronic Healthcare Systems: State of the Art and Future Trends, Ilias Maglogiannis, University of Central Greece, Papasiopoulou 2-4, PC 35100 Lamia, Greece, IFIP International Federation for Information Processing 2009
- [3] http://www.angelfire.com/ks2/kaz/ai_medicine/timeline.html
- [4] <http://www.ibm.com/watson/health/>

- [5] research.healthit.techtarget.com/feature/Healthcare-IoT-security-issues-Risks-and-what-to-do-about-them
- [6] Personalized biomedical devices & systems for healthcare applications
- [7] <https://www.wearable-technologies.com/2016/12/the-top-10-best-wearables-2016/>
- [8] Recent Advances in Wearable Sensors for Health Monitoring, Mary M. Rodgers, Vinay M. Pai, and Richard S. Conroy, in IEEE Sensor Journal 2014
- [9] D. Son et al., "Multifunctional wearable devices for diagnosis and therapy of movement disorders," Nature Nanotechnol., vol. 9, pp. 397–404, Mar. 2014
- [10] Markow T, Ramakrishnan N, Huang K, Starner T, Eicholtz M, Garrett S, Profita H, Scarlata A, Backus D. Mobile music touch: vibration stimulus in hand rehabilitation. In: Proceeding of 4th International Conference on Pervasive Computing Technologies for Healthcare, 2010, 1–8
- [11] <https://forums.sufficientvelocity.com/threads/homeless-da-vinci-surgical-robot-spotted-begging-for-spare-surgeries.30368/>
- [12] Robotics for Healthcare, Jung Kim, Gwang Min Gu and Pilwon Heo, Biomedical Engineering:Frontier Research and Converging Technologies, Springer 2016, Pg 489 – 503
- [13] 3D Printing in Medicine: an introductory message from the Editor-in-Chief, Frank J. Rybicki, Springer 2015
- [14] McGurk M, Amis A, Potamianos P, Goodger N (1997) Rapid prototyping techniques for anatomical modelling in medicine. Ann R Coll Surg Engl 79:169–174
- [15] F. Rengier , A. Mehndiratta , H. von Tengg-Kobligk ,C. M. Zechmann ,R. Unterhinninghofen ,H.-U. Kauczor , F. L. Giesel, 3D printing based on imaging data: review of medical applications, CARS 2010,Pg 335-340
- [16] https://www.aprecia.com/pdf/ApreciaSPRITAMLaunchPressRelease_FINAL.PDF
- [17] 3D-printing techniques in a medical setting: a systematic literature review, Philip Tack , Jan Victor, Paul Gemmel and Lieven Annemans, BioMedical Engineering OnLine 2016 15:115
- [18] <http://www.usa.philips.com/healthcare/product/HCNOCN503/eicu-program-telehealth-for-the-intensive-care-unit>
- [19] <http://www.intel.com/content/www/us/en/silicon-innovations/moores-law-technology>
- [20] http://www.kauffmanfellows.org/journal_posts/exponential-technologies-across-health-care/
- [21] Advances in Healthcare Technology Shaping the Future of Medical Care, Gerhard Spekowius and Thomas Wendler, Phillips research book series Volume 6, Springer
- [22] <http://tokbox.com/key-technology-challenges-for-the-healthcare-industry>
- [23] http://www.un.org/en/development/desa/population/publications/pdf/ageing/WPA2015_Report.pdf
- [24] Telemedicine and Telemonitoring in Healthcare, Salmah F.A. Alsgaer, Xiaohui Tao, Ji Zhang, Hua Wang, and Zhi Guo, Springer International Publishing Switzerland 2013
- [25] Wireless Networks in Mobile Healthcare Pantea Keikhosrokiani, Nasriah Zakaria, Norlia Mustaffa, Tat-Chee Wan, Muhammad Imran Sarwar, and Keyvan Azimi, Springer International Publishing Switzerland 2015



Hybrid imaging for image guided procedures

Rajan H. Patel, in the context of the course "Instruments for Image Guides Procedures" by Prof. M. Friebe
Institute Medical Engineering, Otto-von-Guericke-University Magdeburg, Germany e-mail: rajanh.patel@outlook.com

Introduction

Hybrid Imaging
'The fusion of two or more imaging technologies into a single, new form of imaging' – "synergistic"

Why?

- Number of Image guided procedures are increasing rapidly with development of techniques and devices
- But the promise of these new procedures is realised only with the parallel developments in imaging techniques
- It requires precise and efficient navigation
- Hybrid systems that combine real-time acquisition with structural and functional data are the best suited for the navigation during IGP
- Depending on the application, different combination can be used

Two approaches

i. Software approach

- The software approach aligns two image sets after they had been acquired on different scanners at different times.
- Any two or more imaging modality data can be fused using software approach
- Problems: Misalignment, two examination

ii. Hardware approach

- The hardware approach is a combination of 2 (or more) modalities within a single device that acquires the different images either simultaneously or sequentially without moving the patient from the bed
- Minimises misalignment
- Only one examination
- Cost

Hybrid Imaging Systems

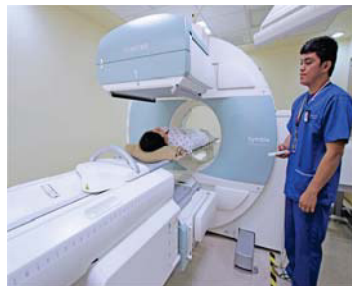SPECT/CT

Applications

- Oncology and cardiology
- Radionuclide sentinel lymph node imaging
- Monitoring brachytherapy

Challenges

- Higher cost
- Increased power requirements
- Lead shielding
- Training
- Artefacts



Siemens symbia truepoint SPECT/CT device

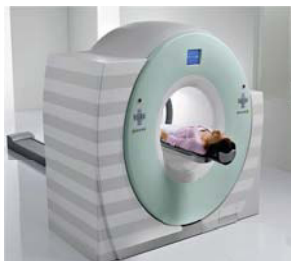PET/CT

Applications

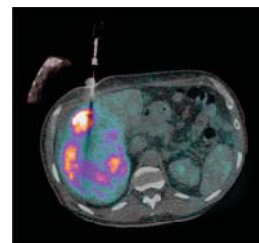
- Oncology
- Early diagnosis and staging of cancer
- Biopsy
- In patient with multiple or wide-spread tumour

Challenges

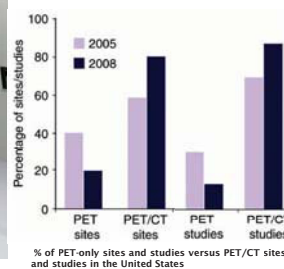
- Mis-registration
- Attenuation-correction artefact



PET/CT system with patient



PET/CT guided needle intervention into highly metabolic area inside the lesion



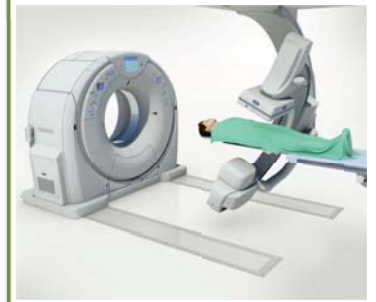CT/ANGIOGRAPHY

Applications

- Intra-arterial tumour therapy
- trans-arterial chemoembolization
- tumour ablation
- percutaneous drainage

Challenges

- Radiation dose (1.2x to 1.7x higher than c-arm CT)
- Cost
- Smaller gantry



Toshiba CT/angiography system

Outlook

SPECT/CT

- Detector technology
- Semiconductor & solid-state materials
- Cardiology camera

PET/CT

- Detectors
 - LSO (lutetium oxyorthosilicate)
 - GSO (gadolinium silicate)
- Spatial resolution
- EM needle tracking and navigation systems

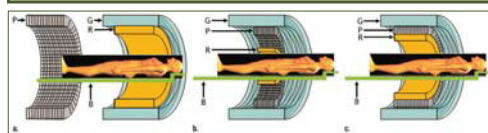
US/MRI

- B-mode and Doppler US
- Clinical 1-4MHz US transducer with 8 meter cable inside the bore of clinical 1.5T MRI scanner
- RF noise and artefacts
- Shielding the US transducer with aluminium foil
- System was tested on cryo-gel phantoms & its use has been demonstrated in rats in-vivo
- Further work is required to make tissue visible on US/MRI images
- This system shows potential as useful tool for clinical HIFU guidance and monitoring

PET/MRI

3 approaches:

- GE – 2 separate systems in separate rooms with common patient bed
- Philips – both systems are next to each other with patient bed that can be rotated 180°
- Siemens – simultaneous acquisition with single gantry system (PET detector ring inside)



Schematic cross-sectional views of potential designs for combined PET/MR imaging systems
P: PET detector
G: gradient set
B: patient bed
R: RF coil

Conclusion

Since last 2 decades, there has been constant advancement in field of imaging and interventional radiology. Hybrid systems evolved a lot since they introduced. Combination of functional and anatomical data can be very helpful during interventions. It has potential applications in image guided procedures. This technology enhances the quality of diagnostic as well as interventional imaging, which ultimately improves quality of treatment.

References

- [1] Hricak, H., Choi, B.I., Scott, A., et al. (2010). Global Trends in Hybrid Imaging, Radiology: Volume 257, Issue 2, doi:10.1148/radiol.10100579/-/DC1
- [2] Townsend, D., (2008). Dual-Modality Imaging: Combining Anatomy and Function, J Nucl Med 2008; 49:936-955, doi: 10.2967/jnumed.108.051276
- [3] Bybel, B., Brunken, R., DiFilippo, F., et al., (2008). SPECT/CT Imaging: Clinical Utility of an Emerging Technology, RSNA RadioGraphics 2008; 28:1097-1113, doi: 10.1148/rg.284075203
- [4] <https://usa.healthcare.siemens.com/molecular-imaging/xspect/symbiateries>
- [5] Kobayashi, K., Bhargava, P., Raja, S., et al., (2012). Imageguided Biopsy: What the Interventional Radiologist Needs to know about PET/CT, RadioGraphics 2012; 32:1483-1501, doi: 10.1148/rg.325115159
- [6] <http://www.klinikum-stuttgart.de/kliniken-institute-zentren/klinik-fuer-nuklearmedizin-mit-praxis-fuer-nuklearmedizin-und-molekulare-bildgebung/klinische-schwerpunkte/fdg-petct/#prettyPhoto>
- [7] Cerri, J., Huber, F., Bogoni, M., (2014). PET/CT-guided biopsy of liver lesions, Clin Transl Imaging (2014) 2:157-163, DOI 10.1007/s40336-014-0056-0
- [8] <https://medical.toshiba.com/products/angiography/inflix-44-ct/>
- [9] Jadvar, H., Colletti, P., (2014). Competitive Advantage of PET/MRI, Eur J Radiol. 2014 January; 83(1): 84-94. doi: 10.1016/j.ejrad.2013.05.028
- [10] Sherwood, V., Civile, J., Rovens, I., et al., (2014). Development of a Hybrid Magnetic Resonance and Ultrasound Imaging System, BioMed Research International Volume 2014, Article ID 914347, <http://dx.doi.org/10.1155/2014/914347>

Hybrid Imaging for Image Guided Procedures

Rajan H. Patel

Medical Systems Engineering

Faculty of Electrical Engineering and Information Technology

Otto-von-Guericke-Universität Magdeburg, Germany

rajanh.patel@outlook.com

Abstract

In last decade, there has been steep increase in the number of procedures carried out using minimally invasive approaches, as devices and techniques developed. Precise and efficient navigation of medical devices is very important for minimally invasive procedures. Hybrid systems, which combine real-time acquisition with cross-sectional and/or functional data, are the best suited for precise monitoring of interventional procedures and several such systems are available in market. Hybrid imaging techniques combine anatomical [ultrasound, computed tomography (CT), and/or magnetic resonance imaging (MRI)] and molecular [single photon emission CT(SPECT) and positron emission tomography(PET)] imaging modalities. Depending on the application, different combinations of these imaging modalities can be used for greater advantage. In this documentation, a review on Hybrid Imaging modalities, their advantages and limitations, and finally outlooks and recommendations are discussed.

Keywords

Hybrid Imaging, Image fusion, Image guided procedures, interventional radiology, SPECT/CT, PET/CT, CT/angiography, PET/MRI, US/MRI.

Abbreviations

MRI Magnetic resonance imaging, **CT** Computed tomography, **SPECT** Single photon emission computed tomography, **PET** Positron emission tomography, **US** Ultrasonography

I. INTRODUCTION

During the past century, technologies have progressed rapidly and have had an impact on medicine to an extent unseen before. Talking about the evolution in imaging modalities, the first x-ray computed tomography (CT) scanner was introduced in the early 1970s, initially for brain imaging and then later for whole body. Following CT, clinical magnetic resonance (MR) was introduced, which is an important technique because it does not require the use of ionizing radiation. These two techniques, CT and MR, are being used for the imaging of human anatomy. However, in diagnosing and staging disease or monitoring response to therapy, anatomical imaging is not enough. Functional or metabolic changes can occur without any change in anatomy. Functional imaging techniques, by using radioactive tracers and gamma camera, was introduced in late 1940s. The first human tomographic images with positron-emitting isotopes were presented in 1972, followed by the single

photon emission tomography (SPECT) a year or so later based on the work of the early 1960s.^[1]

With the development of imaging modalities and devices, number of image-guided minimal invasive procedures increased. In most of the cases, both anatomical as well as functional images are required to sufficiently diagnose the diseases and monitor the procedure. As single imaging modality can only give either anatomical or functional detail, need for using combination of two or more imaging modalities during intervention emerged. "The fusion of two or more imaging technologies into a single, new form of imaging is called 'Hybrid Imaging'." This new form of imaging is synergistic - more powerful than the sum of its parts.^[2]

Two principal approaches can be used for the image fusion: software and hardware. The software approach aligns two image sets after they had been acquired on different scanners at different times. Using software approach any two or more imaging modality data can be

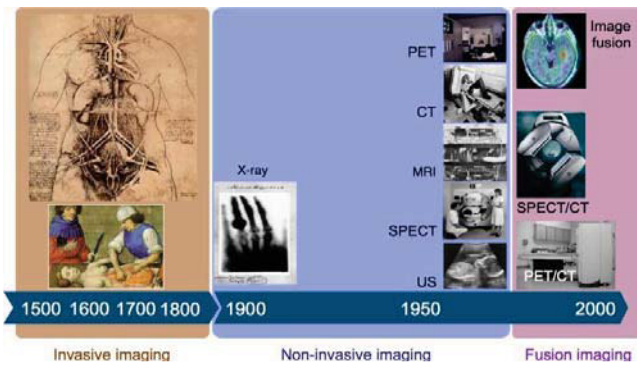


Figure 1 From invasive to non-invasive imaging. It took more than 500 years to establish non-invasive imaging from the pencil drawings of Da Vinci to routine tomographic imaging. Fifty years were needed to introduce hybrid imaging.

fused. Software approach is difficult to apply of body parts except brain because of complex alignment procedure. In contrast, hardware approach is a combination of 2 (or more) modalities within a single device that acquires the different images either simultaneously or sequentially without moving the patient from the bed. This approach eliminates differences in patient positioning and minimizes misalignment due to involuntary internal organ motion. The advantages of this hardware based hybrid imaging are diverse. First, a single examination would provide comprehensive information on the state of a disease. Here, functional information would be gathered and displayed in an anatomical context. Second, patients would be invited for only one, instead of two or multiple examinations. Third, costs for hybrid imaging devices may initially be high, but hospitals would benefit from purchasing a single device rather than two independent devices. Fourth, the combination of complementary imaging techniques can yield synergy effects for the acquisition and processing of image data. [3]

Given the rapid evolution of hybrid technology over the past decade, it is worthwhile reviewing the role of these modalities in image guided procedures and evaluating prospects. In the next sessions of this article, software approach, hardware approach including various hybrid imaging modalities with their applications in Image guided procedures, their limitations and prospects are discussed.

II. THE SOFTWARE APPROACH

The main purpose of the paper is to review Hybrid imaging modalities. But it is useful to do brief review of the Software fusion, which has been proved highly successful in some applications. In software-fusion method, two image sets are fused either by identifying

common landmarks or fiducials that can then be aligned or by optimizing a metric based on image intensity values. In either method, the complexity of the subsequent transformation is defined by the number of possible degrees of freedom between the two image volumes. [1]

Any medical image fusion methods have two main stages: (a) Image registration & (b) fusion of relevant features from the registered images. Image registration requires a method to correct the spatial misalignment between the different image data sets that often involve compensation of variability resulting from scale changes, rotations, and translations. The registration becomes difficult in the presence of inter-image noise, missing features and outliers in the images. On the other hand, the fusion of the features involves the identification and selection of the features with a focus on relevance of the features for a given clinical assessment purpose. Medical image fusion methods include Morphological Methods, Knowledge based methods, Wavelet based methods, Neural Network based methods, Fuzzy Logic based methods, and some other methods. [4] The summary of the medical image fusion methods, the modalities that these methods are applied and the applications in medical imaging studies are presented in the Table 1 in [4]. Also,

Combination	Modality 1	Modality 2	Fused Image
MRI-PET			
MRI-SPECT			
MRI-CT			
Xray-VA			
PET-CT			

Figure 2 Examples of multi-modal medical image fusion. combination of modality 1 with modality 2 using specific image fusion techniques results in improved feature visibility as shown

there are several navigation systems (EM tracking, optical tracking) which can be used during interventions based on software approach. [5]

There are wide range of applications of software-based medical image fusion in image guided procedures. The image guided brain interventions based on image fusion are Image guided neuro-surgery, Verification of implanted catheter and Brain tumor biopsy. [4] MR and x-ray are fused for these applications. [6] The image fusion applications targeted on prostate include localization of the prostate for 3D conformal radiation therapy, thermal ablation of the prostate cancer and prostate brachytherapy. MR and TRUS (trans-rectal ultrasound) can be fused for prostate biopsies. Liver is another vital organ which needs precise navigation while doing the laparoscopy on it. Fusion of CT images and Endoscopy images are done during laparoscopy. [4] Trans-catheter Structural Heart Interventions is also done using software based hybrid image-guidance. [7] Other applications of software based hybrid imaging are percutaneous nonvascular procedures, vascular procedures, and bronchoscopy. [5]

Limitations of software approach are as follows. Alignment of images acquired by 2 separate modalities on 2 different scanners is very complex procedure even if the temporal difference between scans is very small, especially when the regions of body outside the brain are involved. [3] The most difficult application of software approach is imaging of head and neck regions, where nonlinear mismatches can occur as the result of different positions of the arms or head. The abdominal and thoracic regions are also difficult to image using software approach as there is constant respiratory and bowel movements. Also, patient movements can cause difficulties in imaging. Patient must undergo into two examination instead of one. [8] A detailed review of software fusion methods can be found in [4] and [8], in which specific aspects of medical image fusion are presented with several image fusion methods and their applications.

III. HARDWARE APPROACH

In this section, three hybrid imaging modalities with their history, development, challenges and applications are discussed.

1. SPECT/CT

History and Development

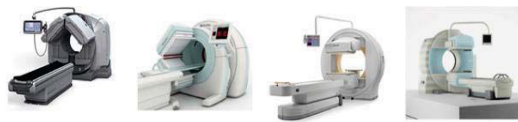In the late 1980s, researchers started developing method to combine functional and anatomical imaging in a single system. The first such system was proposed by

Mirshanov [9]. In this system, separate scintillation and semiconductor detector were used to scan the patient simultaneously with radionuclide and x-ray imaging. The resulting emission and transmission data were then recorded with a common image buffer. This system was not translated into practice, though it was the first that proposed hybrid system with which an x-ray was integrated directly to produce the transmission data as a part of functional imaging study. [10]

Another early design for hybrid imaging system was “Transmission/emission and registered imaging (TERI) computed tomography scanners” by Kaplan. [11] This work proposed simultaneous acquisition of CT transmission and SPECT emission data using imaging detectors to get maps of attenuation coefficient to compensate the SPECT data for attenuation and to maintain spatial resolution between two image data sets. [12]

The development of experimental SPECT/CT systems was started by Hasegawa et al at the University of California, San Francisco (UCSF) in the late 1980s and early 1990s. This team developed a radionuclide imaging system that incorporated a low-power x-ray generator. They used a collimated array of high-purity germanium (HPGe) detectors to record photons from both external x-ray source and the internal radionuclide distribution. The recorded photons were then processed with photon-counting electronics to differentiate the x-ray data and radionuclide data. This system proved the technical feasibility of simultaneously acquiring the x-ray and radionuclide image data using an HPGe detector array with high performance photon-counting electronics. [12]

In the mid-1990s, Hasegawa et al also developed the “modern” SPECT/CT system at USCF. In this system, the SPECT and CT sub-systems can be placed in-line for imaging and integrated with a common patient table and computer system. This group integrated a GE XR/T SPECT and GE 9800 Quick CT systems with an extended table that could be positioned for either CT or SPECT imaging without removing the patient from the system. The system design allowed the CT and SPECT data to be acquired sequentially with the CT data reconstructed in the CT scanner with a conventional filtered back-projection algorithm, then transferred to an external host computer via magnetic tape. The resultant data from reconstruction and post-processing were used to create three different image sets: the x-ray CT data; the radionuclide emission data; and a fused image with colored radionuclide data displayed over a co-registered grayscale CT image. [12,13]



	Discovery NM/CT 670 GEHC	Anyscan Mediso	Brightview-XCT Philips	Symbia Siemens
SPECT Axial FOV	40 cm	39 cm	41 cm	39 cm
SPECT Transv FOV	54 cm	53 cm	54 cm	53 cm
CT slices	16	16	cone beam	2, 6, 16
Max. coverage	20 mm	20 mm	140 mm	19 mm
CT tube power	50 kW	60 kW	10 kW	50 kW
CT tube max. voltage	140 kVp	140 kVp	120 kVp	130 kVp
CT tube max. current	440mA	500 mA	80 mA	345mA
Max. CT rotation	0.5 s	0.4 s	12 s	0.5 s
Min. CT slice width	0.625 mm	0.6 mm	0.3 mm	0.6 mm

Figure 3 state-of-the-art SPECT/CT systems with some of their parameters

In 1996, a combined SPECT/CT design was presented by Blankespoor and co-workers including a clinical SPECT gamma camera in tandem with clinical single-slice CT. The images were co-registered by considering the axial displacement between the SPECT and CT imaging fields. First, the patient was imaged with CT after injection of the dye and an uptake period, and then with SPECT. The SPECT attenuation correlation factors were generated using CT data. This device was used to perform small number of clinical studies. Since then, SPECT/CT has advanced rapidly and many commercial designs are available today. The Infinia Hawkeye series (GE healthcare) offers SPECT imaging fused with low resolution anatomy. The latest design, Infinia Hawkeye 4 system has ability to perform cardiac and bone SPECT scans at half dose. Also, it has ability to acquire whole-body bone scans at half time and half dose. [12,13]

In 2004 the Symbia T2 (Siemens Medical Solutions), the first combined clinical SPECT/CT was launched including a dual-slice CT and a dual-head Symbia scintillation camera. This is the first fully-clinical commercial CT system. This design is also available with 6-slice and 16-slice CT system. Philips BrightView XCT SPECT/CT system has flat panel based volume CT technology. The maximum rotation speed of this system for 360° is 12 sec. GE healthcare NM/CT 670 pro SPECT/CT system is available with a 16-slice CT which has a maximum rotation time of 0.5s i.e. Single breath-hold scans with high image quality. [12,13]

Challenges

The main challenge in implementing SPECT/CT system is higher equipment cost, especially if system has 16- or 64-detector row CT unit. Some other challenges in implementing SPECT/CT are room renovation; increased power, cooling and space requirements; lead shielding;

and high SPECT/CT camera weight. The non-multidetector system can minimize some of these issues.

Another challenge with SPECT/CT is artefacts. During acquisition of CT and SPECT images, patient movements will lead to mis-registration, which not only affects anatomic localization but also generates an incorrect attenuation map, which leads to defects on the attenuation corrected images. To overcome this problem, in addition to routine quality control for both SPECT and CT, a co-registration program and associated quality control phantom must be used in SPECT/CT on a regular basis to ensure correct alignment between the SPECT and CT scanners. Training of Nuclear medicine technologists and physicians involved with both SPECT and CT is also a problem. CT physicians who regularly interpret results of CT studies may require additional training in evaluating the SPECT component of the study and vice versa. [14]

Applications

There are many applications of hybrid SPECT/CT, especially in oncology and cardiology. SPECT/CT is being used mainly for diagnosis purpose. In cardiology, myocardial perfusion imaging is main application of SPECT/CT. Also, SPECT/CT can potentially improve the current practice of evaluation of coronary artery calcification and coronary angiography. [14] SPECT/CT is also useful in bypass graft definition and localization in Coronary bypass graft. In oncology, SPECT/CT has applications in brain cancer, breast cancer, colorectal cancer, thyroid cancer, esophageal cancer, lung cancer, neuroendocrine tumor, prostate cancer, sympathetic nervous system tumors. Most of these applications are diagnostic and anatomical localization. [11] Radionuclide sentinel lymph node imaging using SPECT/CT has an important role in both surgical and radiation interventions of prostate cancer. [15,16] Monitoring brachytherapy is also one of the important application of SPECT/CT in prostate cancer. There are many other applications of SPECT/CT such as planar bone scintigraphy, localization of infections, evaluation of therapeutic efficacy for pancreatic chemotherapy. [10]

2. PET/CT

History and Development

In 1990s, Townsend and co-workers proposed the combined PET-CT system. Along with the image alignment the expected benefit of a hybrid PET/CT hardware was to derive the PET attenuation correction factors from the CT images. The first PET/CT prototype became functional in 1998, which was designed and developed by CTI PET systems in Knoxville, Tenn., USA (now Siemens Healthcare) and was clinically evaluated at

University of Pittsburgh. The design incorporated a rotating ECAT ART PET system (CTI PET Systems, Knoxville, Tennessee) and a single-slice spiral CT (Somatom AR. SP; Siemens Medical Solutions, Germany). It took 1h or more for this prototype to take image of the Torso. Instead of a lengthy conventional PET transmission acquisition, use of quickly acquired low-noise CT data reduced the total duration of the examination. [17]

The first commercial PET/CT appeared in market was the Discovery LS (GE healthcare) in 2001. After a few months, this was followed by the Biograph (Siemens medical solutions), and then later by the Gemini (Philips medical systems). Over the years, with the advances with PET and CT instrumentation the PET/CT designs have also evolved. Today, over 20 different PET/CT designs are available from six vendors worldwide. All PET/CT systems allows whole-body, multi-bed imaging within single examination, using the CT for attenuation and scatter correction of PET data. [18] In some PET/CT designs, to facilitate the use of the scanner for radiation therapy planning and to accommodate the large size of patients, the patient port is kept 70 cm in diameter. [17]

Challenges

The main challenge is artefacts which are of two types. (i) mis-registration which is caused by respiration, cardiac motion, patient motion, bowel movements, and bladder distention. (ii) Attenuation-correction artefact which is caused by metallic objects (e.g. dental implants, orthopedic prosthesis) and contrast media. The limited availability of new tracers is the major challenge especially in oncological imaging with PET/CT. Also, role of PET/CT for cardiac applications is yet to be determined. [18,19]

Table 1 [20]
CT and PET Parameters in Current PET/CT Designs

CT parameters		PET parameters	
Detectors	Ceramic	Scintillator	BGO; GSO; LSO
Slices	1, 2, 4, 8, 16	Detector size	4×4 mm; 6×6 mm
Rotation speed	0.4–2.0 s	Axial FOV	15–18 cm
Tube current	80–280 mA	Septa	2D/3D; 3D only
Heat capacity	3.5–6.5 MHU	Attenuation	rod; point; CT only
Trans. FOV	45–50 cm	Trans. FOV	55–60 cm
Time/100 cm	13–90 s	Time/bed	1–5 min
Slice width	0.6–10 mm	Resolution	4–6 mm
Patient port	70 cm	Patient port	60–70 cm

BGO = bismuth germanate; GSO = gadolinium oxyorthosilicate; LSO = lutetium oxyorthosilicate; FOV = field of view; MHU = mega Hounsfield units.

Applications

The clinical applications of PET/CT are mostly oncology. The accuracy of staging and restaging with PET/CT is better than CT or PET separately. [18] PET/CT guided biopsy can facilitate early diagnosis and staging of tumors. [19] PET/CT is accurate in initial diagnosis, staging and restaging in lung cancer, thyroid carcinoma, tumors in head and neck, esophageal cancer, breast cancer, colorectal cancer, lymphoma, and melanoma. [17] Juliano J. Cerci and co-workers performed PET/CT guided biopsy of liver lesions on a group of patients and based on that they concluded that PET/CT-guided biopsy is feasible. [21] Based on the PET/CT guided percutaneous fine needle aspiration cytology/biopsy, performed by MJ Govindarajan and co-workers, it was concluded that PET/CT guided biopsies may help in difficult situations, particularly in the cases where it is important to know which part of the tumor is active or which lesion is active with patient with widespread lesions. [22] Radiation therapy planning is also an important application of PET/CT. Because of misalignment issues due to cardiac and respiratory motion, cardiac PET/CT has not many applications yet. But, if strong clinical demand exists it

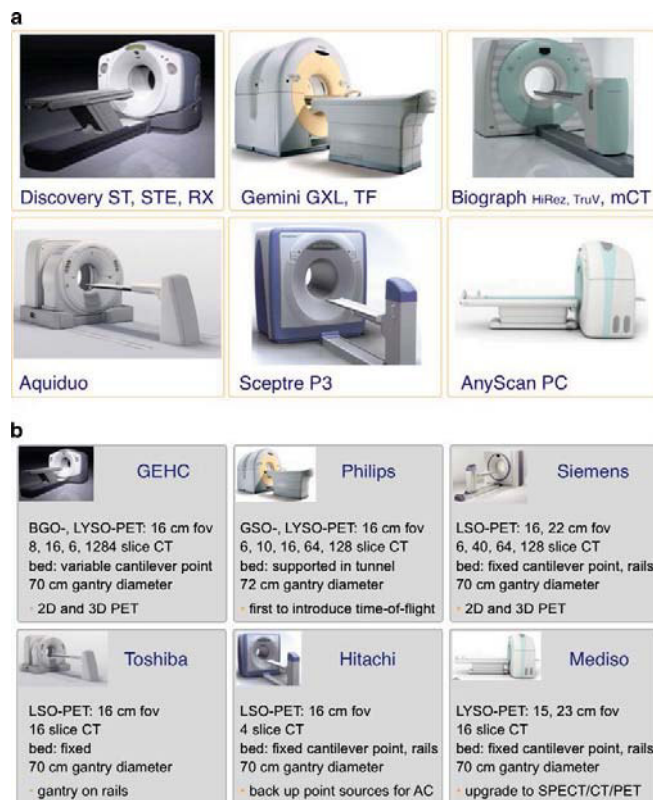

Figure 4 (a) Selected PET/CT designs offered by GE Healthcare, Philips Healthcare Systems, Siemens Healthcare Solutions, Toshiba, Hitachi and Mediso. (b) Selected system design parameters for the PET/CT systems in (a)

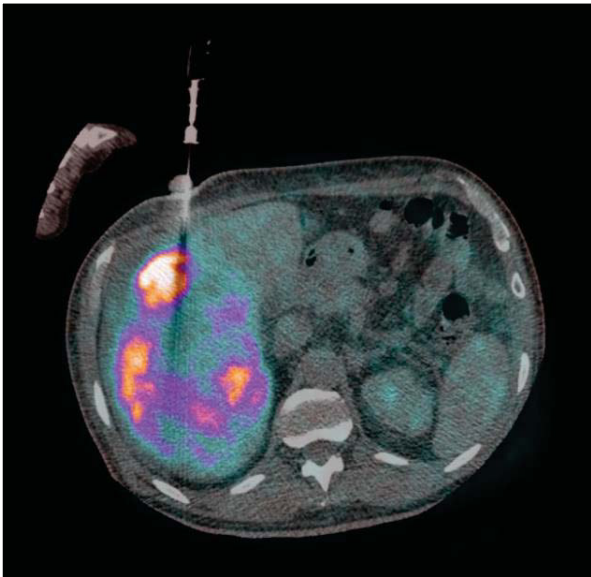


Figure 5 PET/CT guided needle intervention into highly metabolic area inside the lesion

can be expected that the issues like misalignment will be resolved. [18]

3. CT/ANGIOGRAPHY

History and Development

The first hybrid CT/angiography was developed by Professor Y. Arai (Director of the National Cancer Center, Tokyo, Japan) in 1992. In this system, a CT scanner and an angiography unit were arranged in line using a common patient table. This allows CT, angiography, and conventional fluoroscopy to be performed on the same table without moving the patient, thus omitting the risk of catheter and needle dislocation or compromising sterile conditions. [23] There are many CT/angiography designs available today from several vendors including MIYABI Angio-CT from Siemens healthcare and Angio-CT from Toshiba Medical.

There are some advantages of Hybrid CT/angiography system over C-arm cone beam CT. First, it has high-contrast resolution. Whereas, low-contrast resolution is critical problem for cone beam C-arm CT. Second, it has Large field of view compared to C-arm CT. The field of view of cone beam C-arm CT is limited to 20-25cm, thereby in patients with a large body size or multiple tumors, the whole liver cannot be scanned. While, CT/angiography system has maximum field of view of 50cm. Third, hybrid CT/angiography has minimal artefacts in contrast with c-arm cone beam CT (motion artefacts, metal artefact). Forth, and the important advantage of a CT/angiography system is that under the

real-time CT-fluoroscopy guidance, the needle puncture can be conducted. By contrast, the needle is inserted using conventional fluoroscopy guidance while using C-arm cone beam CT. [23]

There are also some disadvantages of hybrid CT/angiography. First, the radiation doses of patients are 1.2-1.7 times higher in hybrid CT/angiography compared to C-arm cone beam CT. Second, it has narrow workspace in gantry, which makes it impossible to perform a needle puncture. Also, the cost of hybrid CT/angiography is higher than c-arm cone beam CT. [23]

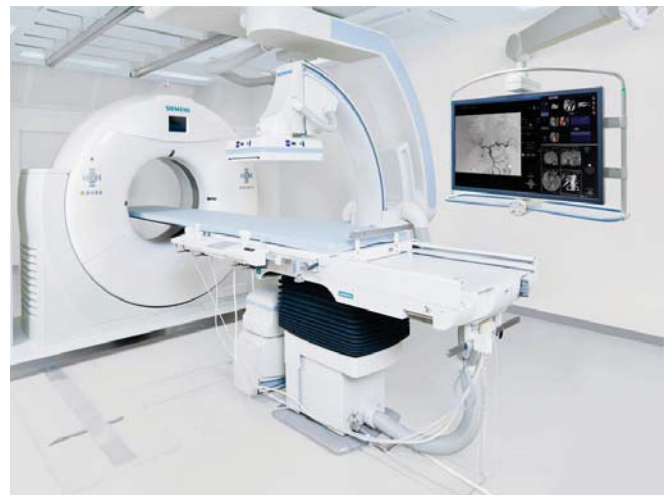

Figure 6 MIYABI Angio-CT from Siemens healthcare State-of-the-art image guidance for a broad spectrum of minimally-invasive interventions

Applications

Hybrid CT/angiography system has various applications as follows. CT/angiography is beneficial for liver-tumor diagnosis. CT/angiography system can conduct CT hepatic arteriography (CTHA) and CT arterio-portography (CTAP). The combination of CTHA and CTAP is most sensitive modality for detection of hepatocellular carcinoma (HCC). An interventional CT/angiography system is helpful for Intra-arterial tumor therapy, such as trans-arterial chemoembolization for hepatocellular carcinoma, and trans-arterial chemoembolization for various malignant tumors. Other important applications of CT/angiography are tumor ablation, and percutaneous drainage. [23]

IV. OUTLOOK

SPECT/CT

SPECT and SPECT/CT is continuously evolving with the advances in the detector technology. Recent developments in detector technology, which includes silicon photodiode or solid-state materials, has the

potential of improvement in spatial resolution and energy resolution, with compact size and higher stability, compared to conventional photomultiplier tube technology. These solid-state and semiconductor detectors have wide scope in imaging of heart, breast, and other small organs. Recently, dedicated nuclear cardiology cameras have been developed by Spectrum Dynamics, Ltd. (Caesarea, Israel) and by Cardiac, Inc. (Canton, MI). These cameras are 5 times faster than conventional system in acquiring cardiac image. GE healthcare has also developed the SPECT camera with similar performance. These new instruments can significantly decrease the total scan time of SPECT component of SPECT/CT. [10]

PET/CT

With introduction of LSO (lutetium oxyorthosilicate) and GSO (gadolinium silicate) detectors in PET/CT, coincidence time windows became shorter and lower-energy thresholds became higher compared with BGO (Bismuth germanium oxide) -based PET/CT. The sensitivity of PET/CT can be improved by the addition of more detectors in system. Also, by making crystal detector smaller, spatial resolution can be improved which can increase the lesion detectability of the system. [10] Recent developments in electro-magnetic needle tracking and navigation system can be used to perform real-time PET/CT guided biopsy procedures. The preoperative CT images can be registered with PET/CT images to enable real time PET/CT guidance. This technique has ability to perform procedures which are not feasible with standard single-modality image guidance. [19]

PET/MRI

The hybrid PET/MRI system was under the preclinical development since long time. Recently it became available for clinical use. PET/MRI offers various

features of MRI including fMRI, dynamic contrast-enhanced imaging, excellent soft-tissue contrast, and diffusion-weighted imaging with PET data. The data acquired by PET/MRI was compared with software-fused MRI and PET to evaluate clinical performance of PET/MRI. The first clinical hybrid PET/MRI system, Brain PET (by Siemens), was developed for brain imaging in which 3 T MRI was integrated with PET. Recently, the 3 main imaging system vendors (GE, Siemens, and Philips) have introduced different approaches for PET/MRI. GE and Philips Healthcare implemented the sequential approach in their PET/MRI. The GE approach uses two separate systems in two separate but adjacent rooms that can be used either separately for PET or MRI examinations or be used to travel a common mobile patient-bed from one scanner room to other scanner room. In this approach, patient motion artefact between two scan can be a problem. PET/CT can be used instead of PET, this is called as tri-modality approach. The Philips approach is also similar which uses the Ingenuity time-of-flight PET scanner and a 3 T MRI located next to each other with a patient bed that can be rotated 180° to transfer patient from one scanner to another. This system uses a MR-based attenuation correction approach. This system also has some technical issues like patient motion artefacts and limitation in acquiring data parallelly. Siemens uses simultaneous acquisition approach which has integrated single gantry system with the 3 T MRI within which PET detector ring is placed. This approach has some technical challenges including design and implementation of MRI-compatible PET photodetectors and techniques for maintaining magnetic field inhomogeneity and MR-based attenuation correction of PET data. [24]

There are many challenges in PET/MRI which are yet to be overcome. Some of these challenges are identification of clinical applications, clinic workflow, artefact

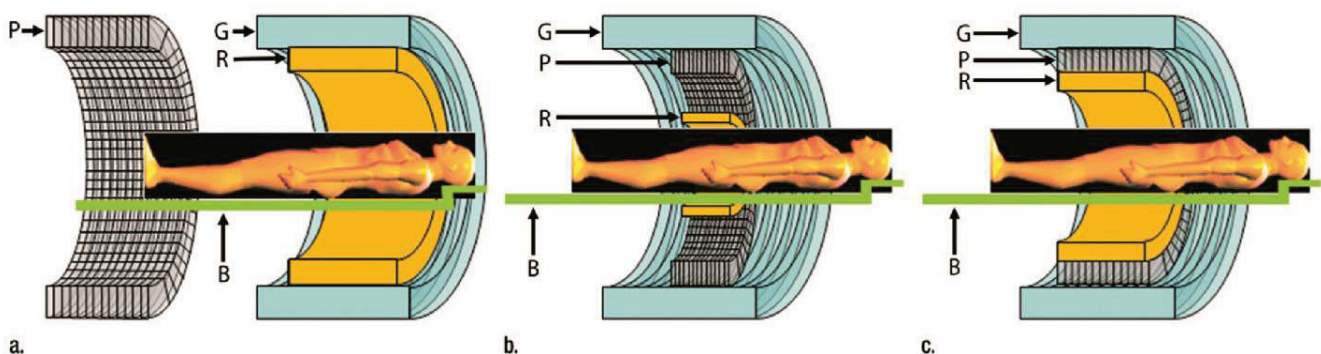


Figure 7: Schematic cross-sectional views of potential designs for combined PET/MR imaging systems: (a) tandem design with two imagers mounted back-to-back to allow sequential rather than simultaneous acquisition, (b) insert design with PET imager (P) inserted between radiofrequency coil (R) and gradient set (G) of MR imager, and (c) fully integrated design with two imagers in same gantry. Radiofrequency coil, gradient set, PET imager, and patient bed (B) are shown for all configurations

handling, regulatory requirements, risks and safety considerations, training and credentialing needs for image interpretation, comparative effectiveness, and cost-utility. [24]

US/MRI

Hybrid US/MRI system, which allows ultrasound (US) image and magnetic resonance (MR) data to be acquired simultaneously, has been developed recently. In this system, B-mode and Doppler US are performed, using a clinical 1-4MHz US transducer with 8-meter cable, inside the bore of clinical 1.5T MRI scanner. Due to US imaging susceptibility artefacts and RF noise are generated into MR images. RF noise can be minimized by using transducer shielded by aluminum foil. MR-safe US imaging transducer can be mounted at least 4cm from the target region of interest to overcome the susceptibility artefacts. This system was tested on cryo-gel phantoms and its use has been demonstrated in rats in vivo. Based on the experiments performed by Victoria Sherwood and co-workers in [25], it is concluded that further work is required to make tissues visible on MR-US images before, during, and after HIFU (High intensity focused ultrasound) and such system shows potential as a useful tool for clinical HIFU guidance and monitoring by combining soft tissue contrast by MRI with the real-time visualization of cavitation bubbles and blood flow using B-mode and Doppler ultrasound. [25]

V. CONCLUSION

Since last 2 decades, there has been constant advancement in field of imaging and interventional radiology. Hybrid systems evolved a lot since they introduced. Software based hybrid imaging is being used in various image guided procedures since long time. Hardware based hybrid imaging has wide range of applications in diagnostic radiology. It also has potential applications in image guided procedures. The role of hybrid imaging in image guided procedures are yet to be defined. With the development of individual systems, hybrid systems also evolve. Combination of functional and anatomical data can be very helpful during interventions. Depending on the application, different combination of imaging modalities can be used. To make hybrid system feasible in image guided procedures, some challenges should be overcome. In a nutshell, this technology enhances the quality of diagnostic as well as interventional imaging, which ultimately improves quality of treatment.

REFERENCES

[1] Townsend, D. (2008), Multimodality imaging of structure and function, *Phys. Med. Biol.* 53 (2008) R1–R39, doi:10.1088/0031-9155/53/4/R01

[2] Hricak, H., Choi, B.I., Scott, A., et al. (2010), Global Trends in Hybrid Imaging, *Radiology: Volume 257, Issue 2*, doi:10.1148/radiol.10100579/-/DC1

[3] Townsend, D., (2008), Dual-Modality Imaging: Combining Anatomy and Function, *J Nucl Med* 2008; 49:938–955, doi: 10.2967/jnumed.108.051276

[4] James, A.P., Dasarathy, B.V., (2014) Medical Image Fusion: A survey of the state of the art, *Information Fusion* 2014

[5] Abi-Jaoudeh, N., Kruecker, J., Kadoury, S., et al., (2012), Multimodality Image Fusion-Guided Procedures: Technique, Accuracy, and Applications, *Cardiovasc Intervent Radiol* (2012) 35:986–998, DOI 10.1007/s00270-012-0446-5

[6] Fahrig, R., Heit, G., Wen, Z., et al., (2003), First use of a truly-hybrid X-ray/MR imaging system for guidance of brain biopsy, *Acta Neurochir (Wien)* (2003) 145: 995–997, DOI 10.1007/s00701-003-0138-7

[7] Biaggi, P., Fernandez-Golfin, C., Hahn, R., et al., (2015), Hybrid Imaging During Transcatheter Structural Heart Interventions, *Curr Cardiovasc Imaging Rep* (2015) 8: 33, DOI 10.1007/s12410-015-9349-6

[8] Slomka, P.J., (2004), Software Approach to Merging Molecular with Anatomic Information, *J Nucl Med* 2004; 45:36S–45S

[9] Mirshanov, D.M., (1987), Transmission-Emission Computer Tomography. Tashkent Branch, All-Union Research Surgery Center, USSR Academy of Medical Science; USSR: 1987

[10] Seo, Y., Aparici, C.M., and Hasegawa, B.M., (2008) Technological Development and Advances in SPECT/CT. *Semin Nucl Med.* 2008 May; 38(3): 177–198, doi: 10.1053/j.semnuclmed.2008.01.001.

[11] Kaplan, CH., (1989) Transmission/emission registered image (TERI) computed tomography scanners. International patent application PCT/US90/03722. 1989

[12] Beyer, T., Freudenberg, L.S., Townsend, D., et al., (2011), The future of hybrid imaging—part 1: hybrid imaging technologies and SPECT/CT, *Insights Imaging* (2011) 2:161–169, DOI 10.1007/s13244-010-0063-2

[13] Buck, A., Nekolla, S., Ziegler, S., et al., (2008), SPECT/CT*, *J Nucl Med* 2008; 49:1305–1319, DOI: 10.2967/jnumed.107.050195

[14] Bybel, B., Brunken, R., DiFilippo, F., et al., (2008), SPECT/CT Imaging: Clinical Utility of an Emerging Technology, *RSNA RadioGraphics* 2008; 28:1097–1113, doi: 10.1148/rg.284075203

[15] Piato, J., Filassi, J., Vega, A., et al., (2016), SPECT-CT Guided Thorascopic Biopsy of Sentinel Lymph Nodes in the Internal Mammary Chain in Patients with Breast Cancer, *Innovations: Volume 11, Number 2, March/April 2016*

[16] Aparici, C., Seo, Y., (2012), Functional Imaging for Prostate Cancer: Therapeutic Implications, *Semin Nucl Med.* 2012 September; 42(5): 328–342, doi: 10.1053/j.semnuclmed.2012.04.004.

[17] Blodgett, T., Meltzer, C., Townsend, D., (2007), PET/CT: Form and Function, *Radiology: Volume 242: Number 2*

[18] Beyer, T., Townsend, D., Czernin, J., et al., (2011), The future of hybrid imaging—part 2: PET/CT, *Insights Imaging*, DOI 10.1007/s13244-011-0069-4

[19] Kobayashi, K., Bhargava, P., Raja, S., et al., (2012), Image-guided Biopsy: What the Interventional Radiologist Needs to Know

about PET/CT, *RadioGraphics* 2012; 32:1483–1501, doi: 10.1148/rg.325115159

[20] Townsend, D., Carney, J., Yap, J., et al., (2004), PET/CT Today and Tomorrow, *J Nucl Med* 2004; 45:4S–14S

[21] Cerci, J., Huber, F., Bogoni, M., (2014), PET/CT-guided biopsy of liver lesions, *Clin Transl Imaging* (2014) 2:157–163, DOI 10.1007/s40336-014-0056-0

[22] Govindarajan, M.J., Nagaraj, K.R., Kallur, K.G., et al., (2009), PET/CT guidance for percutaneous fine needle aspiration cytology/biopsy, *Indian J Radiol Imaging*. 2009 Aug; 19(3): 208–209, doi: 10.4103/0971-3026.54885

[23] Tanaka, T., Arai, Y., Inaba, Y., et al., (2014), Current role of hybrid CT/angiography system compared with C-arm cone beam CT for interventional oncology. *Br J Radiol* 2014;87:20140126

[24] Jadvar, H., Colletti, P., (2014), Competitive Advantage of PET/MRI, *Eur J Radiol*. 2014 January; 83(1): 84–94. doi: 10.1016/j.ejrad.2013.05.028

[25] Sherwood, V., Civale, J., Rivens, I., et al., (2014), Development of a Hybrid Magnetic Resonance and Ultrasound Imaging System, *BioMed Research International Volume* 2014, Article ID 914347, <http://dx.doi.org/10.1155/2014/914347>

Images

[Fig.1 & 3] Beyer, T., Freudenberg, L.S., Townsend, D., et al., (2011), The future of hybrid imaging—part 1: hybrid imaging technologies and SPECT/CT, *Insights Imaging* (2011) 2:161–169, DOI 10.1007/s13244-010-0063-2

[Fig.2] James, A.P., Dasarathy, B.V., (2014) Medical Image Fusion: A survey of the state of the art, *Information Fusion* 2014

[Fig.4] Beyer, T., Townsend, D., Czernin, J., et al., (2011), The future of hybrid imaging—part 2: PET/CT, *Insights Imaging*, DOI 10.1007/s13244-011-0069-4

[Fig.5] Cerci, J., Huber, F., Bogoni, M., (2014), PET/CT-guided biopsy of liver lesions, *Clin Transl Imaging* (2014) 2:157–163, DOI 10.1007/s40336-014-0056-0

[Fig.6] <https://www.healthcare.siemens.com>

[Fig.7] Torigian DA, Zaidi H, Kwee TC, et al. PET/MR imaging: technical aspects and potential clinical applications. *Radiology*. 2013; 267:26–44. [PubMed: 23525716]

Do we need Robotic Prostatectomy ?- A Review

Debarati Bag , Medical Systems Engineering , FEIT , OVGU , Magdeburg.

Introduction

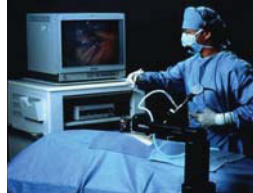- Robotic assisted radical prostatectomy (RARP) is a rapidly evolving technique used for the medication of localized prostate cancer.

- 65 % percent of the surgeries in USA are robotic assisted whereas Europe and other countries is somewhat slower in accepting this technology.

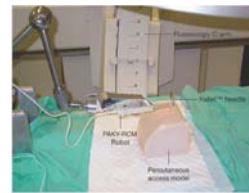
- It seems that RARP has advantages over open in terms of blood lose, hospital stay , decreased pain but there is no definitive evidence.

- Although an effective transition can be made from ORP to RARP the outcomes may be as operator dependent as technology driven.

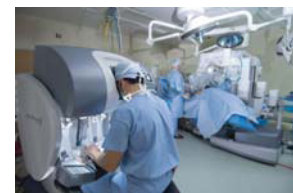Development Of Robotic Surgery



1)AESOP-voice activated robot



2) PAKY-RCM robot



3) Da Vinci robotic system

Comparison with laparoscopic and open surgeries

- In 2000 the first telesurgical laparoscopic surgery was Performed.

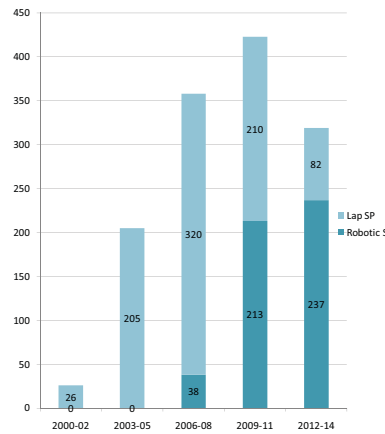
- Gradually there had been a successful transition from Open to laparoscopic technology with the assistance of robotic device.

- Centers which were for reputed for open tried their hands on RLRP.

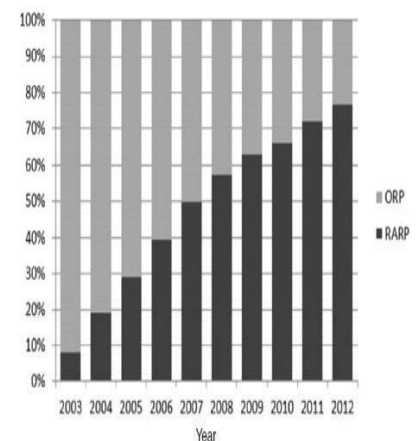
- One study proved that out of 208 systems installed worldwide in 2004 only 92(44%) were used during LRP. 78 systems existed in the USA and only 14 were present in Europe.

- Another study suggested that a total of 1330 cases were done at participating institutions over the study period. Most of the procedures were done laparoscopically (63.4%), but there was an increase in the number of robotic cases over time.

- It is not surprising that the role of robot-assisted laparoscopic surgery has expanded for the reputation of being safe and effective option over the years in these institutions as shown in graph 1 and 2.

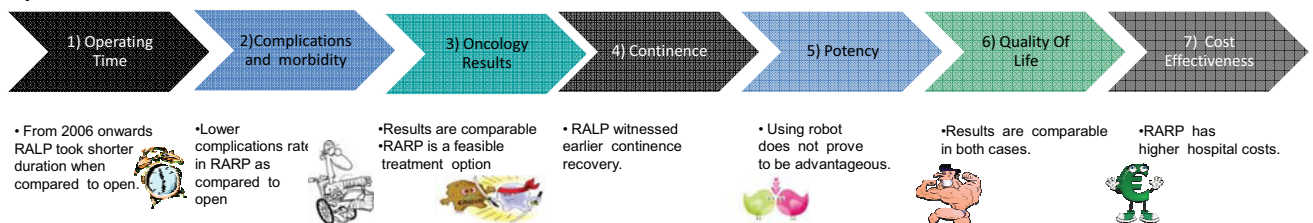


Graph 1 : Temporal trend in the use of laparoscopic versus robotic technique for simple prostatectomy over the study period 2000–2014 at participating institutions



Graph 2: Transition from open to robot assisted prostatectomy over the years

Parameters for comparison



Conclusion

- Modern medical principles must be supported by strong evidence from high quality studies but unfortunately the surgical field lacks randomized or observational trials. Thus, great debate concerning robotic-assisted laparoscopic procedures is on-going: much of the debate centers stems from a lack of evidence on the superiority or non-inferiority of robotic techniques versus traditional ones.

- The ideal study should comprise a randomized design with all procedures performed by one surgeon who has adequately mastered both techniques, although surgeon
- A definitive answer to our question will come probably from time, when robotic procedures will be performed with more devices and improved performance among surgeons far beyond the present standards.

References

- [1] Bill-Axelsson A, Holmberg L, Ruutu M, Häggman M, Andersson SO, et al; Scandinavian Prostate Cancer Group Study No. 4. Radical prostatectomy versus watchful waiting in early prostate cancer. N Engl J Med 2005; 352: 1977–84
- [2] Dasgupta P, Patil K, Anderson C, Kirby R. Transition from open to robotic-assisted radical prostatectomy. BJU Int 2008; 101: 667–8.
- [3] Goldstraw MA, Patil K, Anderson C, Dasgupta P, Kirby RS. A selected review and personal experience with robotic prostatectomy: implications for adoption of this new technology in the United Kingdom. Prostate Cancer Prostatic Dis 2007; 10: 242–9.
- [4] SULSER T, GUILLONNEAU B, VALLANCIEN G. Complications and initial experience with 1228 laparoscopic radical prostatectomy's at 6 European centers. J Urol 2001;165:615A.
- [5] CATALONA WJ, SMITH DS. Cancer recurrence and survival rates after anatomic radical retropubic.

Do we need robotic prostatectomy? - The Big Question

Debarati Bag,
Medical System Engineering,
FEIT, OVGU

Abstract— Robotic assisted radical prostatectomy (RARP) is a rapidly evolving technique used for the medication of localized prostate cancer. Data has proven that around 65% of the prostatectomy surgeries are robot assisted in the USA whereas Europe and rest of the world has been somewhat slower in accepting this innovation. This article reviews the current literature on RARP with respect to some parameters such as operating time, complications and morbidity, oncology results, potency, quality of life ,urinary incontinence and cost effectiveness. At a first glance it would appear that RARP has advantages over open in terms of reduced blood loss, decreased pain, short hospital stay and low margin rates. However there is no definitive evidence to show an advantage over standard surgeries but the way RARP has reached parity with laparoscopy or open within five years is astonishing. In the absence of randomized trials, the outcomes of RARP compared with ORP and LRP look favorable, but must be considered with a degree of caution. Although an effective transition can be made from ORP and LRP to RARP, the outcomes may be as much operator-dependent as technology-driven

Index terms- Robotic assisted radical prostatectomy (RARP), Robotic assisted laparoscopy prostatectomy (RALP), Prostate Cancer (PCa)

I .INTRODUCTION

Over the past few decades the field of urology has witnessed tremendous changes in surgical practice. It has witnessed and evaluated infusions of novel technology and minimally invasive instrumentation and at the same time embraced into the urological community with a primal, ongoing desire to improve patient outcome. It has been almost 20 years that Urologists have led their way in robotic surgery. Robot-assisted prostatectomy is one of the most common robotic procedures worldwide, particularly in the United States, where there are at present more than 550 DA Vinci robotic systems in operation. Many surgeons argue that this scenario is just a reflection of marketing; but now this procedure is widely regarded as the ‘gold standard’.

Meanwhile the acceptance of robot assisted prostatectomy in Europe and elsewhere in the world has been slower for many reasons. Urologists claimed that the experience they gained in open prostatectomy has yielded excellent results. Also, the cost in setting up and maintaining a robotic system is quiet high, which is pertinent in poorer nations. Finally, the volume–outcome relationship is also an issue, while the smaller centers found it difficult to overcome their learning curve.

Compared with open prostatectomy, robot assisted prostatectomy was found to be associated with less blood loss, a shorter postoperative catheterization period, and shorter hospital stay, but at the expense of a longer operative time. However there is no definitive evidence to show an advantage over standard laparoscopy, but the fact that this technique has reached parity with laparoscopy within 5 years is encouraging. This article reviews the current scenario with regard to the outcomes of robotic prostatectomy specifically in the arena of operating time, complications and morbidity, oncology results, continence, potency, quality of life ,urinary incontinence and cost effectiveness.

II. THE DEVELOPMENT OF ROBOTIC SURGERY: HISTORICAL ASPECTS

In 1988 the first robotic surgery took place and was performed by Kwoh; where they used a robot with improved absolute positioning accuracy for CT guided stereotactic brain surgery. Davies was the first to report the use of a robot in urological surgery in the year 1991. They undertook a transurethral resection prostate (TURP) using a modified industrial arm. ROBODO was introduced in 1992 was the first commercially available robotic system to perform orthopedic hip surgery. Laparoscopic Radical Prostatectomy (LRP) drastically changed the role of video-endoscopic surgery in urology. Laparoscopy was famous in the nineties as a representation of a nice technique used to look for indication and was used only by dedicated centers for few indications of ablative surgery. It was only in the year 1988 a breakthrough was initiated when Guillonneau and Vallancian performed radical prostatectomy thereby increasing worldwide interest in minimal invasive surgery.

In 1992, Schuessler a non academic urologist attempted the first LRP with the assistance of two endourologist The team

was successful in performing 9 LRP procedures but they found no benefit over open procedure. Meanwhile, USA was skeptical about LRP. It was only when Menon hired Guillonneau and Vallancian to train and establish LRP at their institutions; the former attitude toward LRP began to transform. Also one of the important transition was the introduction of the da Vinci Robotic Surgical System which allowed a non laparoscopic surgeon to accomplish minimally invasive prostatectomy.

Currently, there are three main systems available in urological practice, all at varying stages of development:

- Automated endoscopic system for optimal positioning (AESOP; Computer Motion, CA now Intuitive Surgical Corp.)
- PAKY-RCM (Urorobotics, Baltimore, MD)
- Da Vinci (Intuitive Surgical Corp., Sunnyvale, CA, USA).

2.1. AESOP

Automated endoscopic system for optimal positioning (AESOP) was introduced in the mid-1990s and was cleared by the Food and Drug Administration in 1994 to assist surgeons in minimally invasive surgery specifically laparoscopy. AESOP's function is to move an endoscope inside the patient's body at the time of surgery. The camera moves based on voice commands given by the surgeon. Voice activation of the AESOP arm allows the surgeon to position the camera while also controlling the other two arms of the ZEUS system. The endoscope can also be controlled by a computer which allows for more precise movements and also allows the endoscope to be inserted into the patient through a smaller incision (a key component of minimally invasive surgery). This was the first surgical robotic system to gain approval by the US FDA and was used commonly for laparoscopic radical prostatectomy (LRP).

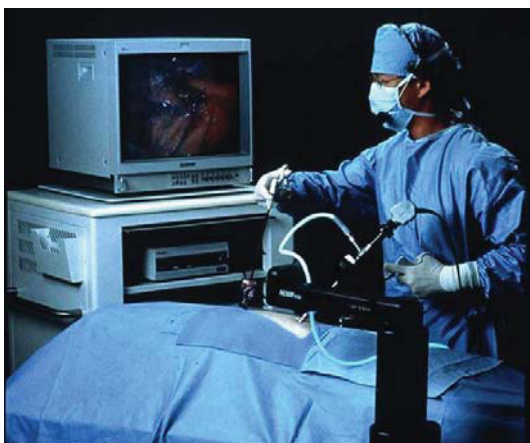

Figure 1 : Aesop is a voice -activated robotic arm that holds the camera and endoscope assembly for the surgeon during an endoscopic procedure.

2.2. PAKY

This robotic system was first developed in the year 1996 for the percutaneous access to the kidney. This has now been superseded by the Tracker system in 2002. This system was responsible for the first randomized control trial of telerobotic surgery performed between Guy's and John Hopkins Hospitals with robotic needle punctures during percutaneous nephrolithotomy (PCNL). While the robot took longer to perform the procedure, it was significantly more precise than a human.

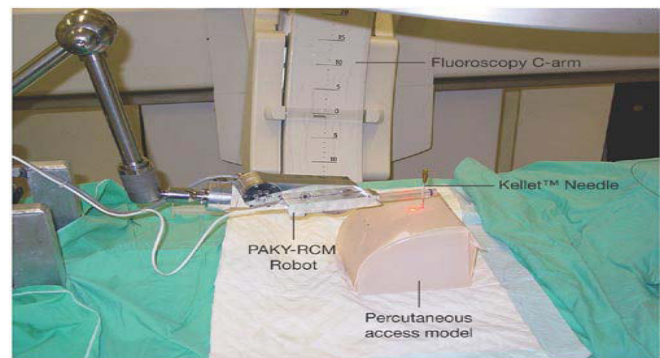


Figure 2: PAKY-RCM robot during a randomized, controlled trial of telerobotics.

2.3. Da Vinci robot

This is the state-of-the-art robotic surgical system, which has shown to be superior to its direct competitor, the ZEUS. The **da Vinci** Surgical System (sic) is a **robotic** surgical system made by the American company Intuitive Surgical. Approved by the Food and Drug Administration (FDA) in 2000, it is designed to facilitate complex surgery using a minimally invasive approach, and is controlled by a surgeon from a console.

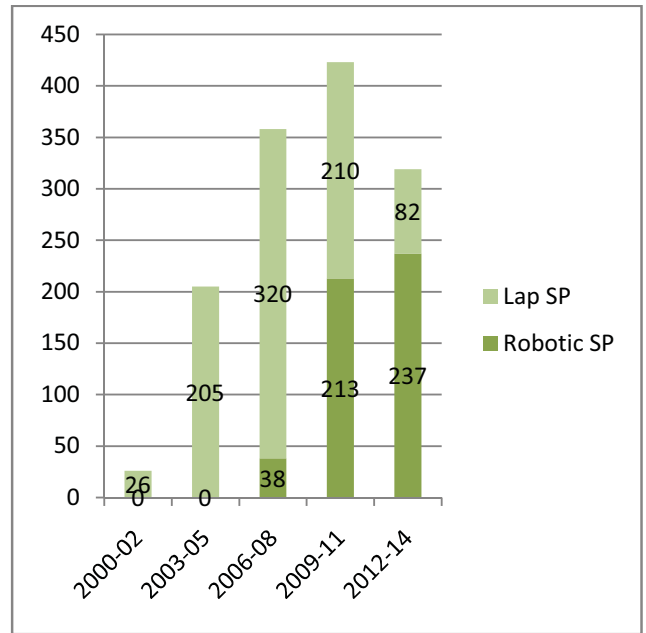
The Da Vinci robot is a combination of a camera, a three- or four-arm robot and a master console. One of the major advances with this system is the intuitive nature of operation. The robotic arms have unique Endo-wrist articulations allowing six degrees of freedom, which is similar to the number of degrees of freedom of the human wrist. The instrumentation provides a three-dimensional (3D) vision to the operating surgeon with the ability to have ten times magnification. The console instruments are sensitive enough to translate a pressure of 2.2N times and are also able to filter out surgical tremor. Moreover, the ergonomic design of the console allows the surgeon to sit more comfortably while viewing the surgical field.

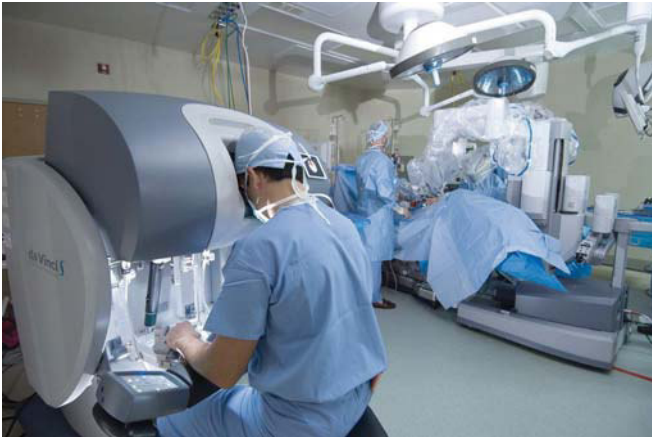

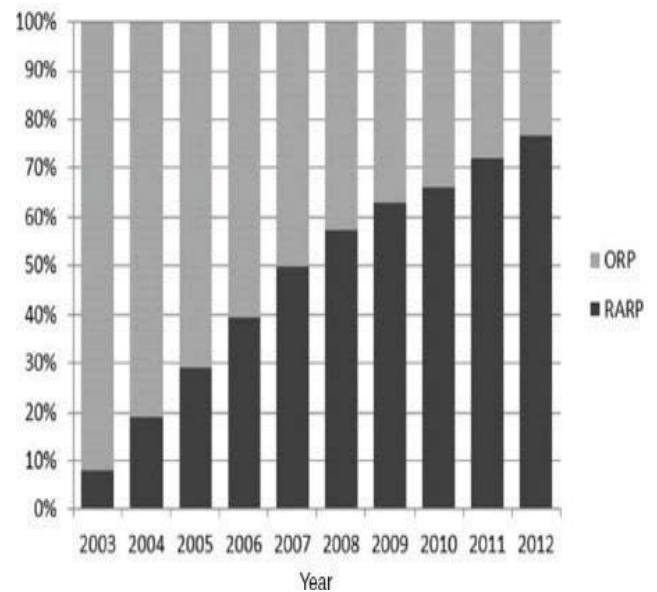
Figure 3: Da Vinci® Robotic Surgery.

III.A. Comparison with laparoscopic and open surgeries

In 2000 the first telesurgical laparoscopic radical prostatectomy was performed. Meanwhile in the USA enthusiasm for robotically assisted technique replaced the conventional LRP. Gradually there had been a successful transfer from open to laparoscopic technology with the assistance of robotic device. Thus surgeons who were inexperienced with laparoscopy were able to perform minimally invasive prostatectomy without indulging in time intensive training required for LRP. Even centers that are well recognized for their excellence in open surgeries have begun to explore RLRP. Apart from da Vinci system voice controlled AESOP robot was frequently used during LRP. One study proved that out of 208 systems installed worldwide in 2004 only 92(44%) were used during LRP. 78 systems existed in the USA and only 14 were present in Europe. Factors like uncertainties in reimbursement, high cost of maintenance and the high price of hand instruments (approx. 1500 euros /case) significantly limited the distribution and acceptance. Another study suggested that a total of 1330 cases were done at participating institutions over the study period. Most of the procedures were done laparoscopically (63.4%), but there was an increase in the number of robotic cases over time. It is not surprising that the role of robot-assisted laparoscopic surgery has expanded for the reputation of being safe and effective option over the years in these institutions, as shown in Graph 1.



Graph 1: Temporal trend in the use of laparoscopic versus robotic technique for simple prostatectomy over the study period 2000–2014 at participating institutions.



Graph 2: Transition from open to robot assisted prostatectomy over the years.

B. Morbidity and complications.

The absence of standardization in reporting surgical complications for open, laparoscopic and robot-assisted prostatectomy has resulted in a wide variation in the types of complications reported as well as in the overall incidence of complications. A comprehensive review of the literature of laparoscopic open and RALP series was performed to summarize overall complication rates. The most common complications included preoperative bleeding or blood transfusion, bladder neck contracture, and anastomotic leakage. A study was conducted where we found that out of 1243 patients treated at 2 centers in Germany illustrated similar patterns (Table 1). A comprehensive description of incidence and types of complications revealed a total major and minor complication rate of 17%, 4% and 14.6%. A total of 34 morbidities were encountered during 246 LRP cases. There was 2% life threatening complications and no grade V complications (i.e. death). Minimally invasive radical prostatectomy has become a well-accepted treatment modality for localized prostate cancer. After transcending the learning curve, LRP and RALP may potentially be associated with lower complication rates as compared to RRP. As demonstrated in this chapter, it is often difficult to critically analyze complication data in the absence of a standardized classification system of surgical complications. As more data with longer follow-up is available, the complication profile of LRP and RALP will be further elucidated and allow more meaningful comparisons to the RRP literature.

Wound dehiscence	1.4%	0.1%
Lymphocele	2.3%	-
Prolonged lymphdrainage	1.3%	0.3%
Urine retention	1.7%	1.0%
Pelvic hematoma	0.7%	0.5%

Table 1: Comparison of different complications after laparoscopy and open prostatectomy

C. Oncological outcomes

Although numerous past studies have reported favorable oncologic outcomes for open prostatectomy in the treatment of high-risk prostate cancer, the role of RARP in this ambience has not yet been clearly explored. Comparative studies with respect to long-term survival rates associated with open and RARP in the treatment of high-risk PCa are still lacking. According to a survey done in Kyung Hee University School of Medicine, Seoul, 5 year survival outcomes of open surgery was compared with those of RALP. The comparison between oncologic outcomes of RARP, in terms of PSM (positive surgical margin) and 5-year BCRFS rates in high-risk PCa patients treated by the same surgeon, with those of open prostatectomy surgeries illustrate that the two procedures are comparable. Although surgical experience affects the PSM rates, especially in pT3 disease, latest findings indicate that RARP is a feasible treatment option for high-risk prostate cancer patients.

D. Continence

There are few neck-to-neck comparisons of open versus robotic surgery performed by the same surgeon at the similar points during their career. It would be easy to fudge the comparison in favor of the robotic camp by selecting a handful of favorable robotics series and several low quality open radical prostatectomy studies. It is more informative to take an honest look at all of the available literature and analyze the outcome data. When analyzing the data from high volume surgeons (i.e. > 500 cases) where the technique from case to case is nearly identical, we have technical data so-to-speak, that is, data which is more influenced by surgical modality and operative technique than by patient factors. We must also review, however, basic studies, which are more representative of the experience the average patient will have in a general community surgeon practice. The reality is that many patients are not having their operation done at the high volume academic centers from the top tier surgeons who are writing the papers from which we are extracting this data.

A single-center prospective comparative study between open prostatectomy and RALP witnessed that robotic surgery allowed a statistically significant earlier continence recovery

Complication	Open(N=1243)	RALP(N=1243)
Site	University of Hamburg	SLK Kliniken Heibronn
Major Complication	10.7%	12.3%
Intraoperative	6.6%	8.9%
Transfusion Rate	6.1%	7.7%
Rectal Lesion	0.2%	1.2%
Urethra Lesion	0.3%	-
Postoperative	4.1%	3.6%
Cardiovascular	0.6%	0.1%
Tromboembolic	1.3%	0.3%
Infections	0.5%	-
Lymphocele	0.6%	-
Renal	0.2%	0.9%
Minor Complication	15.8%	3.4%
Cardiovascular	1.1%	-
Nervous system	1.1%	0.3%
Gastrointestinal	0.4%	0.2%
Pulmonary system	0.6%	0.1%
Renal	0.6%	0.2%

compared with the traditional retropubic approach (Tewari 2003). In a particular study performed at UC Irvine Department of Urology, it was demonstrated that 50% of the patients recovered continence (defined as no pads or a security liner) at 44 days with the robotic approach vs. 160 days with the open approach.

E. Potency

The chance of regaining potency diminishes with age and with the number of nerves damaged. However it is technically possible to spare the nerves, but seldom the nerves themselves are cancerous and must be destroyed since the primary goal of the surgeon is to remove the prostate cancer. If the cancer has not reached the nerves controlling erection, the da Vinci Robot has the visual capabilities and the precision necessary to spare these nerves in most cases. Therefore it is possible that using the robot may add to the chances of being potent after surgery. However, there is no way to guarantee this due to variability in patient anatomy and condition. It is important to realize that some men never regain the ability to maintain an erection after robotic prostatectomy.

It is still unclear how using the da Vinci robot for prostatectomy will affect potency. Astonishingly it would appear that using the robot may increase chances of potency, and research as to how all this may translate into earlier return or increased percentage of potency is still in spree. It is now a proven fact that using the robot reduces blood loss during robotic prostatectomy surgery, and length of hospital stay, and thus this indicates a decrease in trauma and inflammation, which leads us to ponder that there may be a higher chance of potency (erectile function). Urinary continence at zero pads, bladder capacity, and urinary symptom scores (for men with moderate symptoms) at three months are all also improved over open surgery results. Thus the robot has its own benefits.

F: Quality of life

Although quality of life has been well studied after open prostatectomy and RALP there are only few studies between these two. It was observed that there was similar 12 months baseline return to urinary and sexual function. Optimal outcome of RALP has not yet been achieved. Quality of life improved in 7.8% and remained stable in 37% out of 500 patients undergoing RALP.

G: Cost effectiveness

The contemporary population based study revealed that adoption of RARP occurred between 2003 and 2013. RARP showed lower morbidity compared to open particularly in lower complication rates, blood transfusion rates and shorter length of stay in hospital. RARP has higher hospital cost that are attributed to higher supply and operating room cost. However this cost difference varies among the highest

volume surgeons.

IV. Conclusion

The pioneer advancement in the surgical treatment of local prostate cancer was the development of robotic surgical technology. Initially developed by the United States Department of Defense for use in military battlefield applications, robotic technology was adapted for civilian use through the entrepreneurial efforts of 2 rival corporations, Intuitive Surgical, Inc, and Computer Motion, Inc. These companies simultaneously developed robotic interfaces for use in human surgical applications. Computer Motion, Inc, introduced the Zeus Surgical System at approximately the same time that Intuitive Surgical, Inc, developed its da Vinci Surgical System. But it had its own pros and cons. The display system of the da Vinci projects the image in the direction of the surgeon's hands, the optically correct hand-eye coordination is restored. This is more difficult with laparoscopy, in which the camera is sometimes offset to the plane of dissection. The 11-mm telescope in the da Vinci system is a combination of two 5-mm optical channels (one for the right eye and one for the left eye), which have 2 separate 3-chip-charged coupling devices in the camera head. The 2 images are displayed to provide 3-dimensional (3-D) stereoscopic vision to the surgeon, providing depth perception lacking in laparoscopy. The conventional laparoscopic technique does not provide a 3-D depth of view. The movements of the robotic system are intuitive (ie, a movement of the master control to the right causes the instrument to move to the right), as opposed to the counterintuitive movements in laparoscopy with fulcrum movement effects (ie, movement of the laparoscopic instrument to the right by the surgeon causes the tip of the instrument to move to the left inside the patient's body). The robotic systems provide increased precision by filtering hand tremors, providing magnification (10X or 15X), and providing scaling for the surgeon's movements (a 1:3 scaling means that a 3-in movement of the master is translated into a 1-in movement of the instrument tip).

The robotic instruments have articulated tips, which permit 6° of freedom in movements (ie, they mimic human wrist movements, including rotation), which is unlike laparoscopy, with which only 4° of freedom are permitted. Robotic techniques also have various disadvantages. The current-generation robot is still bulky and tends to limit the working space of the assistant(s). The availability of instrumentation for the robotic systems is presently limited, although development of new instruments is ongoing. Economically, the robotic system is viable only for centers with a high volume of cases or multidisciplinary robotic use. The system cost exceeds \$1.2 million, and the annual maintenance costs range from \$100,000 to \$150,000. Although these factors are in play still RALP has become a commonplace in the US over the last decade. Since they experience less surgical blood loss

fewer blood transfusions, short hospital stay duration and a much improved surgical margin status as compared to ORP. However very little is known about comparative long term outcomes of ORP and RALP after 12 months follow up. Whereas a similar study showed significant improved urinary continence among RALP patients. In meta analysis states RALP patients experienced a minimal rate of erectile dysfunctions compared to ORP patients. Also RALP patients has shown the trait of superior sexual functions compared to ORP patients. RALP operative times were significantly longer while when compared to open surgeries. But by 2006 this scenario changed. In the later years RALP operative times decreased to 170 minutes (shorter than ORP) and positive margin rates decreased to 17%. This is owing to increasing surgeon and surgical team experience.

Modern medical principles must be supported by strong evidence from high quality studies but unfortunately the surgical field lacks randomized or observational trials. Thus, great debate concerning robotic-assisted laparoscopic procedures is on-going: much of the debate centers stems from a lack of evidence on the superiority or non-inferiority of robotic techniques versus traditional ones. One can see arguments in favors of robotic radical prostatectomy in the outlines of relative risks that reflect a favorable impact of robotic assistance in the procedure in terms of lower transfusion rates, fewer minor complications and shorter hospital stay. Moreover, functional outcomes, namely continence and potency, as well as oncological outcomes, such as surgical margins and biochemical control, seem to be improved. Nevertheless, some studies warn us of two main flaws that may affect their conclusions: one is the significant heterogeneity found in the meta-analysis for each outcome measured. While this could have originated from differences in the methods used to report data, a selection bias to allocate more favorable cases to the the newest surgical technique may also be at play. The other and most important flaw in regards to the outcomes reported is that some series included in the meta analysis show an unusually high rate of incontinence in patient submitted to open radical prostatectomy; consequently the comparison between the two techniques is statistically significant in favor of robotic prostatectomy, however this is not a demonstration of superiority but only of a poor surgical skill with the open technique. The ideal study should comprise a randomized design with all procedures performed by one surgeon who has adequately mastered both techniques, although surgeon and patient preferences may make this almost impossible. A definitive answer to our question will come probably from time, when robotic procedures will be performed with more devices and improved performance among surgeons far beyond the present standards.

V. References

- 1) Bill-Axelsson A, Holmberg L, Ruutu M, Häggman M, Andersson SO, et al; Scandinavian Prostate Cancer Group Study No. 4. Radical prostatectomy versus watchful waiting in early prostate cancer. *N Engl J Med* 2005; 352: 1977–84.
- 2) Dasgupta P, Patil K, Anderson C, Kirby R. Transition from open to robotic-assisted radical prostatectomy. *BJU Int* 2008; 101: 667–8.
- 3) Goldstraw MA, Patil K, Anderson C, Dasgupta P, Kirby RS. A selected review and personal experience with robotic prostatectomy: implications for adoption of this new technology in the United Kingdom. *Prostate Cancer Prostatic Dis* 2007; 10: 242–9.
- 4) SULSER T, GUILLONNEAU B, VALLANCIEN G. Complications and initial experience with 1228 laparoscopic radical prostatectomies at 6 European centers. *J Urol* 2001;165:615A.
- 5) RASSWEILER J, STOLZENBURG J, SULSER T, DEGER S, ZUMBE J, HOFMOCKEL G, JOHN H, JANETSCHKE G, FEHR JL, HATZINGER M, PROBST M, ROTHENBERGER KH, POULAKIS V, TRUSS M, POPKEN G, WESTPHAL J, ALLES U, FORNARA P. Laparoscopic radical prostatectomy – The experience of the German Laparoscopic Working Group. *Eur Urol* 2006; 49: 113-119.
- 6) PAUL A, PLOUSSARD G, NICOLAIEW N, XYLINAS E, GILLION N, DE LA TAILLE A, VORDOS D, HOZNEK A, YIOU R, ABOU CC, SALOMON L. Oncologic outcome after extraperitoneal laparoscopic radical prostatectomy: midterm follow-up of 1115 procedures. *Eur Urol* 2010;57:267-272.
- 7) BINDER J, KRAMER W. Robotically-assisted laparoscopic radical prostatectomy. *BJU Int* 2001; 87: 408-410.
- 8) AGARWAL PK, SAMMON J, BHANDARI A, DABAJA A, DIAZ M, DUSIK-FENTON S, SATYANARAYANA R, SIMONE A, TRINH QD, BAIZE B, MENON M. Safety profile of robot-assisted radical prostatectomy: a standardized report of complications in 3317 patients. *Eur Urol* 2011;59:684-698.
- 9) PATEL VR, COELHO RF, ROCCO B, ORVIETO M, SIVARAMAN A, PALMER KJ, KAMEH D, SANTORO L, COUGHLIN GD, LISS M, JEONG W, MALCOLM J, STERN JM, SHARMA S, ZORN KC, SHIKANOV S, SHALHAV AL, ZAGAJA GP, AHLERING TE, RHA KH, ALBALA DM, FABRIZIO MD, LEE DI, CHAUHAN S. Positive surgical margins after robotic assisted radical prostatectomy: a multi-institutional study. *J Urol* 2011;186:511-516.
- 10) CATALONA WJ, SMITH DS. Cancer recurrence and survival rates after anatomic radical retropubic
- 11) Shah J. Robotic surgery. *Cancer Topics* 2006; 12: 14–16.
- 12) Binder J, Kramer W. Robotically assisted laparoscopic radical prostatectomy. *BJU Int* 2001; 87: 408–410.

13) Pasticier G, Rietbergen J, Guillonneau B, Fromont G, Menon M, Vallancien G. Robotically assisted laparoscopic radical prostatectomy: feasibility study in men. *Eur Urol* 2001; 40: 70–74.

14) Abbou C, Hoznek A, Salomon L, Olsson LE, Lobontiu A, Saint F et al. Laparoscopic radical prostatectomy with a remote controlled robot. *J Urol* 2001; 165: 1964–1966.

15) Menon M, Tewari A, Peabody J, The VIP Team. Vattikuti Institute prostatectomy: technique. *J Urol* 2003; 169: 2289–2292.

16) Sim H, Yip S, Lau W, Tan Y, Wong M, Cheng W. Team-based approach reduces learning curve in robot-assisted laparoscopic prostatectomy. *Int J Urol* 2006; 13: 560–564.

17) Herrell S, Smith Jr J. Robotic-assisted laparoscopic prostatectomy: what is the learning curve? *Urology* 2005; 66 (Suppl 5A): 105–107.

18) Walsh P, Donker P. Impotence following radical prostatectomy: insight into etiology and prevention. *J Urol* 1982; 128: 492–497.

19) Guillonneau B, Vallancien G. Laparoscopic radical prostatectomy: the Montsouris technique. *J Urol* 2000; 163: 1643–1649.

20) Rassweiler J, Sentker L, Seeman O, Hatzinger M, Stock C, Frede T. Heilbronn laparoscopic radical prostatectomy: technique and results after 100 cases. *Eur Urol* 2001; 40: 54–64.

21) Joseph J, Rosenbaum R, Madeb R, Erturk E, Patel H. Robotic extraperitoneal radical prostatectomy: an alternative approach. *J Urol* 2006; 175 (3 Pt1): 945–950.

22) Wolfram M, Brautigam R, Engl T, Bents W, Heitkamp S, Ostwald M et al. Robotic-assisted laparoscopic radical prostatectomy: the Frankfurt technique. *World J Urol* 2003; 21: 128–132

Balloon radiation in breast cancer treatment: Advantages, disadvantages and future outlook

Maryam Sadeghi, Department of Medical Engineering, Otto-von-Guericke University, Magdeburg, Germany, maryam.sadeghi@st.ovgu.de

Introduction

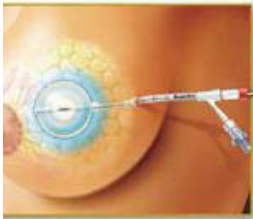

Fig1- The device is placed inside the breast surgical cavity and inflated [1]



Fig2- A single insertion 4 lumen balloon brachytherapy applicator [2]

- For properly selected patients with early stage breast cancer, accelerated partial breast irradiation (APBI) is an alternative treatment method to the conventional whole breast irradiation.
- The Mammosite device is placed inside the breast surgical cavity and inflated with a combination of saline and radiographic contrast to completely fill the cavity.
- Its purpose is to irradiate the tissue immediately surrounding the lumpectomy cavity.
- This technique has been rapidly adopted in both academic centers and in the community, due to its simpler and more accessible technique with more than 20,000 patients treated using this device. (4, 5)

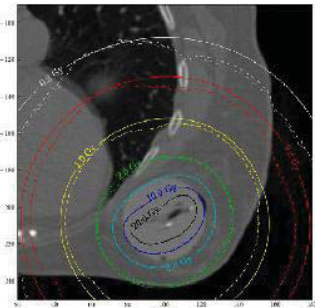
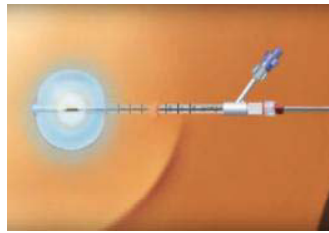
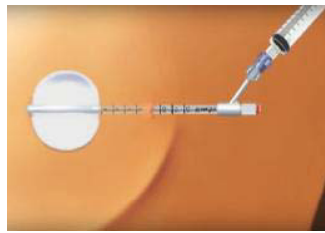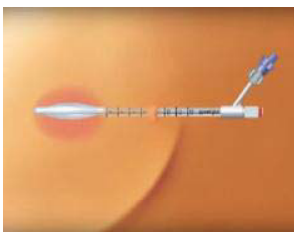
Methods

The MS can be inserted through a single incision site, either at the time of surgery or under ultrasound guidance in a separate procedure.

A balloon tipped catheter is inserted into the resection cavity and inflated to a diameter of 4 to 5 cm.

The inflated balloon shapes and compresses the tissue adjacent to the cavity into a nearly spherical shell surrounding the balloon.

Dose to overlying skin is the main dose-limiting factor for MammoSite treatment.



Dose distributions for a MammoSite 192 Ir HDR implant [4]

Dosimetry: A typical clinical protocol for the MammoSite prescribes a dose of 340 cGy b.i.d. at a distance of 1 cm from the surface of the balloon.

Advantages and disadvantages

Advantages:

- Spare healthy tissue and organs from the effects of radiation
- Allows treatment to be completed in just 5 days instead of 5-7 weeks
- Better quality of life outcomes were reported for patients prescribed with Mammosite when compared to women treated with WBRT
- Feasible and dosimetrically advantageous as compared to an electron boost.

Disadvantages:

- Poor cavity conformance
- Inadequate skin distance limits the use of this approach
- Possible treatment-related toxicities included: Breast seromas, Seroma formation, use of hormonal therapy, breast infection, and A/B cup size were associated with fat necrosis

Results

Outcome:

The applicator performed well clinically in almost all the reviewed articles. Several studies evaluated the value of Mammosite, and now follow-up data of up to 7 years are already available. These reports suggest that Mammosite is comparable to whole-breast irradiation in terms of safety and efficacy. [6]

Local recurrence:

Using the MammoSite balloon in a carefully selected group of patients has demonstrated 5-year local recurrence results comparable to results achieved with conventional WBRT. The suggested risk factors related to local recurrence are: age 40 years or younger, symptomatic detection, cribriform or solid/comedo architecture, nonspecified or close/involved margins, local excision without radiotherapy, high nuclear grade and presence of necrosis.

Removal reasons:

- Inadequate skin distance
- poor cavity conformance
- positive margins
- microinvasion on final pathology
- physician decision
- poor cavity conformance
- positive node.

Conclusion and future outlook

Improvements to Mammosite device should be fulfilled foreseeing the simplicity of insertion and treatment delivery associated with Mammosite. And advance approximating the dose distributions, providing increased dosimetric control, the ability to maximize target coverage, reduce dose to skin and rib and reduce the need for dosimetric compromise.

References

- [1] <http://www.eyephysics.com/palamos/MammoSite>
- [2] <http://www.hologic.com/products/intervention-and-treatment/breast-brachytherapy/mammosite-targeted-radiation-therapy-system>
- [3]
- [4] Tedgren, Åsa Carlsson, Mathieu Plamondon, and Luc Beaulieu. "The collapsed cone algorithm for 192Ir dosimetry using phantom-size adaptive multiple-scatter point kernels." *Physics in medicine and biology* 60.13 (2015): 5313.
- [5]
- [6] Excellent Long-term Breast Preservation Rate after Accelerated Partial Breast Irradiation Using a Balloon Device, Mann et al, 2016, doi: 10.1016/j.clbc.2016.02.010

Review of balloon radiation in breast cancer treatment: Advantages, disadvantages and future outlook

Maryam Sadeghi, Department of Electrical Engineering, Otto von Guericke University

Abstract

Background: For properly selected patients with early stage breast cancer, accelerated partial breast irradiation (APBI) is an alternative treatment method to the conventional whole breast irradiation. The MammoSite radiotherapy system is an option to overcome the longer schedules associated with external beam radiation therapy. The device is placed inside the breast surgical cavity and inflated with a combination of saline and radiographic contrast to completely fill the cavity. The treatment schedule for the MammoSite is 34 Gy delivered in 10 fractions at 1.0 cm from the balloon surface with a minimum of 6 hours between fractions on the same day.

Material and methods: This review article presents the advantages, disadvantages, uncertainties and clinical outcomes associated with the MammoSite brachytherapy.

Results: Potential advantages of Mammosite are: high localized dose, minimum delay between surgery and RT, catheter moves with breast, improved local control, no exposure to staff, likely side-effects reduction and potential cost/time saving. The optimal cosmetic results depend on the balloon-to skin distance. Good-to-excellent cosmetic results are achieved for patients with balloon-skin spacing of 7 mm. The available data on the local control achieved with the Mammosite were comparable with other accelerated partial breast irradiation techniques. The contrast medium inside the balloon causes dose reduction at the prescription point.

Conclusion: Initial clinical results have shown that the MammoSite device could be used as a sole radiation treatment for selected patients with early stage breast cancer providing minimal recurrence rates, minimal complication rates and excellent cosmesis. The future aspects of the device is also discussed in the study.

Key Words: *Mammosite, Accelerated partial breast irradiation, brachytherapy, Balloon radiation*

Introduction:

Breast conservation therapy is an alternative to mastectomy for patients with Stage I and II breast cancer. The current standard of care for breast conservation therapy includes a post-lumpectomy course of whole-breast external beam radiotherapy, which typically requires 5–7 weeks to complete. The purpose of radiotherapy is to prevent recurrence by eliminating residual foci of cancer that remains in the surrounding breast tissue. (1) The treatment trend is shifting away from whole breast radiation towards partial breast radiation for women with early breast cancer. (2, 3) to overcome the

presented by a 5-7 week treatment course required for external beam radiation. Partial breast irradiation (PBI) is used by several institutions to treat patients with early breast cancers. (3, 4)

The MammoSite (MS) brachytherapy catheter is the first balloon-based brachytherapy device developed for PBI in the USA and is commercially available, since 2002. It is a dual lumen catheter with a spherical inflatable silicone balloon, which is placed in the lumpectomy cavity. The central lumen has a port, which is connected to a loaded high-dose-rate (HDR) Iridium-192 source in the center (Fig. 1, 2). (4, 5, 6)

The balloon is inflated with 30–70 mL of sterile saline or a mixture of saline and radiographic contrast agent until it fills the lumpectomy cavity. The catheter is removed on the fifth day at the end of the MammoSite treatment. (1, 7)

This technique has been rapidly adopted in both academic centers and in the community, due to its simpler and more accessible technique with more than 20,000 patients treated using this device. (4, 5)

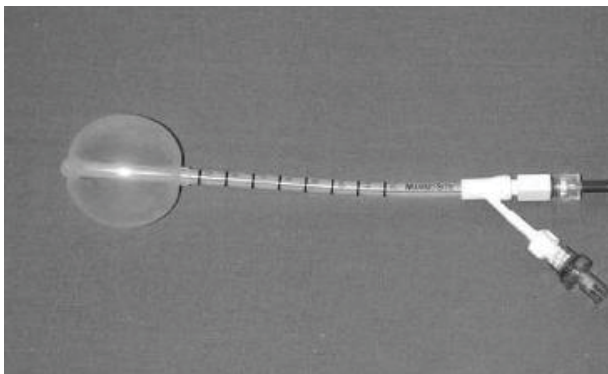


Fig. 1. MammoSite balloon applicator with two connectors. One port is for the injection and the other is for passage of the Ir-192 source.

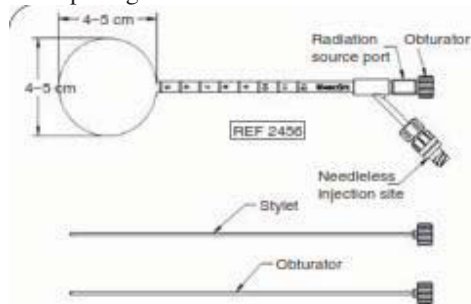


Fig.2.

Mammosite structue

Dosage:

A typical clinical protocol for the MammoSite includes a dose of 340 cGy b.i.d. at a distance of 1 cm from the surface of the balloon, with a minimum of 6 hours between fractions over 5-7 days. (1, 4, 6, 7, 8, 9, 10, 11, 12, 13, 14, 15, 16, 17, 18)

Treatment with Mammosite applicator provides dosimetrically acceptable plans

when used appropriately, but during the radiation organs including the skin and ribs adjacent to the lumpectomy cavity, the lungs and the heart receive more radiation. (1, 4, 6, 8, 9) Therefore radiation dose to these structures should be monitored and reduced if possible.

Dickler et al found that the mean maximal skin dose per fraction in the excellent cosmetic outcome group was 354.8 cGy and the mean maximal skin dose per fraction in the good cosmetic outcome group was 422.3 cGy. Therefore skin distance can be considered a surrogate for skin dose. (4)

According to Astrahan et al, a constraint of 340 cGy/fraction to the skin was found to be acceptable but it may be feasible to push the skin dose limit up to about 450 cGy/fraction if a more accurate determination of the point on the skin closest to the balloon can be ensured. (1)

Valakh et al, demonstrated that the mean cardiac dose in balloon-based HDR brachytherapy patients is, on average, less than 3.3 Gy. However, these low doses may result in clinically relevant late cardiac toxicity. (9)

Dose homogeneity has been reported somewhat better for MSB than conventional radiography based IB. (6)

Strohmaier et al, studied the ^{60}Co instead of ^{192}Ir sources despite their identical shape and dimensions have different physical characteristics, they show identical dose distributions, as demonstrated in various studies. The results of their work showed no advantages or disadvantages exist for ^{60}Co sources compared to ^{192}Ir sources with regard to clinical aspects. (19)

The use of contrast material inside the MammoSite balloon decreases the dose rate in the PTV region. This filtering effect, which hardens the beam, is more pronounced for ^{192}Ir , which has a lower photon energy spectrum when compared to ^{192}Ir . The ^{192}Ir HDR sources can be a

viable replacement for Ir-192 HDR sources in breast brachytherapy treatment using the MammoSite device as cited by Cazeca et al. (7)

It is recommended that, the received dose for other organs be routinely examined and reported so that its correlation with toxicity data can be available in the future.

Implantation:

The MS can be inserted through a single incision site, either at the time of surgery or under ultrasound guidance in a separate procedure. Initial reports used radiation plans with a simplified single dwell position, single prescription point technique, which works well for busy centers or centers with limited physics support. (4)

In study of Benitez et al, an 85% rate of implant to treatment was achieved. They also suggested that it may be possible to increase the implant-to-treatment ratio further if catheters are placed postlumpectomy. Postlumpectomy

placement is an additional procedure for the patient but can be accomplished in the office or procedure suite with ultrasound guidance with relative ease. In the experience of Zannis et al, an implant-to-treatment ratio of 91% was achieved with postlumpectomy placement. It is anticipated that with increasing experience a higher implant-to-treatment ratio will be accomplished. (20)

Poor cavity conformance and inadequate skin distance were the main factors limiting use of the MammoSite device in Benitez et al, study. (5)

Removal reasons, explantation:

The MammoSite balloon catheter was removed in several articles for different reasons.

Inadequate skin distance, poor cavity conformance, positive margins, microinvasion on final pathology, physician decision, poor cavity conformance, positive node, and age less than 45 years are the reasons cited for catheter explantation. (5, 20) The major reasons for explantation were inadequate skin distance and poor cavity conformance, accounting for 71% of the catheters removed. In the American Society of Breast Surgeons (ASBS) registry data, 20% of balloons that were removed were a result of inadequate margins and final pathology. (1)

Outcome:

The publications concerning the use of MammoSite device have shown a positive safety profile and good to excellent cosmesis outcome and association with low rates of local recurrence in patients. Since FDA approval of this device in May 2002, Mammosite use has rapidly expanded. More than 1000 procedures were performed in the first 8 months after FDA approval for clinical use. (1, 4, 5, 20, 21, 22) The applicator performed well clinically in almost all the reviewed articles.

Several studies evaluated the value of Mammosite, and now follow-up data of up to 7 years are already available. These reports suggest that Mammosite is comparable to whole-breast irradiation in terms of safety and efficacy. (5, 6, 13) Better quality of life outcomes were reported for patients prescribed with Mammosite (specifically, women treated with multi-lumen catheter-based) when compared to women treated with WBRT. (23, 24)

In a study by Benitez et al, patients were queried if they would use the MammoSite brachytherapy treatment again, or if they would recommend MammoSite balloon brachytherapy to a friend or family member, 100% responded affirmatively. (5)

Albuquerque et al, compared the effect of adjuvant whole breast radiation therapy (WBRT) versus partial breast radiation therapy (PBRT) on fatigue, perceived stress, quality of life and natural killer cell activity. They concluded that PBRT resulted in lower radiation and therefore to less fatigue and higher quality of life after radiation therapy compared to WBRT. (25)

The Mammosite device has the largest number of patients treated for any existing partial breast irradiation modality (2) and according to various studies reviewed, Mammosite is a safe, feasible, well tolerated and efficacious alternative to WBRT.

Recurrence:

In the structure of MammoSite placed in the lumpectomy cavity, no tissue is present in the near field of a source. This space is instead occupied by the fluid or contrast that inflates the balloon. The maximum dose to surrounding tissues occurs in the tissue compressed against the balloon surface. This is precisely the tissue apparently at greatest risk of recurrence. (1)

Nevertheless, radiation using the MammoSite balloon in a carefully selected group of patients has demonstrated 5-year local recurrence results comparable to results achieved with conventional WBRT. No local recurrences (either at the tumor bed or elsewhere in the breast) or regional recurrences have occurred in 5years of follow up. (5)

The suggested risk factors related to local recurrence are: age 40 years or younger, symptomatic detection, cribriform or solid/comedo architecture, nonspecified or close/involved margins, local excision without radiotherapy, high nuclear grade and presence of necrosis. (20)

Advantages:

The characteristics listed below are the main reasons for acceptance of the Mammosite device by the medical community as an

effective means of delivering partial breast irradiation:

- Shortened treatment period compared to WBRT (less than 1 week vs. 6–7 weeks) (6, 26)
- The reduced irradiated breast tissue, which may translate into less toxicity to the surrounding tissue and organs. (5, 6)
- Only one applicator is implanted and the treatment planning is relatively simple. (6, 21)
- Feasible and dosimetrically advantageous as compared to an electron boost. (12)
- High localized dose
- Minimum delay between surgery and RT
- Catheter movement with breast
- No exposure to staff
- Likely side-effects reduction
- Potential cost saving (e.g. for country patients). (27)

Limitation and disadvantages:

The main factors limiting use of the MammoSite device are:

- Poor cavity conformance
- inadequate skin distance (5)

Toxicity and side effects:

Toxicity is a result of skin dose, radiation hot spots, and balloon size. Reports studying Mammosite overall suggest minimal treatment-related toxicities similar to other forms of APBI.

Minor side effects are reported in the reviewed studies. Benitez et al reported an infection rate of 9.3%. Seroma formation occurred in 32.6% of patients, of which 12% were symptomatic requiring aspiration. The only serious adverse events were 2 infections: mastitis and abscess. Retraction of the breast and/or nipple was reported in 20.9%. (5)

Patients experienced only mild-to-moderate side effects in a study by Keisch et al, including skin erythema (57%), dry desquamation (13%), and moist desquamation (5%). Their trial detected no severe device-related adverse events. The only four potentially device-related events reported, including an abscess and 3 seromas, were all self-limiting and resolved. (21)

Treatment-related toxicities included: Breast seromas, Seroma formation, use of hormonal therapy, breast infection, and A/B cup size were associated with fat necrosis in a study by Khan et al. (17)

A cancer induction model was simulated in MATLAB by Santos et al, to estimate the LAR (lifetime attributed risk) of SPC (second primary cancers) formation after exposure to ionizing radiation. The lungs, liver and contralateral breast showed high LAR estimates. Overall, results show that the APBI technique leads to the lowest risk estimate for SPC formation. (28)

Despite of all these reports toxicity can be lowered with newer multicatheter applicators, appropriate patient selection, and closed (ultrasound-guided) catheter insertion techniques. (10) Skin spacing and the small high-dose volumes were suggested to strongly correlate with cosmetic outcome; the greater the skin spacing, the better the cosmetic outcome. (5, 16)

Shah et al, expressed the only method for lowering skin toxicity as maintenance of as large a distance as possible between the device and the skin. (15)

Improvements and future:

As in every procedure, there is always room for improvements for Mammosite. As discussed above cosmetic outcomes can be improved, with increased skin spacing having statistical significance at skin spacing 7 mm.

Multi- lumen and multi catheter Mammosites were developed to improve the limitations of the single-lumen MammoSite system's fixed geometry and inflexibility to sculpt dose. (16) In MammoSite technique, verification of balloon symmetry, balloon/cavity conformance and overlying skin thickness is essential to assure target coverage and toxicity avoidance. (26) The results show that the MultiCatheter method is associated with significantly lower skin and chest wall dose than is the MammoSite. The Multi- Catheter technique is more flexible and can be applied to any size of breast or lumpectomy cavity. By introducing multiple lumen, these applicators have a greater capability to shape the dose distribution through optimization of sourced well positions and dwell times. (1, 11) These catheters may also offer women better breast cosmesis and decreased toxicity with increased time following their treatment. (24)

The ClearPath (CP) multicatheter hybrid device was developed in an effort to improve the technique of partial breast irradiation to offer the advantages of both intracavitary and interstitial brachytherapy. The hybrid CP catheter reduced the skin dose significantly. The use of this device has the potential to increase the applicability of APBI in patients with a surgical cavity close to skin compared with balloon brachytherapy. (14)

To correct the shortcomings of the single point method, Dickler et al, developed the six prescription point, multiple dwell position technique (RUSH Technique). In this technique, six optimization points are placed 1 cm from the balloon surface. Four points are placed in a plane transverse to the balloon axis perpendicular to the axis of the catheter and two points are also placed along the axis of the catheter. The six point method was found to improve dose coverage compared with the single point technique.

Dickler et al, feel that RUSH Technique offers the best compromise between a method that accounts for source anisotropy, partially accounts for the 3-D shape of the inflated balloon, and a method that is not technically difficult to utilize. (29)

Astrahan *et al*, showed that by varying the number and arrangement of dwell positions, the shape of the isodose lines could be modified. (29)

Ouyang et al, results indicate that CONPs (cerium oxide nanoparticles) can be employed for radioprotection during APBI. The presence of CONPs in normal breast tissue has the potential to reduce radiation side effects by eliminating reactive oxygen species without causing additional damage. Using 2 nm sized NPs, with an initial concentration of 1 mg.gr^{-1} , we found that 2–10 days of diffusion is required to obtain desired concentrations of CONPs in regions 1–2 cm away from the lumpectomy wall. (30)

Strohmaier et al, suggest that no advantages or disadvantages exist for ^{60}Co sources compared to ^{192}Ir sources with regard to clinical aspects. Despite the fact that ^{60}Co and ^{192}Ir sources of identical shape and dimensions have different physical characteristics, they show identical dose distributions. Nevertheless, there are potential logistical advantages of ^{60}Co sources due to its longer half-life (5.3 years vs. 74 days), makes it an interesting

alternative especially in developing countries. (19)

Improvements to Mammosite device should be fulfilled foreseeing the simplicity of insertion and treatment delivery associated with Mammosite. And advance approximating the dose distributions, providing increased dosimetric control, the ability to maximize target coverage, reduce dose to skin and rib and reduce the need for dosimetric compromise. A desirable time-saving feature designed for MammoSite dosimetry would be the ability to automatically find the closest point on the surface of a region of interest, such as skin or lung, to the balloon surface. Regarding toxicity, optimization techniques that exploit catheter axis orientation, source anisotropy, dwell position, dwell weighting, and balloon diameter may be used to constrain the dose to the overlying skin while preserving the prescribed dose to as much of the region as possible. To customize Mammosite based on location and shape of the cavity and thus having potential to offer APBI to a larger subset of patients is practicable. The use of contrast material inside the MammoSite balloon decreases the dose rate at the prescription point. (7) Usage of different fluids as contrast might decrease the toxicity. Change of the shape and symmetry of the balloon may also result in better outcome.

Shah et al, 2012, doi:
10.1016/j.brachy.2012.01.008

4. A dosimetric comparison of MammoSite_ and ClearPath high-dose-rate breast brachytherapy devices, Dickler et al, 2007, doi: 10.1016/j.ijrobp.2007.07.261

5. Five-year results: the initial clinical trial of Mammosite balloon brachytherapy for partial breast irradiation in early-stage breast

References:

1. Optimization of Mammosite therapy, Astrahan et al, 2004, doi: 10.1016/s0360-3016(03)01458-5

2. Mammosite, Martin Keisch, 2005, doi: 10.1586/17434440.2.4.387

3. Comparison of survival and regional failure between accelerated partial breast irradiation and whole breast irradiation,

- cancer, Benitez et al, 2007, doi:
10.1016/j.amjsurg.2007.06.010
6. Dosimetric comparisons between high dose rate interstitial and MammoSite balloon brachytherapy for breast cancer, Major et al, 2006, doi:
10.1016/j.radonc.2006.05.005
7. Effects of breast-air and breast-lung interfaces on the dose rate at the planning target volume of a MammoSite® catheter for Yb-169 and Ir-192 HDR sources, Cazeca et al, 2010, doi: 10.1118/1.3458720
8. Equivalent uniform dose for accelerated partial breast irradiation using the MammoSite applicator, Stewart et al, 2013, doi: 10.1016/j.radonc.2013.06.030
9. A comprehensive analysis of cardiac dose in balloon-based high-dose-rate brachytherapy for left-sided breast cancer, Valakh et al, 2012, doi:
10.1016/j.ijrobp.2011.02.058
10. Extended (5-year) Outcomes of Accelerated Partial Breast Irradiation Using MammoSite Balloon Brachytherapy: Patterns of Failure, Patient Selection, and Dosimetric Correlates for Late Toxicity, Vargo et al, 2013, doi:
10.1016/j.ijrobp.2013.05.039
11. Dosimetric experience with 2 commercially available multilumen balloon-based brachytherapy to deliver accelerated partial-breast irradiation, Fu et al, 2014, doi:
10.1016/j.meddos.2014.11.005
12. A dosimetric analysis comparing electron beam with the MammoSite brachytherapy applicator for intact breast boost, Shah et al, 2010, doi:
10.1016/j.ejomp.2009.08.004
13. Excellent Long-term Breast Preservation Rate after Accelerated Partial Breast Irradiation Using a Balloon Device, Mann et al, 2016, doi: 10.1016/j.clbc.2016.02.010
14. Multicatheter hybrid breast brachytherapy: A potential alternative for patients with inadequate skin distance, Beriwal et al, 2008, doi:
10.1016/j.brachy.2008.07.003
15. MammoSite and Interstitial Brachytherapy for Accelerated Partial Breast Irradiation, Factors that Affect Toxicity and Cosmesis, Shah et al, 2004, doi:
10.1002/cncr.20424
16. Comparative dosimetric findings using accelerated partial breast irradiation across five catheter subtypes, Rana et al, 2015, doi:
10.1186/s13014-015-0468-7
17. Six-Year Analysis of Treatment-Related Toxicities in Patients Treated with Accelerated Partial Breast Irradiation on the American Society of Breast Surgeons MammoSite Breast Brachytherapy Registry Trial, Khan et al, 2012, doi: 10.1245/s10434-011-2133-1_
18. Angiosarcoma and Breast Cancer Recurrence Eight Years Following Mammosite Therapy, Mansfield et al, 2014, doi: 10.1111/tbj.12337
19. Comparison of 60Co and 192Ir sources in HDR brachytherapy, Strohmaier et al, 2011, doi: 10.5114/jcb.2011.26471
20. Preliminary results and evaluation of MammoSite balloon brachytherapy for partial breast irradiation for pure ductal carcinoma in situ: a phase II clinical study, Benitez et al, 2006, doi:
10.1016/j.amjsurg.2006.06.013

21. Initial clinical experience with the Mammosite breast brachytherapy applicator in women with early-stage breast cancer treated with breast-conserving therapy, Keisch et al, 2003, doi: 10.1016/s0360-3016(02)04277-3
22. Clinical outcomes with the Mammosite radiation therapy system: Results of a prospective trial, Small et al, 2015, doi: 10.1007/s13566-015-0228-1
23. Long-term followup of breast preservation by re-excision and balloon brachytherapy after ipsilateral breast tumor recurrence, Trombetta et al, 2014, doi: 10.1016/j.brachy.2014.05.017
24. WBRT vs. APBI: an interim report of patient satisfaction and outcomes, Bitter et al, 2016, doi: 10.5114/jcb.2016.57816
25. Impact of partial versus whole breast radiation therapy on fatigue, perceived stress, quality of life and natural killer cell activity in women with breast cancer, Albuquerque et al, 2012, doi: 10.1186/1471-2407-12-251
26. A Comparison of Skin Dose Delivered with MammoSite and Multicatheter Breast Brachytherapy, Oshaghi et al, 2013
27. Review of MammoSite brachytherapy: Advantages, disadvantages and clinical outcomes, Bensaleh et al, 2009, doi: 10.1080/02841860802537916
28. Risk estimation of second primary cancers after breast radiotherapy, Santos et al, 2016, doi: 10.1080/0284186x.2016.1185150
29. The MammoSite breast brachytherapy applicator: A review of technique and outcomes, Dickler et al, 2005, doi: 10.1016/j.brachy.2004.12.003
30. Potential of using cerium oxide nanoparticles for protecting healthy tissue during accelerated partial breast irradiation (APBI), Ouyang et al, 2016, doi: 10.1016/j.ejmp.2016.03.014



and available to treat Atherosclerosis

E. Avcioglu, Department of Medical Engineering, Otto-von-Guericke University, Magdeburg, Germany with the support of M. Friebe, Department of Catheter Technologies, Otto-von-Guericke University, Magdeburg, Germany
Contact: erdinc.avcioglu@ovgu.de

Introduction

Atherosclerosis - The leading cause of death

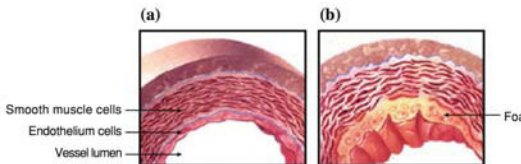


Fig. 1: Healthy Arterial Wall (a) and an arterial wall with atherosclerotic lesion (b) caused by foam cells [1]

Facts about Atherosclerosis

- Chronic vascular disease
- developing very slowly and stays a long period of time symptomless
- accumulation of cholesterol at arterial macrophages
- Reduction of inner arterial lumen
- Reduction/ Blockage of blood flow

↓
Myocardial infarction (heart attack), stroke or other serious conditions

Challenges

- Early detection needed (prevent Patients from death)
- Harmless Diagnosis and Therapy
- Preventing Restenosis after Revascularization procedure

Aim of this poster

Give an overview about available and needed tools in interventional treatment and diagnosis of Atherosclerosis

Diagnostic and Therapy Tools

A lot of diagnostic tools for detection of Atherosclerosis were developed in the last years and also many new high promising technologies are in the developing state (see Fig. 2 - Fig. 7).

Diagnostic Tools

Conventional angiography

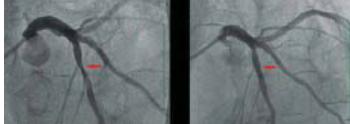


Fig. 2: Angiogram of a lesion in the left anterior descending artery before an intervention (left) and after an intervention (right) [2]

Magnetic resonance imaging (MRI)

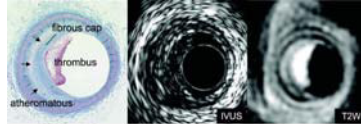

Fig. 3: Comparison between histological (left) IVUS (middle) and MRI (right) images of an atherosclerotic lesion [4]

Intravascular ultrasound (IVUS)

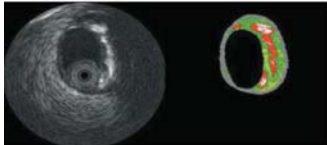


Fig. 4: IVUS image (left) and corresponding tissue map (right) black part of the image represents the inner lumen, dark green is fibrous tissue, light green fatty tissue, red is necrotic core and white is dense calcium [3]

Near infrared spectroscopy (NIRS)

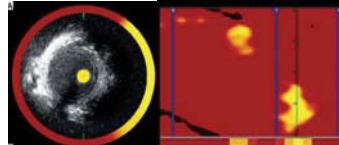


Fig. 5: IVUS image combined with Near infrared spectroscopy (NIRS) information (left) chromogram of NIRS (right) yellow represents locations of high and red of low probability of lipid presence [2]

Optical Coherence Tomography (OCT)

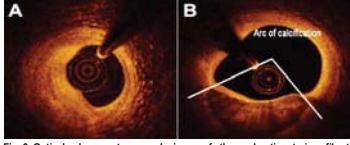


Fig. 6: Optical coherence tomography image of atherosclerotic arteries; fibrotic stable plaque (A) calcification (B) [5]

Intravascular palpography

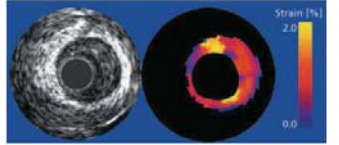


Fig. 7: IVUS image (left) and Intravascular palpography map (right); higher percentage of strain is concentrated to weaker points, with higher rupture risk [3]

Therapy methods and tools

Lifestyle modification and pharmacological treatment

Interventional or Surgical Revascularization procedures

- Coronary artery bypass grafting
- Percutaneous Coronary Intervention

Stenting tools

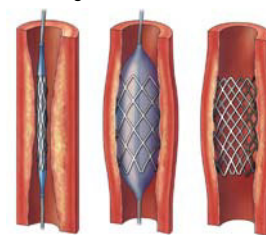


Fig. 8: Stent placement with a balloon catheter. Balloon catheter is inserted in a deflated state (left); balloon catheter is inflated (middle); balloon catheter is removed and stent remains in the artery (right) [6]

Atherectomy devices




Fig. 9: Atherectomy device with rotational tip, aspiration and infusion ports [7]

Thrombectomy devices

Are used for aspiration of thrombus during percutaneous coronary intervention (PCI).

Unsolved problems and needed tools

Despite the fact that a lot of tools are available, there are still needed tools for unsolved problems like Restenosis or late stent Thrombosis after PCI (Fig. 10). A Lithoplasty balloon catheter (Fig. 11) could reduce thrombus, perforations or distal embolization events. Recent improvements of atherectomy devices which are rotating in a shape of an elliptical orbit are reducing the target lesion revascularization significantly (Fig. 11).

Main unsolved Therapy problem

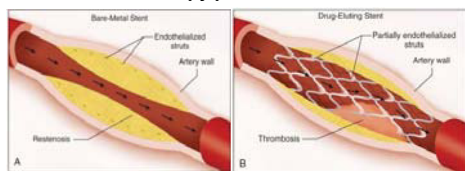


Fig. 10: Comparison of complications with a bare-Metal stent - Restenosis risk (A) and a Drug-eluting stent - Late stent thrombosis (B) [8]

Newer Therapy approaches

- Lithoplasty balloon catheter (Fig. 11)
- Elliptical rotating Atherectomy device (Fig. 12)
- Thermal treatment
- Photodynamic therapy



Fig. 11: Orbital atherectomy catheter with diamond coated eccentric shaped crown [9]

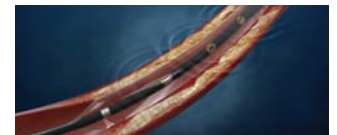

Fig. 12: Lithoplasty balloon catheter with small electrodes on its surface which deliver ultrasound shockwaves to break up calcified plaques [10]

Conclusion and Future Outlook

Numerous diagnostic and therapy tools are available or still under research. The major goal of the newer diagnostic techniques is providing early diagnosis and characterization of plaque composition to assess the rupture risk. From the therapeutic point of view, tools are needed which can prevent restenosis caused by bare metal stents or late stent thrombosis caused by drug eluting stents after PCI. When the benefits of the newer methods get clinically proven and a successful translation will occur, there is high promise that in the near future a much more optimal diagnosis for atherosclerosis will exist. Especially because of the molecular imaging capability by considering that the origin of atherosclerosis is of molecular nature. Due to its selectivity Photodynamic therapy could be a future treatment technology in Atherosclerosis for preventing restenosis.

References

- [1] A. Haber, "Atherosclerosis," in *Metallocomplexes for Attenuation of Atherosclerosis*, Berlin Heidelberg, Springer-Verlag, 2012, pp. 17-27.
- [2] M. Horvath, P. Hajek, C. Stechovsky, J. Honok and E. al., "The role of near-infrared spectroscopy in the detection of vulnerable atherosclerotic plaques," *Arch Med Sci*, Bd. 12, Nr. 6, p. 1308-1316, 2014.
- [3] V. Mani, A. Chowdhury, V. Johan and A. Patel, "Ultrasound detection of coronary disease," in *The Vulnerable Atherosclerotic Plaque: Strategies for Diagnosis and Management*, Singapore, Blackwell Publishing, 2007, pp. 211-221.
- [4] H. Yasuhiro and F. Peter, "Frontiers in Intravascular Imaging Technologies," *Circulation*, Nr. 117, pp. 2024-2037, 2008.
- [5] N. Shah, P. Howlett, D. Fluck, M. Williams, A. Jacques and M. Mahmoudi, "Optical Coherence Tomography in Coronary Atherosclerosis," *MOJ Anatomy & Physiology*, 23 July 2015.
- [6] *Britannica*, [Online]. Available: <https://www.britannica.com/science/aneurysm/images-videos/The-insertion-of-a-stent-into-a-coronary-artery-where/106616>. [Access: 18th January 2017].
- [7] *Radiologykey*, [Online]. Available: <http://www.radiologykey.com/ivus/products/atherectomy-systems/jetstream-atherectomy-system.html>. [Access: 18th January 2017].
- [8] *Radiologykey*, [Online]. Available: http://radiologykey.com/wp-content/uploads/2015/12/B978141605335400037X_4.jpg. [Access: 18th December 2016].
- [9] *Diagnostic and Interventional Cardiology*, "New Technologies to Treat Peripheral Artery Disease (PAD)," 2016 February 2016. [Online]. Available: <http://www.dicardiology.com/article/new-technologies-treat-peripheral-artery-disease-pad>. [Access: 18th December 2016].
- [10] *medGadget*, "medGadget," 09 January 2015. [Online]. Available: <http://www.medgadget.com/2015/01/shockwave-pad-balloon-catheters-with-lithoplasty-technology-ce-marked-video.html>. [Access: 18th December 2016].

Stenosis – Interventional and Diagnostic Tools and Systems needed and available to treat Atherosclerosis

Erdinç Avcıoğlu, Faculty of Electrical Engineering and Information Technology, Otto-von-Guericke University Magdeburg, erdinc.avcioglu@hotmail.com

Abstract— Due to the fact that Atherosclerosis is the leading cause of death, a huge number of diagnostic procedures are on the market or in the developing state. This paper provides a comprehensive overview of available diagnostic and interventional tools for treating Atherosclerosis. Moreover, still needed improvements will be identified and the current situation is evaluated. Real time imaging methods with detailed morphological information are shown and discussed. Advancements like targeted contrast agents which allow the characterization of plaque composition are compared due to their significance. The differentiation between different soft tissue layers are considered. The possible use of Imaging modalities with molecular imaging capability are presented and the opportunity of offering earlier diagnosis is analyzed. The effects of different therapy tools on standard revascularization procedures are discussed. Different types of stents are compared and discussed about alternatives.

Index Terms—Atherosclerosis, Percutaneous Coronary Intervention, Stenosis, Vessel Revascularization

I. INTRODUCTION

ATHEROSCLEROTIC cardiovascular disease (ACVD) is the leading cause of death in industrial nations [1]. In the developing world the number of deaths caused by ACVD like ischemic heart disease and atherothrombotic stroke is lower, but increasing rapidly. A prognosis shows that in the year 2025 80 – 90 % of all cardiovascular diseases will be in the developing countries [2].

Atherosclerosis is a chronic vascular disease. In most cases it is developing very slowly and stays a long period of time symptomless. The disease starts with an accumulation of cholesterol at arterial macrophages which are then transformed into lipid loaded foam cells. As a next step these foam cells attach to arterial walls and cause a thickening which reduces the inner arterial

lumen. At the same time the artery walls are losing their elasticity because of the cholesterol sedimentation on the endothelial cells [3].

A decrease of the artery lumen causes a reduction in blood flow up to a complete blockage of the artery. Major affected arteries are coronary arteries, cerebral arteries and the aorta. A blockage of one of these arteries can cause myocardial infarction (heart attack), stroke or other serious conditions. Risk factors for atherosclerosis are smoking, hypertension, diabetes mellitus, genetic factors, unhealthy blood cholesterol levels, overweight, older age and the lack of physical activity [4].

Early detection of atherosclerotic lesions in the cardiovascular System can prevent most of the patients from death [1]. This fact makes clear that the focus of new medical diagnostic approaches should be on providing early, easy and harmless diagnosis of asymptomatic atherosclerosis. For this reason, the paper will give an overview of available diagnostic and interventional tools for treating Atherosclerosis and will try to identify still needed tools which are not yet on the market. The main goal of this tools should be offering earlier diagnosis and a safer and more individual treatment of ACVD.

II. STANDARD DIAGNOSTIC METHODS

Invasive x-ray angiography is still the gold standard for anatomic imaging of stenosis caused by Atherosclerosis [5]. Most often coronary, carotid or peripheral angiography is done. For this kind of procedures, a thin catheter is inserted through the femoral artery at the groin (most often) up to the region of interest. The catheter is used to inject a contrast media to these regions. Under x-ray fluoroscopy the contrast media becomes well visible and offers a high diagnostic accuracy with a spatial resolution of 0.1 - 0.2 mm and temporal resolution of 10 ms [5]. With these properties x-ray angiography is the most accurate anatomic

4th of January 2017

E. A. Author is with the Electrical Engineering and Information Technology Department, University of Magdeburg, Saxony-Anhalt, Germany (e-mail: erdinc.avcioglu@ovgu.de).

imaging technique to outline the stenosis caused by plaque on the arterial wall [5].

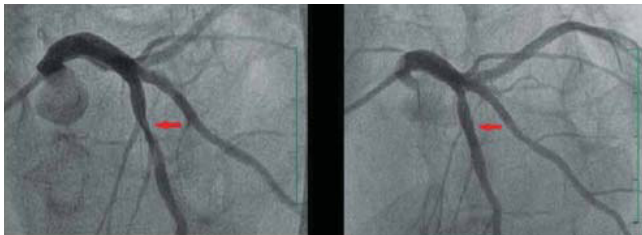


Fig. 1: Angiogram of a lesion in the left anterior descending artery before an intervention (left) and after an intervention (right) [6]

Angiography is also done noninvasive with computed tomography or magnetic resonance imaging. These methods are called coronary computed tomographic angiography (CCTA) and magnetic resonance angiography (MRA).

III. ALTERNATIVE DIAGNOSTIC APPROACHES WITH FUTURE PERSPECTIVE

A lot of special diagnostic strategies are available to detect Atherosclerosis. The most common and important ones are described in the following part.

A. Intravascular Ultrasound (IVUS)

IVUS is a catheter based ultrasound system which provides real time images of existing plaque and vessel morphology. There are 3 types of plaque which can be identified by this technique. Soft plaques with large lipid core, calcium containing plaque and a combination of lipid and fibrous tissue. Soft Plaque can be recognized by echolucent Signals which are displayed as black pixels on the screen. Echobright Signals with additional shadowing effect behind the plaque are interpreted as calcium layers, which are displayed as brighter pixels. The mixture of echolucent and echobright signals are understood as plaque which contains a combination of lipid and fibrous tissue [7].

The disadvantages of this technique are the invasiveness and that no cellular or molecular imaging is possible. Echolucency could also be achieved due to necrosis or thrombus. However it is valuable in outlining plaque morphology and classifying key indicators of instability and is the most widely available ultrasound tool for this purpose [7]. As a conclusion it can be said that “IVUS is useful but not conclusive or comprehensive” [7] for the diagnosis of atherosclerosis.

B. IVUS with targeted contrast agents

An advancement of conventional IVUS imaging is to combine the IVUS imaging with intravenous injected

targeted contrast agents with the shape of microspheres (microbubbles). These microspheres are filled with gas and with different ligands attached to the surface of their thin shell. The ligands can bind to disease specific molecules. In the case of atherosclerosis this molecules could be leukocyte adhesion molecules on the endothelial cells of inner arterial walls which are caused by inflammation processes [8]. Recent research shows that also nanoscale echo-reflective liposomes can be used as targeted contrast agents [7].

This method is also still invasive but would allow to use ultrasound for molecular imaging in atherosclerosis diagnosis and differentiate between different types of atherosclerotic plaque.

C. IVUS for plaque characterization

A study shows that backscattered spectra of ultrasound waves are related to the underlying tissue layers [9]. Therefore compared to standard IVUS imaging where the plaque characterization is done by image analysis the composition of plaque can be analyzed more precisely by the interpretation of the backscattered spectrum [10]. Fig. 2 shows such a tissue map of a corresponding IVUS image based on spectral analysis. The black part of the image represents the inner lumen, dark green is fibrous tissue, light green fibro-fatty tissue, red is necrotic core and white is dense calcium.

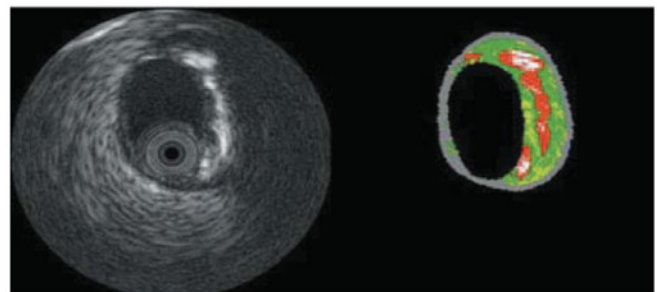


Fig. 2: IVUS image (left) and corresponding tissue map (right) [7]

The spectral analysis is done with intravascular ultrasound machines which are providing phased-array transducers, where the analyzing system is built in and only needs an ECG input to synchronize the images to the heart beat [7].

D. Non Invasive external MRI & Intravascular magnetic resonance imaging (IMRI)

Non Invasive external MRI is the most precise technique in characterization different layers of soft tissue like the atherosclerotic components of lipids, fibrous tissue, calcium and Thrombus formation [11]. It can also detect thickenings at early stages of the atherosclerotic process [12]. Fig. 3 shows a comparison

between a histological image which illustrates the real anatomical structure, an IVUS image and a T2 weighted MRI image of an artery. It is easy to see that the contrast between the soft tissue layers is higher in the MRI image than in the IVUS image.

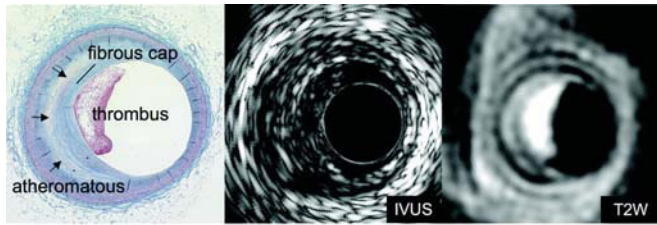


Fig. 3: Comparison between histological (left) IVUS (middle) and MRI (right) images of atherosclerotic lesions [13]

Furthermore, it is easier to see the similarity to the histological image than in the IVUS image.

One of the disadvantages is the signal to noise ratio (SNR) which is decreasing with higher distances of the vessels from the RF-Coils. This is mostly the case for smaller vessel sizes like tiny branches of the coronary arteries. Therefore, external non-invasive MRI is only useful for large arteries like the Aorta, the carotid arteries and some major branches of the coronary arteries [12]. With decreasing SNR also, the image resolution is decreasing, which is the major limitation of this method.

An advancement of this approach for above mentioned problem are intravascular catheter based MRI-Coils which can be inserted into the arteries and are built to use for deeper lying small arteries like some coronary branches. Another advantage of this procedure is that it is not affected by cardiac motion in comparison to external MRI Application. The intravascular MRI system is composed of a probe which is integrated at the tip of the vascular catheter and a transportable control unit. Magnets, RF-Coil and corresponding electronics are included in the IMRI probe. For such a portable IMRI System is no external magnetic field or coils necessary. Fig. 4 shows the IVMRI catheter probe with integrated low pressure fixation balloon. This fixation method is used to achieve higher resolution because of less motion of the coil tip. When the catheter is fixed, the probe scan in a section shaped lateral view of 60°. The MR diagram which is shown in the right, illustrates the lipid fraction (LF) based on the diffusion coefficient of the MR signal. The LF is the percentage of lipid in the imaged arterial wall. Blue areas in the diagram mean that the LF is decreased and yellow areas mean that the LF in these regions are increased. These calculated regions are correlating to 90 % with the histological information [14]. However, the clinical use of this technique is very limited because of the invasive procedure, size of the

catheter and the time consuming scan. Nevertheless, there is still research necessary to make this procedure optimal and usable in a clinical routine.

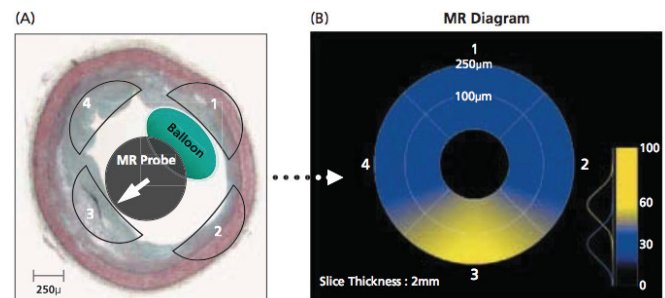


Fig. 4: Intravascular MRI catheter probe with inflatable balloon fixation mechanism (left), corresponding MR diagram based on the diffusion coefficient (right) [12]

E. Radionuclide Imaging

Like mentioned before coronary angiography is the gold standard for diagnosing atherosclerosis [15]. Coronary Angiography is very successful in measuring a stenosis of the lumen of an artery. When the lumen diameter of an artery starts to decrease, the plaque formation growth is completed up to 40 % which means that it is impossible to detect atherosclerosis in early stages [16]. This fact was one of the reasons why functional imaging in the field of Atherosclerotic diagnosis got important. PET or SPECT devices are able to make a quantification of the biological process of plaque development, provide information about the plaque composition and track the disease progression from the starting point. Biological targets such like the adhesion molecule VCAM-1, which is one of the first molecules expressed by the endothelial cells, signalizes the beginning of the plaque formation process [16].

The probes which are labeled with radionuclides should have key characteristics like high affinity to targeted molecule, ability to overcome biological barriers, low toxicity, efficient clearance in vivo and straightforward production [17].

For a better registration of the molecular or cellular information to anatomical detail it can be combined with imaging modalities like MRI or CT. Disadvantages are that also this tool needs an invasive procedure, associated with high cost and radiation exposure. It is still in the preclinical research status.

F. Near infrared spectroscopy

Near infrared spectroscopy (NIRS) is based on the fact that every material has a characteristic pattern of absorbance of near-infrared light which can be used as a unique fingerprint to identify different types of

substances [6]. This can also be used for detecting atherosclerotic plaque [6]. In clinical practice it is used in combination with the IVUS imaging system. Fig. 5 shows on the left the image of an hybrid catheter system of IVUS and NIRS. On the right side of the image the chemogram of NIRS is illustrated where yellow represents locations of high probability of lipid presence

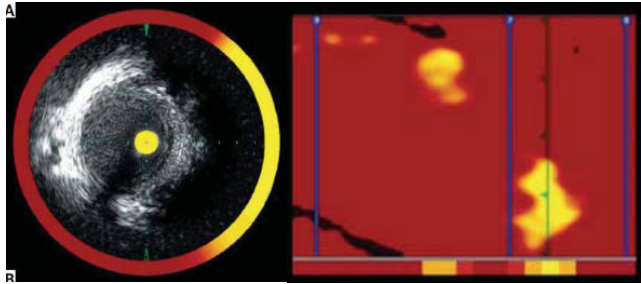


Fig. 5: IVUS image combined with Near infrared spectroscopy (NIRS) information (left) chemogram of NIRS (right) [6]

and red low probability locations of lipid presence. The chemogram can be imagined as the artery wall which had been split open along its longitudinal axis. In this manner the x-axis is the pullback position in millimeter and the y-axis the circumferential position in degrees. The combined image of IVUS and NIRS helps the surgeon in interpreting the vulnerable plaque regions in the IVUS image [6].

G. Intravascular thermography

Another new Approach which is still in preclinical state is intravascular thermography. This approach is based on the assumption that the temperature at arterial walls with atherosclerotic lesions are heterogenic distributed compared to healthy vessel walls. Certain regions with increased temperature could be a sign for inflammation which are known as one of the major signs for atherosclerosis. Also the macrophages which are very active cells and play a major role in building up the cholesterol layers of plaque are leading an increase in heat. But there are other factors like the circulating blood which are influencing and fluctuating the temperature of the arterial walls [7].

Recent research is testing this technique by introducing a thermography catheter which gave helpful results but it is still waiting for the FDA approval to test it on human subjects to determine if it is beneficial, safe and reproducible in real clinical circumstances [7].

H. Optical Coherence Tomography

The optical coherence tomography (OCT) is similar to

the IVUS technology with the exception, that light is used instead of ultrasound at the distal tip of the catheter. The light waves are hitting against the arterial walls of the region of interest and the backscattered light is measured. The Signal is created by the echo time delay. With an axial resolution of 10-15 μm and a lateral resolution of 20-90 μm this method is the one with the highest resolution. The reason for that is the use of light which has much shorter wavelengths (1280-1350 nm) than ultrasound. This advantage is at the same time a limitations of the penetration depth (1-3 mm) [18].

During the procedure, the catheter is inserted to the region of interest and the red blood cells has to be flushed out because of their high attenuation characteristic of light waves. That interruption of blood flow is one of the main disadvantages of this method because of the risk of coronary damage or myocardial ischemia [18].

Due to the high resolution of this intravascular imaging technique also plaque characterization can be done, especially the thickness of the fibrous cap can be measured precisely. This is one of the major signs to assess the rupture risk of the arterial wall. Fig. 6 shows two different types of plaque composition illustrated by optical coherence tomography. The artery which is shown in A has a decreased intimal lumen due to fibrotic stable plaque, which is easy to differentiate from the artery shown in B where the darker region beyond the artery wall is calcification.

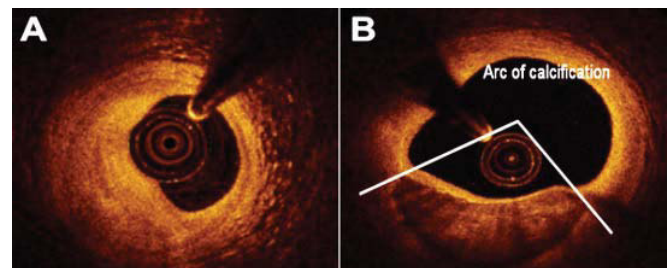


Fig. 6: Optical coherence tomography image of atherosclerotic arteries ; fibrotic stable plaque (A) calcification (B) [18]

This technique is already used in clinical practice primarily for measuring the thickness of the fibrous cap. It is also used for characterization of the healing process after an intervention [18].

I. Intravascular palpography

All above mentioned methods are focused on detecting one pathological aspect like for example measuring the thickness of the fibrous cap. Vulnerable plaque is tried to be differentiate from non-vulnerable plaque by characterization of the plaque composition. But these methods are not considering the force which is finally causing the rupture. The mentioned force is the

pulsating force evoked by the blood pressure [19]. If the plaque is not able to withstand this stress, then it ruptures. Therefore, measuring the strength of the fibrous cap could be more decisive than measuring the thickness of it [19]. Intravascular palpography is created exactly from these thoughts. It uses the difference in mechanical properties of different plaque layers to measure the rupture risk. Intraluminal pressure is applied to test the local strain of analyzed tissue. Intravascular palpography is based on IVUS imaging and is available in a combined system. Fig. 7 illustrates the imaging result of a combined system with IVUS imaging. On the right, the palpography map is shown the percentage of strain measured on the arterial wall. The percentage of strain is concentrated to weaker points, with higher rupture risk which can be identified in this image by the yellow regions [19].

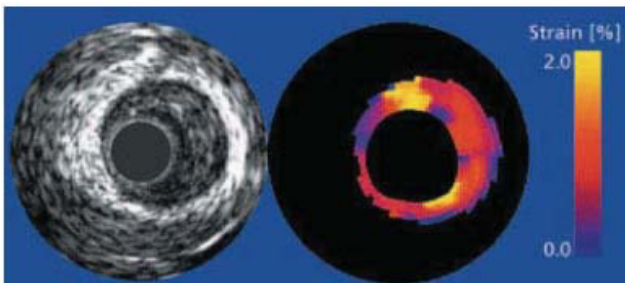


Fig. 7: IVUS image (left) and Intravascular palpography map (right) [19]

It can also be used to identify high stress regions with the support of real time morphological imaging of IVUS. A limitation of this method is the illustration of the strain only of the first 450 μm beyond the arterial wall on an image [20].

J. Coronary computed tomography (CCT) for measuring atherosclerotic plaque strain

For many years coronary computed tomography was used isolated for detecting the severity of atherosclerotic stenosis. Recent studies are showing that an isolated use of angiography for assessment of stenosis is not enough. Currently it is discussed if angiography is needed as additional information to newer approaches to complete the diagnostic assessment [21]. To test if additional using of CCT is beneficial, the coronary flow reserve (CFR) was determined alone and with the additional use of the CCT. The main benefit of the CCT is the additional information whether the plaque is calcified or not. The CFR is a validated measure of severity of detected stenosis. It expresses the ratio of myocardial blood flow during vasodilator stress over that at rest. The result was that the assessment of severity of stenosis can

be done better with additional information of CCT than the stenosis severity test alone [22].

IV. FIRST-LINE THERAPY OF ATHEROSCLEROSIS

A. Lifestyle modification and pharmacological treatment

If vulnerable plaque due to Atherosclerosis is diagnosed, the subsequent task is to realize plaque stabilization. This has to be done by different medical approaches. When the severity is not high, the first line treatment is to control and minimize the risk factors like hypertension, hypercholesterolemia, cigarette smoking and the use of aspirin [23]. Nutrition plays also a significant role at earlier stages of atherosclerosis. Studies has proven that the Mediterranean diet reduces the risk of myocardial infarction up to 50 % [24].

Parallel to lifestyle modification also medications like anti-inflammatory agents, angiotensin-converting enzymes (ACE) inhibitors, lipid lowering medications and many others are used in Atherosclerosis treatment.

V. INTERVENTIONAL REVASCULARIZATION PROCEDURES

If the severity of detected vulnerable plaque is that high, that pharmacological treatment and lifestyle modification are not sufficient, interventional local revascularization procedures are used for treatment. In the following part the most common procedures are described for the example of coronary artery atherosclerosis.

A. Percutaneous coronary intervention (PCI)

PCI is the standard therapy procedure for revascularization of an artery with atherosclerotic lesions. The intervention starts with an incision at the groin area to have access to the femoral artery. From this entry point a catheter is introduced through the artery up to the coronary region. To guide the catheter, usually radio angiography is used. After reaching the coronary arteries radiopaque dye is injected into the arteries to detect a stenosis and calculate the diameter of the artery lumen. As a next step a guidewire is negotiated through the catheter to the right position and the catheter is removed. A balloon catheter is pushed over the guidewire again to the correct location. The balloon catheter is inflated multiple times to enlarge the constricted vessel. To prevent restenosis after deflating and removing the balloon, another balloon catheter with surrounded metal mesh (stent) is inserted to the same location. The second balloon catheter is again inflated

and widening the stent to the arterial walls. After the stent has reached a proper diameter, the balloon catheter is removed and the stent remains in the vessel [25]. The main disadvantage of this procedure is the risk of in-stent restenosis and late stent thrombosis [26].

B. Coronary artery bypass grafting (CABG)

When medication and healthier lifestyle is not reducing the symptoms and PCI is not able to treat the blockages or the probability of getting restenosis after PCI is high, then CABG is the procedure of choice [27]. In this surgery the surgeon creates a new path around the blocked artery to the heart. For the new path a healthy vein or artery from the body is used. CABG has very promising outcomes, and no risk of restenosis. Nevertheless, it is performed as an open heart surgery or minimal invasive procedure which is in both cases much more invasive than PCI [28].

VI. INTERVENTIONAL TOOLS FOR TREATMENT

A. Balloon catheters

Balloon catheters are used in revascularization procedures like PCI to enlarge the lumen diameter of stenotic vessels. They are navigated to the artery by a steerable guide wire in a deflated condition. Important improvements of these catheters in the past years were the increased bending capability, the increased shaft stiffness and the reduction of the diameter of the deflated balloon. Drawbacks of these catheters are that they are overstretching artery walls and especially the separate use has the disadvantage of early or late restenosis after intervention [29]. For this reason, balloon catheters are most often used in combination with other interventional therapy equipment like coronary stents or Atherectomy devices.

A recent developed balloon catheter which was CE marked in 2015 is the lithoplasty balloon catheter. Fig. 8 shows the small electrodes on its surface inside the balloon which can vibrate in a certain frequency to deliver ultrasound shockwaves to break up calcified plaques.

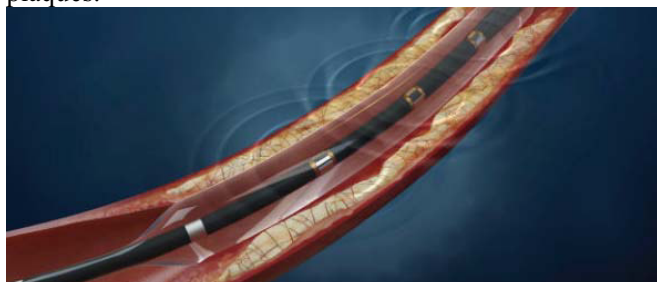

Fig. 8: Lithoplasty balloon catheter [30]

After delivering the shockwaves the plaque is reputed to be more flexible and the balloon is inflated without damaging the vessel wall. The six-months results of a recent study [31] show that there were no thrombus, perforations or distal embolization events. To define other rates like the target lesion revascularization the study is still ongoing.

B. Atherectomy devices

The purpose of Atherectomy devices was intravascular drilling, crushing or sanding of atheroma. An advancement of this are rotational Atherectomy devices which are made for plaque abrasion and pulverization rather than cutting the plaque tissue. This kind of devices are used for cases where balloon catheters are not able to dilate the vessel due to heavy calcification. A study showed that short term success of rotational atherectomy was higher than for balloon angioplasty but associated with higher risk of the need of revascularization procedure 6 months after the treatment [32]. It is also associated with a higher risk of periprocedural myocardial infarction [33]. The drawbacks of these devices lead to newer developments of different technologies. More recent orbital atherectomy devices are used for treatment of very severely calcified lesions before stent implantation. They have a diamond coated crown that rotates with 60,000 to 200,000 rpm which can be seen in Fig. 9.




Fig. 9: Orbital atherectomy catheter with diamond coated eccentric shaped crown [34]

Due to its eccentric shape the crown is rotating in an elliptical orbit. This kind of rotation is reputed to be preventive against damages to healthy cells of the vessel wall. A very recent study shows a two-year data where 443 patients were analyzed to cardiac death, myocardial infarction and target vessel revascularization [35]. These rates were significantly lower than with earlier therapy strategies [35].

C. Stents

To prevent the above mentioned problem a lot of different types of stents were developed in the past years. There are Drug-eluting stents (DES), bare metal

stents (BMS), biodegradable-polymer stents (BDPS), durable polymer stents (DPS) and alternatives to stents available. Bare metal stents are the first used standard version of stents and have only the function to hold the vessel mechanically open. It is often made by cobalt-chromium or stainless steel [36]. The problem with this stents is as already mentioned above that in-stent restenosis occurs and it is needed to repeat the PCI procedure [26]. To avoid this problem DES were developed, which have reduced the need for repeat revascularization [37]. This type of stents is preventing the rebuilt of plaque around the stent material by eluting antiproliferative drugs like the anti-inflammatory agent sirolimus, and the antimetabolic agent paclitaxel [38]. Disadvantageous is that the patient has to do dual antiplatelet therapy for at least 6-12 months where he has to take additional medications [37]. Compared to Bare-Metal Stents the risk for late stent thrombosis is increased with drug-eluting stents [26]. Fig. 10 illustrates the difference in the effect of restenosis caused by BMS and the late stent thrombosis caused by DES on the vessel lumen.

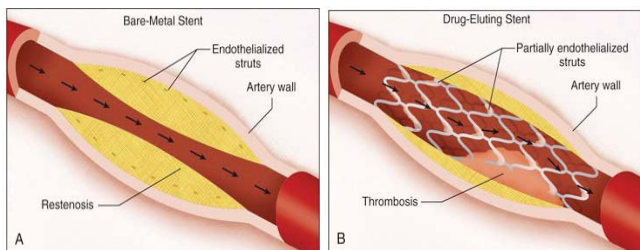


Fig. 10: Comparison of complications with a bare-Metal stent (A) and a Drug-eluting stent (B) [39]

As discussed above there is no current optimal solution of stenting a vessel [26]. Because of this reason newer tools like drug eluting balloons are discussed in recent studies which don't have the drawbacks of implementing a metal scaffold [26]. The advantage of this method is that no implant has to remain in the vessel which can cause inflammation or tissue ingrowth [26]. The drug-eluting balloon is threaded to the location of the stenosis and is inflated once to deliver the drug rapidly to the arterial wall and is completely removed after the procedure. Only the eluted drugs remain in the arterial wall. If the patient has multiple blockages in coronary arteries, the physician will usually think about a multiple arterial bypass grafting surgery, which is a much more complicated intervention [40].

D. Thrombectomy devices

Thrombectomy devices are used for aspiration of thrombus during PCI for reducing the mortality, reinfarction risk or stent thrombosis after the intervention. Current clinical trials were not able to prove these positive outcomes [41]. A randomized trial with 10,732 patients found out that there is no difference between the group which got atherothrombotic aspiration and the control group in cardiovascular death, recurrent myocardial infarction and cardiogenic shock [41].

VII. FUTURE APPROACHES FOR TREATMENT

A. Photodynamic therapy (PDT)

An alternative treatment method for Atherosclerosis is Photodynamic therapy. It can destroy inflammatory cells, stabilize plaque layers, and heal the vessel walls [42]. The basic principle of PDT is built on three steps. First a drug is injected which is selective for the target tissue and sensitive to a certain wavelength of light. A light source is concentrated exposed to the target tissue. The absorbed drug by the target tissue will be selectively destroyed (cell apoptosis) by the activated drug and is not damaging the arterial wall [42]. The activating light is delivered to treatment site by a perfusion balloon catheter based illumination system. The perfusion balloon catheter doesn't stop the blood flow compared to other balloon catheters. Fig. 11 shows an example for a perfusion balloon catheter with a double balloon structure. The two outer balloons are avoiding that blood gets to the middle part of the catheter where the drug delivery to the atherosclerotic lesion takes place.

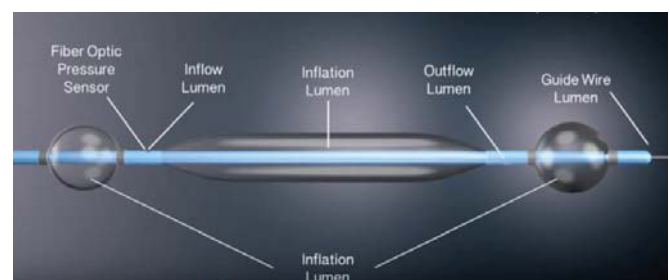


Fig. 11: Perfusion balloon catheter [43]

Nevertheless, the blood is continuously flowing through a separate channel and there is a possibility to deliver drug agents to the atherosclerotic plaque through an additional channel. As a next step a light wire is inserted through the catheter to illuminate the regions of interest and cause cell apoptosis in the target tissue without damaging other regions. With this technique it is possible to treat multiple segments of the vessel within one procedure

However, this technique is not yet used in clinical practice. Some of the reasons might be the need of multiple PDT components, insufficient clinical data and financial restraints because of high cost of an PDT laboratory set up.

B. Thermal treatment of atherosclerosis

The theory of thermal treatment of atherosclerosis is based on macrophage apoptosis by applying heat. Investigations found that heating the plaque up to 42 °C for 15 minutes increased the apoptosis rate of Macrophages. This could be used as an additional treatment to prevent inflammation in coronary arteries. The limitation for this kind of approach is that heat apply can also destroy surrounding tissue. To translate this approach into clinical use under consideration of above mentioned limitation, a first design of a radiofrequency (RF) device in the shape of a RF angioplasty balloon was performed in 2015. This balloon has micro electrodes on its surface and is supported with cooling agents which should prevent damage to healthy structures inside the vessel lumen. The heat is applied for ablating the plaque and vascular smooth muscle tissue which play a major role in the composition of the plaque [44].

VIII. DISCUSSION

Due to the high priority of cardiovascular diseases a huge number of diagnostic and several therapy methods are developed. These diagnostic opportunities lead to a new challenge to choose the correct and individual therapy for each patient. Every physician seems to have his own favorite tool and undertake the associated benefits and drawbacks. There are a lot of approaches but there is more need to combine the benefits of different techniques into one device. When such a device is developed, the subsequent challenge is to produce such a device in a low cost range, which is important by considering the fact that 80-90 % of all atherothrombotic cardiovascular diseases in 2025 will be in the developing world.

As mentioned in the beginning the main focus should be on providing earlier detection to save the patients from death and dissociate from older generally accepted devices like the sole use of coronary angiography to detect atherosclerosis. It is very difficult to identify vulnerable Plaque in early stages of Atherosclerosis with conventional anatomical imaging techniques [45]. That could be one of the reasons why the disease is able to progress silently over many years until symptoms are developed and go into clinical treatment. From this point of view, a risk assessment before developing any symptoms should be the major goal. Molecular Imaging could be the right approach by considering that the

origin of atherosclerosis is of molecular nature and not anatomic. The stenosis is only the consequence of atherosclerosis and not the origin [3] [46]. Compared to the anatomical Imaging in theory the molecular Imaging is also able to detect early formation of atherosclerotic plaque by one of the main initiators, the Inflammation process. The additional information like plaque composition, which can be acquired from these approaches, are significant for decision of each individual case between PCI, CABG or pharmacological therapy. There is still a lot of work to do until this goes into clinical practice, but this kind of techniques could be the future of early diagnosis of atherosclerosis.

IX. CONCLUSION AND FUTURE OUTLOOK

A lot of new diagnostic approaches with high promising technologies for early detection of Atherosclerosis are on the market or in the developing phase. IVUS imaging offers real time imaging with good morphological information. Advancements like targeted contrast agents allow functional imaging to characterize plaque composition with IVUS imaging. Non-invasive external MRI offers the best differentiation between different soft tissue layers, with high similarity to the histological model, which makes it easier to interpret. Radionuclide imaging is high promising due to its molecular imaging capability. Optical coherence tomography is very precise in detecting morphological detail like the fibrous cap thickness. Intravascular palpography measures the strain by analyzing the mechanical properties which is a different aspect in this diagnostic field. Coronary computed tomography is beneficial as an additional technique to other risk assessment methods by quantifying the calcification of the plaque.

The gold standard to treat stenotic vessels is to perform a PCI by using inflatable balloon catheters to widen the vessel lumen and implementing a stent which remains in the vessel to keep the enlarged lumen. Recent improvements of atherectomy devices which are rotating in a shape of an elliptical orbit are reducing the target lesion revascularization significantly. Thrombectomy devices for thrombus aspiration are getting out of use. Newer studies can't prove the benefits of it. A lot of improvements in the field of stents were done by using different materials (e.g. biodegradable stents) or by developing drug-eluting stents which are minimizing the in-stent restenosis risk.

When the benefits of the newer methods get clinically proven and a successful translation will occur, there is high promise that in the near future a much more optimal diagnosis for atherosclerosis will exist.

In the therapeutic field there is no interventional idea for optimal solution that offers a long term without restenosis risk. An exception is the invasive CABG surgery. The drug-eluting stents have a good short term effect and reduce the in-stent restenosis but increase the risk of late stent thrombosis. Due to its selectivity Photo dynamic therapy could be the future technology as supporting treatment for preventing restenosis. The clinical perspective of this technology gives high promise because of the opportunity to treat multiple segments of the vessel in one intervention and could be used in combination with standard PCI to prevent restenosis which is still not solved by other techniques. Another advantage is that the selectivity can be combined with functional diagnostic methods like radionuclide imaging.

Finally, it can be said that both fields offer a lot of space for improvements, especially in the translation of above mentioned approaches into clinical practice.

REFERENCES

- [1] M. Naghavi, „Preventive Cardiology: The SHAPE of the Future,“ in *Asymptomatic Atherosclerosis*, Houston, Texas, Humana Press, 2010, pp. 1-12.
- [2] Y. Salim, R. Srinath, Ô. Stephanie und A. Sonia, „Global burden of cardiovascular diseases, I: general considerations, the epidemiologic transition, risk factors,“ *Circulation*, pp. 2746-2753, 27 November 2001.
- [3] A. Haber, „Atherosclerosis,“ in *Metalloproteases for Attenuation of Atherosclerosis*, Berlin Heidelberg, Springer-Verlag, 2012, pp. 17-27.
- [4] G. Howard-Alpe, J. Sear und P. Foex, „Methods of detecting atherosclerosis in non-cardiac surgical patients; the role of biochemical markers,“ *British Journal of Anaesthesia*, pp. 758-769, October 2006.
- [5] J. Tarkin, M. Dweck, N. Evans, R. Takx, A. Brown und e. al, „Imaging Atherosclerosis,“ *Circulation Research*, pp. 750-769, 2016.
- [6] M. Horvath, P. Hajek, C. Stechovsky, J. Honek und e. al., „The role of near-infrared spectroscopy in the detection of vulnerable atherosclerotic plaques,“ *Arch Med Sci*, Bd. 12, Nr. 6, p. 1308–1316, 2014.
- [7] V. Mani, A. Chowdhury, V. Johan und A. Petrov, „Ultrasonic detection of coronary disease,“ in *The Vulnerable Atherosclerotic Plaque : Strategies for Diagnosis and Management*, Singapore, Blackwell Publishing, 2007, pp. 211-221.
- [8] F. Villanueva, „Molecular Imaging of Cardiovascular Disease Using Ultrasound,“ *J Nucl Cardiol*, pp. 576-586, November 2008.
- [9] A. Nair, B. Kuban, E. Tuzcu, P. Schoenhagen, S. Nissan und e. al, „Coronary plaque classification using intravascular ultrasound radiofrequency data analysis,“ *Circulation*, pp. 2200-2206, 2002.
- [10] S. Bridal, P. Fornes, P. Brunevar und G. Berger, „Parametric (integrated backscatter and attenuation) images constructed using backscattered radio frequency signals (25–56 MHz) from human aortae in-vitro,“ *Ultrasound Med Biol*, pp. 215-229, 1997.
- [11] V. Fuster, R. Corti, Z. Fayad, J. Schwitter und J. Badimon, „Integration of vascular biology and magnetic resonance imaging in the understanding of atherothrombosis and acute coronary syndromes,“ *J Thromb Haemost*, pp. 1410-1421, 2003.
- [12] H. Song, R. Wolf, J. Schneiderman und R. Wilensky, „Magnetic resonance imaging and intravascular magnetic resonance imaging,“ in *The Vulnerable Atherosclerotic Plaque : Strategies for Diagnosis and Management*, Singapore, Blackwell publishing, 2007, pp. 230-246.
- [13] H. Yasuhiro und F. Peter, „Frontiers in Intravascular Imaging Technologies,“ *Circulation*, Nr. 117, pp. 2024-2037, 2008.
- [14] J. Toussaint, J. Southern und V. Fuster, „Water diffusion properties of human atherosclerosis and thrombosis measured by pulse field gradient nuclear magnetic resonance,“ *Arterioscler Thromb Vasc Biol*, Nr. 17, pp. 542-556, 1997.
- [15] H. Langer, R. Haubner, B. Juergen und M. Gawaz, „Radionuclide imaging - A molecular key to the atherosclerotic plaque,“ *J Am Coll Cardiol*, pp. 1-12, 1 July 2008.
- [16] S. Kazuma, D. Sultan, Y. Zhao, L. Detering, M. You und e. al., „Recent Advances of Radionuclide-based Molecular Imaging of Atherosclerosis,“ *Curr Pharm Des*, pp. 5267-5276, 2015.
- [17] Y. Liu und M. Welch, „Molecular imaging of small animals : instrumentation and applications,“ in *Advances in Radiotracer Development for Molecular Imaging*, New York, Spring, 2014, pp. 275-318.
- [18] N. Shah, P. Howlett, D. Fluck, M. Williams, A. Jacques und M. Mahmoudi, „Optical Coherence Tomography in Coronary Atherosclerosis,“ *MOJ Anatomy & Physiology*, 23 July 2015.
- [19] V. Mani, A. Chowdhury, V. Johan und A. Petrov, „Intravascular palpography,“ in *The Vulnerable Atherosclerotic Plaque : Strategies for Diagnosis and Management*, Singapore, Blackwell Publishing

- , 2007, pp. 289-296.
- [20] V. Soest, „Intravascular Photoacoustic Imaging Of Vulnerable Atherosclerotic Plaque,“ *ICR*, pp. 120-123, 08 September 2016.
- [21] M. Di Carli und R. Blankstein, „Quantifying Plaque Burden and Morphology Using Coronary Computed Tomography Angiography to Predict Coronary Physiology Helpful...But Is It Sufficient?,“ *Circulation: Cardiovascular Imaging*, pp. 1-4, 14 October 2015.
- [22] D. Dey, Z. Diaz, A. Schuhbaeck, L. JuarezOrozco, Y. Otaki und e. al, „Relationship between quantitative adverse plaque features from coronary computed tomography angiography and downstream impaired myocardial flow reserve by 13N-ammonia positron emission tomography: a pilot study,“ *Circ Cardiovasc Imaging*, 2015.
- [23] V. Mani, A. Chowdhury, V. Johan und A. Petrov, „New developments in treatment of vulnerable plaques,“ in *The Vulnerable Atherosclerotic Plaque: Strategies for Diagnosis and Management*, Singapore, Blackwell Publishing, 2007, pp. 305-320.
- [24] R. Singh, G. Dubnov, M. Niaz und e. al, „Effect of an Indo-Mediterranean diet on progression of coronary artery disease in high risk patients (Indo-Mediterranean Diet Heart Study): a randomised single-blind trial,“ *Lancet*, Nr. 360, pp. 1455-1461, 202.
- [25] K. Campbell, *Percutaneous Coronary Intervention-Coronary Angioplasty*, Florida: Florida State University College of Medicine, 2011.
- [26] A. Indermuehle, R. Bahl, A. Lansky, G. Froehlich und e. al, „Drug-eluting balloon angioplasty for in-stent restenosis: a systematic review and meta-analysis of randomised controlled trials,“ *heartjnl*, 18 January 2013.
- [27] R. Habib, D. B. MD, M. Yammine, A. El-Hage-Sleiman und e. al, „CABG Versus PCI Greater Benefit in Long-Term Outcomes With Multiple Arterial Bypass Grafting,“ *JOURNAL OF THE AMERICAN COLLEGE OF CARDIOLOGY*, pp. 1417-1427, 29 September 2015.
- [28] National Heart, Lung and Blood Institute, „National Heart, Lung, and Blood Institute,“ 23 February 2012. [Online]. Available: <https://www.nhlbi.nih.gov/health/health-topics/topics/cabg>. [Zugriff am 15 December 2016].
- [29] W. Kok, R. P. G. Peters und C. Di Mario, „Greater late lumen loss after successful coronary balloon angioplasty in the proximal left anterior descending coronary artery is not explained by extent of vessel wall damage or plaque burden,“ *Journal of the American College of Cardiology*, pp. 382-388, February 2000.
- [30] medGadget, „medGadget,“ 09 January 2015. [Online]. Available: <http://www.medgadget.com/2015/01/shockwave-pad-balloon-catheters-with-lithotripsy-technology-ce-marked-video.html>. [Zugriff am 19 December 2016].
- [31] T. Brinton, M. Brodmann, M. Werner, G. Tepe, A. Holden und e. al, „TCT-777 Safety and Performance of the Shockwave Medical Lithoplasty® System in treating calcified peripheral vascular lesions: 6-Month Results from the two-phase DISRUPT PAD Study,“ *Journal of the American College of Cardiology*, p. 314, 1 November 2016.
- [32] N. Reifart, M. Vandormael, M. Krajcar und S. Göhring, „Randomized comparison of angioplasty of complex coronary lesions at a single center. Excimer Laser, Rotational Atherectomy, and Balloon Angioplasty Comparison (ERBAC) Study,“ *Circulation*, pp. 91-98, 1 July 1997.
- [33] D. Baim, D. Wahr, B. George, M. B. Leon, J. Greenberg und e. al, „Randomized Trial of a Distal Embolic Protection Device During Percutaneous Intervention of Saphenous Vein Aorto-Coronary Bypass Grafts,“ *Circulation*, pp. 1285-1290, 25 February 2002.
- [34] Diagnostic and Interventional Cardiology, „New Technologies to Treat Peripheral Artery Disease (PAD),“ 2016 February 2016. [Online]. Available: <http://www.dicardiology.com/article/new-technologies-treat-peripheral-artery-disease-pad>. [Zugriff am 18 December 2016].
- [35] P. Généreux, N. Bettinger, B. Redfors, A. Lee, C. Kim und e. al, „Two-year outcomes after treatment of severely calcified coronary lesions with the orbital atherectomy system and the impact of stent types: Insight from the ORBIT II trial,“ pp. 369-377, 16 April 2016.
- [36] A. Koh, L. Choi, L. Sim, J. Tan und e. al, „Comparing the use of cobalt chromium stents to stainless steel stents in primary percutaneous coronary intervention for acute myocardial infarction: A prospective registry,“ *Acute Cardiac Care*, pp. 219-222, 05 December 2011.
- [37] S. Hyuck Kang, K. Park, D. Kang und W. Lim, „Biodegradable-polymer drug-eluting stents vs. bare metal stents vs. durable-polymer drug-eluting stents: a systematic review and Bayesian approach network meta-analysis,“ *European Heart Journal*,

23 January 2014.

- [38] M. Madjid, S. Litovsky, J. Willerson und S. Casscells, „New developments in treatment of vulnerable plaques,“ in *The Vulnerable Atherosclerotic Plaque : Strategies for Diagnosis and Management*, Singapore, Blackwell Publishing , 2007, pp. 305-320.
- [39] Radiologykey, [Online]. Available: http://radiologykey.com/wp-content/uploads/2015/12/B978141605335400037X_f4.jpg. [Zugriff am 18 December 2016].
- [40] A. Michaels und K. Chatterjee, „Angioplasty versus bypass surgery for coronary artery disease,“ *Circulation*, pp. 187-190, 202.
- [41] S. Jolly, J. Cairns, S. Yusuf, P. Meeks, J. Pogue und e. al, „Randomized Trial of Primary PCI with or without Routine Manual Thrombectomy,“ *N Engl J Med* , pp. 1389-1398, 9 April 2015.
- [42] R. Waksman und P. McEwan, „Photodynamic therapy,“ in *The Vulnerable Atherosclerotic Plaque : Strategies for Diagnosis and Management*, Singapore, Blackwell Publishing , 2007, pp. 321-330.
- [43] L. Hood. [Online]. Available: <https://www.youtube.com/watch?v=G8vCaeLfsHA> . [Zugriff am 19 December 2016].
- [44] C. Jiang, K. Zhang, S. Zhao, J. Zou und e. al, „An RF device for effective thermal treatment of atherosclerosis,“ in *Conf Proc IEEE Eng Med Biol Soc*, Milan, 2015.
- [45] S. David und B. Kaufmann, „Ultrasound Imaging for Risk Assessment in Atherosclerosis,“ *Int. J. Mol. Sci*, pp. 9749-9769, 6 February 2015.
- [46] A. Shor, „The deadly disease,“ in *Chlamydia Atherosclerosis Lesion Discovery, Diagnosis, and Treatment*, Johannesburg, Springer, 2007, pp. 6-16.

ISBN: 978-3-944722-55-9