
















CONTEMPORARY REVIEW

Safety and Outcomes of Mechanical Thrombectomy in Acute Ischemic Stroke Attributable to Cardiological Diseases: A Scoping Review

Lucio D'Anna , MD, PhD; Samir Abu-Rumeileh , MD; Giovanni Merlino, MD, PhD; Raffaele Ornello , MD; Matteo Foschi , MD; Francesco Diana , MD; Lorenzo Barba , MD; Vincenzo Mastrangelo, MD; Michele Romoli , MD, PhD; Kyriakos Lobotesis , MD; Francesco Bax , MD; Fedra Kuris , MD; Mariarosaria Valente, MD; Markus Otto , MD; Eleni Korompoki , MD, PhD; Simona Sacco , MD; Gian Luigi Gigli, MD; Thanh N. Nguyen , MD; Soma Banerjee , MD

ABSTRACT: There is limited evidence on the outcomes and safety of mechanical thrombectomy (MT) among patients with acute ischemic stroke (AIS) in the context of cardiac diseases. Our study reviews MT in AIS within the context of cardiac diseases, aiming to identify existing and emerging needs and gaps. PubMed and Scopus were searched until December 31, 2023, using a combination of cardiological diseases and “mechanical thrombectomy” or “endovascular treatment” as keywords. Study design included case reports/series, observational studies, randomized clinical trials, and meta-analyses/systematic reviews. We identified 943 articles, of which 130 were included in the review. Results were categorized according to the cardiac conditions. MT shows significant benefits in patients with atrial fibrillation (n=139) but lacks data for stroke occurring after percutaneous coronary intervention (n=2) or transcatheter aortic valve implantation (n=5). MT is beneficial in AIS attributable to infective endocarditis (n=34), although functional benefit may be limited. Controversy surrounds the functional outcomes and mortality of patients with AIS with heart failure undergoing MT (n=11). Despite technical challenges, MT appears feasible in aortic dissection cases (n=4), and in patients with left ventricular assist device or total artificial heart (n=10). Data on AIS attributable to congenital heart disease (n=4) primarily focus on pediatric cases requiring technical modifications. Treatment outcomes of MT in patients with cardiac tumors (n=8) vary because of clot consistency differences. After cardiac surgery stroke, MT may improve outcomes with early intervention (n=13). Available data outline the feasibility of MT in patients with AIS attributable to large-vessel occlusion in the context of cardiac diseases.

Key Words: atrial fibrillation ■ cardiological diseases ■ heart failure ■ ischemic stroke ■ mechanical thrombectomy ■ percutaneous coronary intervention

Stroke is a major cause of mortality and a leading cause of physical disability, hospitalization, dementia, and depression.¹ Ischemic stroke has multiple risk factors and various causative subtypes (eg, atherosclerotic, cardioembolic, small-vessel disease, rare causes, and unknown causes).² Several

randomized controlled trials demonstrated that mechanical thrombectomy (MT) is effective and safe in acute ischemic stroke (AIS) attributable to large-vessel occlusion (LVO) of the anterior and posterior circulation, irrespective of the cause.³ However, to date, limited evidence is available on the efficacy and safety of

Correspondence to: Lucio D'Anna, MD, PhD, Department of Brain Sciences, Imperial College London, Du Cane Road, London w120nn, United Kingdom. Email: l.danna@imperial.ac.uk

This manuscript was sent to Neel S. Singhal, MD, PhD, Associate Editor, for review by expert referees, editorial decision, and final disposition.

Supplemental Material is available at <https://www.ahajournals.org/doi/suppl/10.1161/JAHA.124.034783>

For Sources of Funding and Disclosures, see page 18.

© 2024 The Authors. Published on behalf of the American Heart Association, Inc., by Wiley. This is an open access article under the terms of the [Creative Commons Attribution-NonCommercial-NoDerivs](https://creativecommons.org/licenses/by-nc-nd/4.0/) License, which permits use and distribution in any medium, provided the original work is properly cited, the use is non-commercial and no modifications or adaptations are made.

JAHA is available at: www.ahajournals.org/journal/jaha

Nonstandard Abbreviations and Acronyms

AIS	acute ischemic stroke
AoD	acute aortic dissection
CAT	cardiac tumor
GA	general anesthesia
IE	infective endocarditis
IVT	intravenous thrombolysis
LVO	large-vessel occlusion
mRS	modified Rankin Scale
MT	mechanical thrombectomy
TAVI	transcatheter aortic valve implantation
TCM	Takotsubo cardiomyopathy

MT among patients with AIS specifically in the context of cardiac diseases. This distinction may be important in the context of LVO stroke because the brain and the heart are intricately linked in the context of stroke, with the heart being both cause and target of stroke pathophysiology and complications. Moreover, most of these patients treated with MT in real-life practice would probably not have qualified for inclusion in the clinical trials, but probably do benefit from the endovascular treatment. Indeed, the question of generalized applicability of these findings to a more heterogeneous population has been a topic of debate. In this review, we aim to summarize the evidence on the efficacy and safety of MT in AIS attributable to cardiological diseases. We discuss their frequency, management, and treatment outcomes to identify current and emerging unmet needs and evidence gaps.

METHODS

We conducted a scoping review following the Preferred Reporting Items for Systematic Reviews and Meta-Analyses guidelines adapted to scoping reviews and a predetermined protocol shared among all authors⁴ (Figure 1).

Eligibility Criteria

We selected studies assessing safety and outcomes of MT in cardiological conditions. Study design included case reports/series, observational studies, randomized clinical trials, and meta-analyses/systematic reviews, because we aimed for a broad catchment of the topic. No age, sex, or geographical restriction was applied. Only published articles were included.

Information Sources

Four reviewers (L.D., S.A.R., M.F., and M.R.) searched articles through publicly available literature databases

(PubMed, Scopus) from inception until December 31, 2023. The search strategy was based on the combination of cardiological diseases and “mechanical thrombectomy” or “endovascular treatment” as keywords (complete search string is provided in Data S1). Reference lists and citing articles were also reviewed to increase the identification of relevant studies. Nonoriginal records, studies without available full text, and articles in languages other than English were excluded.

Study Selection and Data Extraction

Study selection was conducted on the Rayyan online platform (rayyan.ai). Reference lists were screened for titles and abstracts independently by a team of 2 reviewers for each database (ie, L.D. and S.A.R. for Pubmed, M.F. and M.R. for Scopus). Subsequently, potentially relevant articles were acquired in full text and assessed for eligibility. The final selection was shared among all the 4 coauthors, and eventual disagreements were resolved by consensus.

Data Items

We abstracted data on article characteristics (study design), number of participants, age of the patients, number of patients treated with MT, number of patients with good functional outcome at 90 days, rate of mortality at 90 days, rate of symptomatic hemorrhagic transformation, and rate of successful recanalization.

RESULTS

We identified 943 articles, of which 130 were included in the review. We categorized a review of the results according to the cardiac conditions as follows: atrial fibrillation and other arrhythmias (n=39), percutaneous coronary intervention (n=2), transcatheter aortic valve implantation (n=5), infective endocarditis (n=34), heart failure (n=11), aortic dissection (n=4), left ventricular assist device and total artificial heart (n=10), congenital heart disease (n=4), cardiac tumors (n=8), and cardiac surgery (n=13) (Figure 1).

Atrial Fibrillation and Other Arrhythmias

Atrial fibrillation (AF) is a major cause of AIS, accounting for ≈20% to 30% of all cases.^{5,6} AF can be newly detected in close temporal proximity to the index stroke or can be known before the index stroke (known or known AF).⁷ MT is effective and safe in AIS attributable to LVO of the anterior and posterior circulation, irrespective of the cause. Previous studies have produced conflicting results on the post-MT outcomes in patients with acute LVO stroke with AF and their counterparts without AF^{8–28} (Table 1). An individual patient

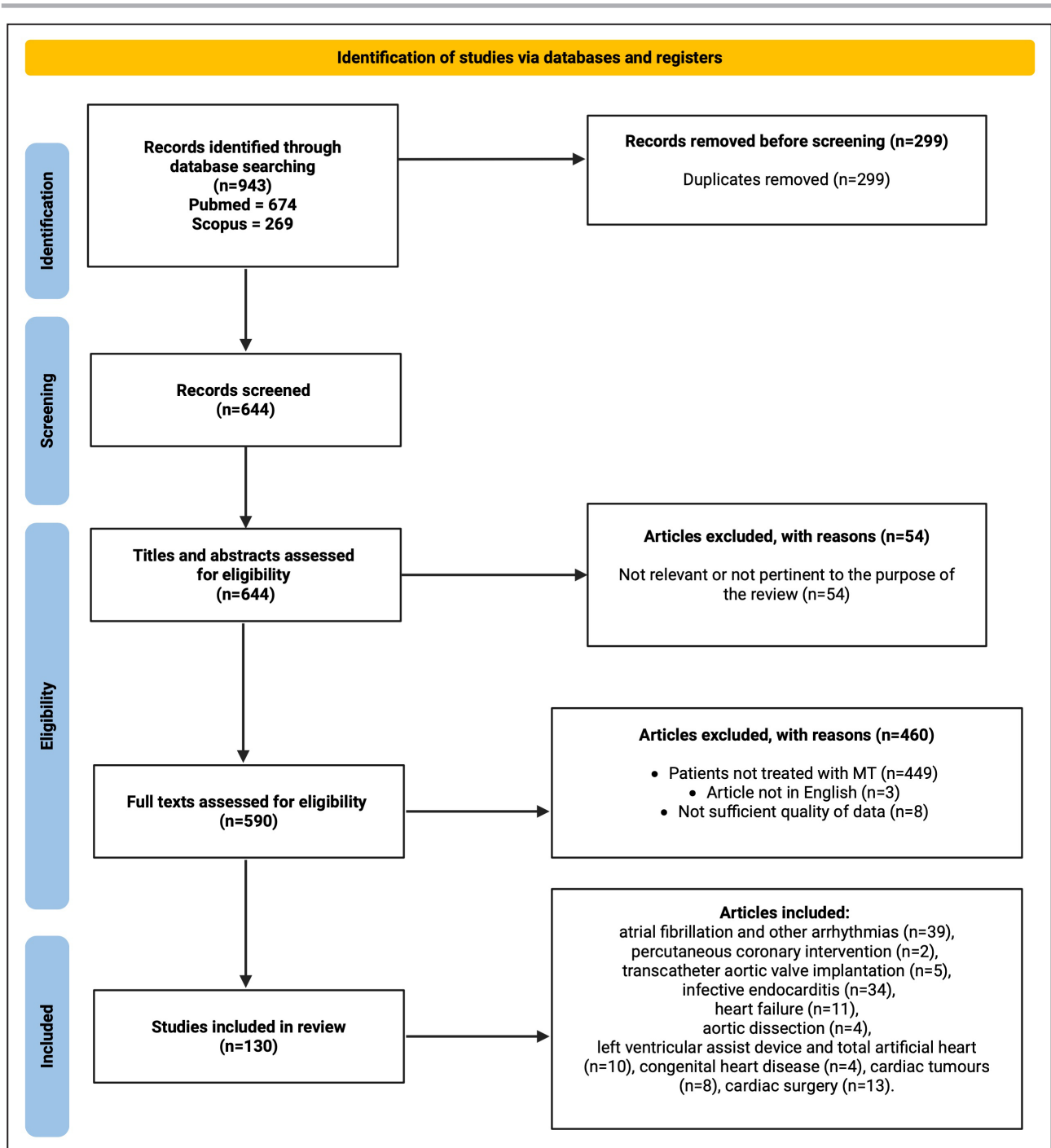


Figure 1. Preferred reporting items for systematic reviews and meta-analyses flowchart for study selection
MT indicates mechanical thrombectomy.

data analysis of 6 randomized clinical trials^{29–34} involved 1351 patients, of whom 447 (33.1%) with AF showed no significant correlation between the presence of AF and outcome of MT.³⁵ Moreover, a recent meta-analysis of adjusted effect estimates, comprising 16096 patients, detected no significant differences in 90-day functional outcomes and mortality after MT in patients with AIS

with and without AF.³⁶ Kobeissi et al³⁷ performed a systematic review and meta-analysis including 10 studies with 6543 patients. Overall, the authors found that there were comparable rates of modified Rankin Scale (mRS) score of 0 to 2 between patients with AF and patients without. However, after sensitivity analysis, the rate of mRS scores of 0 to 2 was significantly lower among

Table 1. Atrial Fibrillation and Mechanical Thrombectomy

Reference	Study type	Total No. of patients	Age, y	Patients treated with MT, n (%)	Patients with mRS score 0–2 at 90 d, n (%)	Patients with mRS score of 6 at 90 d, n (%)	Patients with sICH, n (%)	Patients with successful recanalization (mTICI 2b–3), n (%)	Summary of study findings
Akbik et al 2021 ⁸	Retrospective multicenter cohort study	5621 Patients with AIS undergoing MT, of whom 1517 (36.4%) with AF	No AF: mean, 65 (±SD: 15) AF: mean, 76 (±SD: 11)	5621 (100)	No AF: 1029 (42) AF: 426 (31)*	No AF: 408 (17) AF: 354 (26)	No AF: 160 (7) AF: 89 (8)	No AF: 2108 (85) AF: 1204 (84)	Comorbid AF was associated with better clinical outcomes in patients with AIS undergoing MT
Huang et al 2021 ⁹	Retrospective multicenter cohort study	245 Patients with AIS undergoing MT, of whom 123 (50.2%) with AF	No AF: median, 64 (IQR, 54–71) AF: median, 74 (IQR, 67–79)*	245 (100)	No AF: 60 (49.2) AF: 40 (32.5)*	No AF: 20 (16.4) AF: 37 (30.1)*	No AF: 7 (5.7) AF: 12 (9.8)	No AF: 114 (93.4) AF: 103 (83.7)*	Comorbid AF was associated with worse clinical outcomes in patients with AIS undergoing MT (but not at matched analysis)
Lasek-Bal et al 2021 ¹⁰	Retrospective single-center cohort study	421 Patients with AIS undergoing MT, of whom 108 (25.9%) with AF	No AF: mean, 65.7 (±SD: 18.9) AF: mean, 73.8 (±SD: 9.0)	421 (100)	No AF: 89 (36.2) AF: 28 (32.5)	No AF: 9 (3.7) AF: 5 (5.8)	No AF: 15 (4.9) AF: 7 (6.5)	No AF: 202 (66) AF: 72 (67)	MT may have similar clinical outcomes in patients with AIS with vs without AF
Lasek-Bal et al 2021 ¹⁰	Retrospective single-center cohort study	417 AIS, AF 108 (25.89%)	AF 73.77 (±SD: 8.97); no AF 65.70 (±SD: 18.88)	417 (100)	AF 25 (32.1); no AF 70 (23)	AF 18 (16.7); no AF 53 (17.4)	AF 26 (24), no AF 69 (22)	AF 72 (67), no AF 202 (66)	AF does not impact on outcome after MT
Leker et al 2020 ¹¹	Retrospective single-center cohort study	230 Patients with AIS undergoing MT, of whom 21 (9.1%) with adequately treated AF and 88 (38.3%) with undertreated AF	No AF: mean, 64.5 (±SD: 15.1) Treated AF: mean, 75.7 (±SD: 11.4)* Undertreated AF: mean, 74.9 (±SD: 11.9)*	230 (100)	No AF: 51 (42) Treated AF: 2 (9)* Undertreated AF: 25 (28)	No AF: 23 (20) Treated AF: 3 (15) Undertreated AF: 9 (11)	No AF: 5 (4) Treated AF: 3 (14) Undertreated AF: 3 (3)	No AF: 58 (48) Treated AF: 11 (52) Undertreated AF: 59 (67)	MT is safe and effective in patients with AF independently from the adequacy of AF treatment
Lin et al 2020 ¹²	Retrospective single-center cohort study	83 Patients with AIS receiving MT, of whom 43 (51.8%) with AF	No AF: mean, 70.9 (±SD: 17.3) AF: mean, 72.6 (±SD: 9.5)	83 (100)	No AF: 7 (17.5) AF: 24 (55.8)*	No AF: 6 (15.0) AF: 4 (9.3)	No AF: 4 (10.0) AF: 3 (7.0)	No AF: 22 (55.0) AF: 31 (72.1)	MT may have better clinical outcomes in patients with AIS with vs without AF
Fu et al 2021 ¹³	Retrospective multicenter cohort study	349 Patients with AIS undergoing MT, of whom 171 (49%) with AF	No AF: median, 67 (IQR: 37–79) AF: median, 78 (IQR: 70–83)*	349 (100)	No AF: 85 (47.8) AF: 82 (48.0)	No AF: 32 (18.0) AF: 37 (21.6)	No AF: 7 (3.9) AF: 2 (1.2)	No AF: 171 (96.1) AF: 169 (98.8)	MT has similar clinical outcomes in patients with AIS with vs without AF
Zdraljovic et al 2022 ¹⁴	Prospective multicenter cohort study	127 Patients with AIS undergoing MT, of whom 62 (48.8%) with AF	No AF: median, 61 (IQR: 50.5–68) AF: median, 74.5 (IQR: 66.5–79)*	127 (100)	No AF: 35 (53.8) AF: 19 (30.6)	No AF: 11 (16.9) AF: 22 (35.3)*	No AF: 5 (7.7) AF: 6 (9.7)	No AF: 56 (86.2) AF: 55 (88.7)	MT has similar clinical outcomes in patients with AIS with vs without AF

(Continued)

Table 1. Continued

Reference	Study type	Total No. of patients	Age, y	Patients treated with MT, n (%)	Patients with mRS score 0–2 at 90 d, n (%)	Patients with mRS score of 6 at 90 d, n (%)	Patients with sICH, n (%)	Patients with successful recanalization (mTICI 2b–3), n (%)	Summary of study findings
Heshnatollah et al 2017 ¹⁵	Randomized clinical trial	500 Patients with AIS undergoing MT, of whom 135 (27%) with AF	No AF: median, 61 (IQR: 52–73) AF: median, 72 (IQR: 66–80)*	No AF: 167 (45.2) AF: 66 (48.9)	No AF: 63 (38) AF: 12 (18)*	NA	No AF: 11 (6.6) AF: 7 (10.6)	No AF: 78/136 (57) AF: 38/61 (62)	MT may have similar clinical outcomes in patients with AIS with vs without AF
Zhao et al 2022 ⁴⁴	Prospective multicenter cohort study	647 Patients with AIS undergoing MT, of whom 136 (21.0%) with AF	No AF: median, 63 (IQR: 55–70) AF: median, 73 (IQR: 65–78)	647 (100)	Data available only for 90-d mRS score 0–3 vs 4–6 No AF: 159 (31.1) AF: 48 (35.3)	No AF: 234 (45.8) AF: 65 (47.8)	No AF: 34 (6.8) AF: 11 (8.2)	No AF: 411 (80.4) AF: 111 (81.6)	MT has similar clinical outcomes in patients with AIS with basilar artery occlusion with vs without AF
Mujanovic et al 2022 ¹⁶	Observational multicenter cohort study	2941 Patients with AIS undergoing MT, of whom 1347 (45.8%) with AF	AF: median, 78 (IQR: 69–84)	1347 Patients with AF (100), of whom 632 (46.9%) received bridging IVT	All AF: 418 (39.4) No IVT: 182 (33.3) IVT: 236 (46.0)*	All AF: 206 (25.1) No IVT: 124 (28.1) IVT: 82 (21.6)*	All AF: 72 (5.4) No IVT: 37 (5.2) IVT: 35 (5.6)	NA	MT may have better clinical outcomes in association with bridging IVT in patients with AIS with AF
Tong et al 2021 ¹⁷	Prospective multicenter cohort study	1026 Patients with AIS undergoing MT, of whom 340 (33.1%) with AF	No IVT: median, 66 (IQR: 55–74) IVT: median, 64 (IQR: 55–72)	1026 (100), of whom 426 (41.5) received bridging IVT	No IVT: 251/568 (44.2) IVT: 174/405 (43.0)	No IVT: 93/568 (16.4) IVT: 62/405 (15.3)	No IVT: 33/569 (5.8) IVT: 42/407 (10.3)	No IVT: 379/426 (89.0) IVT: 523/600 (87.2)	MT may have similar clinical outcomes in association with bridging IVT in patients with AIS
Alobaida et al 2023 ¹⁸	Retrospective multicenter cohort study	3106 Patients with AIS undergoing MT, of whom 1718 (55.3%) with AF	No AF: mean, 61.1 (±SD: 14.8) AF: mean, 73.6 (±SD: 12.6)*	3106 (100)	NA	No AF: 24.2% AF: 20.6%	NA	NA	MT may have similar clinical outcomes in patients with AIS with vs without AF
Munir et al 2017 ¹⁹	Observational multicenter study cohort	4627 Patients with AIS undergoing MT, of whom 1480 (32.0%) with AF	No AF: mean, 60 (±SD: 15) AF: mean, 74 (±SD: 11)*	4627 (100)	NA	NA	NA	NA	No difference in in-hospital mortality in patients with AIS undergoing MT with vs without AF
Loo et al 2023 ²⁰	Retrospective cohort study	705 Patients with AIS (314 AF and 391 non-AF)	Bridging IVT: AF 73.2 (±SD:10.3) and non-AF 65.6 (±SD:14.1); No bridging IVT: AF 73.6 (±SD:10.9) and non-AF 64.7 (±SD:16.0)	705 (100)	Bridging IVT: AF 63 (35) and non-AF 118 (45.2) No bridging IVT: AF 43 (33.3) and non-AF 28 (23.7)	Bridging IVT: AF 34 (18.9) and non-AF 41 (15.7) No bridging IVT: AF 25 (19.4) and non-AF 22 (18.6)	Bridging IVT: AF 20 (11) and non-AF 34 (12.8) No bridging IVT: AF 10 (7.7) and non-AF 17 (13.9)	Bridging IVT: AF 158 (87.3) and non-AF 231 (89.2) No bridging IVT: AF 117 (89.3) and non-AF 100 (84)	Presence of AF did not impact on treatment effect of bridging IVT
Yang et al 2023 ²¹	Retrospective cohort study	1036 AIS (432 AF and 604 no AF)	Aged >65: AF 350/432 (81%); no AF 325/604 (53.8%)	1036 (100)	AF: 161/432 (37.3); no AF: 315/604 (52.2)	AF: 110/432 (25.5); no AF: 97/604 (16.1)	AF: 23/390 (5.9); no AF: 17/544 (3.1)	AF: 360/427 (84.3); no AF: 511/573 (89.2)	AF-related stroke is associated with worse outcome in patients with poor collaterals

(Continued)

Table 1. Continued

Reference	Study type	Total No. of patients	Age, y	Patients treated with MT, n (%)	Patients with mRS score 0–2 at 90 d, n (%)	Patients with mRS score of 6 at 90 d, n (%)	Patients with sICH, n (%)	Patients with successful recanalization (mTICI 2b–3), n (%)	Summary of study findings
Pillai et al 2023 ²²	Multicenter, prospective study	253 AIS (AF 67 and no AF 186)	Median age: AF 74 (IQR 66–82); no AF 67.5 (IQR 58–77)	253 (100)	Bridging IVT: AF 14 (48.28) and non-AF 65 (67.01) No bridging IVT: AF 15 (39.47) and non-AF 55 (61.80)	Bridging IVT: AF 6 (20.69) and non-AF 12 (12.37) No bridging IVT: AF 10 (26.32) and non-AF 10 (11.24)	NA	AF: 64 (95.52); no AF 169 (91.35)	AF-related strokes associated with first-pass effect
Wu et al 2023 ²³	Retrospective multicenter cohort study	221 Patients with AIS undergoing MT, of whom 79 (35.7%) with AF	No AF: mean, 61.8 (±SD: 13.5) AF: mean, 70.1 (±SD: 11.7)*	221 (100)	No AF: 63 (44.4) AF: 31 (39.2)	No AF: 35 (24.7) AF: 26 (32.9)	No AF: 8 (10.1) AF: 18 (12.7)	No AF: 119 (83.8) AF: 58 (73.4)	MT may have similar clinical outcomes in patients with AIS with vs without AF
Nogueira et al 2023 ²⁴	Retrospective cohort study	1122 AIS; 39% AF, 61% no AF	NA	1122 (100)	NA	NA	NA	NA	Patients with AF prone to severe ICH
Churojana et al 2018 ²⁵	Retrospective single-center cohort study	134 Patients with AIS undergoing MT, of whom 50 (37.3%) with AF	No AF: mean, 60.2 (±SD: 12.9) AF: mean, 69.2 (±SD: 12.9)*	134 (100)	No AF: 32 (38.1) AF: 19 (38)	No AF: 16 (19) AF: 10 (20)	No AF: 11 (13.1) AF: 6 (12)	No AF: 64 (76.2) AF: 38 (76)	MT may have similar clinical outcomes in patients with AIS with vs without AF
Sur et al 2021 ²⁶	Retrospective observational single-center cohort study	347 Patients with AIS undergoing MT, of whom 161 (46.4%) with AF	No AF: mean, 66.3 (±SD: 14.9) AF: mean, 76.1 (±SD: 11.1)	347 (100)	No AF: 47 (26.6) AF: 46 (30)	Only intrahospital mortality data available No AF: 32 (18.1) AF: 34 (22.1)	No AF: 23 (6.8) AF: 10 (5.5)	No AF: 150 (86.7) AF: 133 (87.5)	MT may have similar clinical outcomes in patients with AIS with vs without AF
Smaal et al 2020 ³⁵	Meta-analysis of 6 RCTs	1349 Patients with AIS, of whom 447 (33.1%) with AF	No AF, MT: mean, 63.1 (±SD: 13.7) AF, MT: mean, 72.8 (±SD: 10.1)*	No AF: 443 (49.1) AF: 224 (50)	Data only available as aOR AF vs no AF: OR=1.14 (95% CI=0.87–1.51)	Data only available as aOR AF vs no AF: OR=1.14 (95% CI=0.83–1.57)	Data only available as aOR AF vs no AF: OR=0.80 (95% CI=0.44–1.47)	NA	No significant interaction between AF and MT outcomes
Zheng et al 2023 ³⁶	Meta-analysis of 18 studies	16096 Patients with AIS, of whom 6862 (42.6%) with AF	Mean, 70.1	16096 (100)	Data only available as aOR AF vs no AF: aOR=1.14 (95% CI=0.95–1.37)	Data only available as aOR AF vs no AF: aOR=0.92 (95% CI=0.79–1.08)	Data only available as aOR AF vs no AF: aOR=0.97 (95% CI=0.71–1.32)	Data only available as aOR AF vs no AF: aOR=1.07 (95% CI=1.0–1.15)	MT may have similar clinical outcomes in patients with AIS with vs without AF
Kobeissi et al 2023 ³⁷	Meta-analysis of 10 observational studies	6543 Patients with AIS	NA	6543 (100)	No AF: 1614/3826 (42.2) AF: 766/2305 (33.2)	No AF: 587/3826 (15.3) AF: 536/2305 (23.3)	No AF: 233/3559 (6.5) AF: 138/2055 (6.7)	No AF: 2823/3427 (82.4) AF: 1782/2150 (82.3)	MT may have worse clinical outcomes in patients with AIS with vs without AF
D'Anna et al 2023 ³⁸	Prospective single-center study	518 Patients with AIS undergoing MT, of whom 122 (22.2%) with known AF and 107 (21%) with newly diagnosed AF	No AF: mean, 62.7 (±SD: 14.6) New AF: mean, 72.6 (±SD: 13.4) Known AF: mean, 74.9 (±SD: 9.6)	518 (100)	No AF: 173 (59.9) New AF: 71 (66.4) Known AF: 80 (65.6)	No AF: 28 (9.7) New AF: 5 (4.7) Known AF: 15 (12.3)	No AF: 19 (3.7) New AF: 2 (0.4)* Known AF: 2 (0.4)*	No AF: 238 (83.2) New AF: 89 (84.0) Known AF: 101 (82.8)	MT may have similar clinical outcomes in patients with AIS with vs without AF

(Continued)

Table 1. Continued

Reference	Study type	Total No. of patients	Age, y	Patients treated with MT, n (%)	Patients with mRS score 0–2 at 90 d, n (%)	Patients with mRS score of 6 at 90 d, n (%)	Patients with sICH, n (%)	Patients with successful recanalization (mTICI 2b–3), n (%)	Summary of study findings
D'Anna et al 2023 ³⁹	Prospective single-center cohort study	573 Patients with AIS undergoing MT, of whom 99 (17.3%) on OAC (89.9% for AF)	No OAC: mean, 71.9 (±SD: 13.1) OAC: mean, 72 (±SD: 11.1)	573 (100)	No OAC: 150 (39.5) OAC: 33 (33.7)	No OAC: 84 (21.2) OAC: 20 (20.2)*	No OAC: 20 (5.1) OAC: 1 (1)	No OAC: 324 (83.3) OAC: 78 (78.8)	MT may have similar clinical outcomes in patients with AIS with vs without OAC
Wang et al 2022 ²⁷	Retrospective single-center cohort study	133 Patients with AIS undergoing MT with AF, of whom 39 (29.3%) on OAC	No OAC: mean, 74 (±SD: 10) OAC: mean, 69 (±SD: 11)	133 (100)	No OAC: 31 (33) OAC: 17 (44)	No OAC: 23 (24) OAC: 8 (21)	No OAC: 13 (14) OAC: 5 (13)	No OAC: 81 (86) OAC: 38 (97)	MT may have similar clinical outcomes in patients with AIS with vs without OAC
Leker et al 2020 ⁴⁰	Retrospective observational cohort study	230 Patients with AIS undergoing MT, of whom 86 (37.4%) with known AF and 23 (10.0%) with newly diagnosed AF	No AF: mean, 64.5 (±SD: 15.1) Known AF: mean, 76.6 (±SD: 12.2) New AF: mean, 74.6 (±SD: 11.7)	230 (100)	No AF: 51 (42) Known AF: 22 (25) New AF: 5 (21)*	No AF: 23 (20) Known AF: 18 (21) New AF: 4 (18)	No AF: 5 (4) Known AF: 5 (6) New AF: 1 (4)	No AF: 58 (48) Known AF: 68 (79) New AF: 18 (78)*	MT may have similar clinical outcomes in patients with AIS with vs without AF
Benavente et al 2016 ⁴¹	Prospective observational single-center cohort study	117 Patients with AIS undergoing MT, of whom 30 (25.6%) on OAC (87.5% for AF)	No OAC: mean, 67.1 (±SD: 10.6) OAC: mean, 72.8 (±SD: 7.9)	117 (100)	No OAC: 54.2% OAC: 46.7%	No OAC: 21.7% OAC: 6.7%	No OAC: 8.2% OAC: 16.7%	No OAC: 90.0% OAC: 93.3%	MT may have similar clinical outcomes in patients with AIS with vs without OAC
L'Allinec et al 2018 ⁴²	Prospective observational multicenter cohort study	333 Patients with AIS, of whom 40 (12.0%) on OAC (75% for AF)	OAC: mean, 75 (±SD: 13) No OAC, no IVT: mean, 64 (±SD: 14)* No OAC, IVT: mean, 61 (±SD: 15)*	333 (100), of whom 188 (56.5) with bridging IVT	OAC: 14/38 (37) No OAC, no IVT: 52/102 (51) No OAC, IVT: 102/173 (59)*	OAC: 10/38 (26) No OAC, IVT: 14/173 (8) No OAC, IVT vs OAC: OR=0.25 (95% CI=0.10–0.61)* No OAC, no IVT vs OAC: OR=0.41 (95% CI=0.16–1.03)	Data only available as OR No OAC, IVT vs OAC: OR=0.44 (95% CI=0.09–2.08) No OAC, no IVT vs OAC: OR=0.69 (95% CI=0.13–3.68)	OAC: 30 (75) No OAC, no IVT: 79 (75) No OAC, IVT: 151 (80)	MT may have similar clinical outcomes in patients with AIS with vs without OAC
Feng et al 2023 ⁴⁵	Prospective multicenter cohort study	2134 Patients with AIS undergoing MT, of whom 619 (29.0%) with AF	No AF: median, 65 (IQR: 55–73) AF: median, 66 (IQR: 57–74)	2134 (100)	No AF: 469 (31) AF: 205 (33.1)	No AF: 594 (39.2) AF: 243 (39.3)	No AF: 59 (3.9) AF: 30 (4.8)	NA	MT may have similar clinical outcomes in patients with AIS with vs without AF
Pan et al 2016 ²⁸	Prospective observational single-center cohort study	35 AIS; AF 10; no AF 25	AF 65 (±SD: 8/17); no AF 56.64 (±SD: 7.93)	35 (100)	NA	AF 4 (40); no AF 6 (24)	NA	AF 83%; no AF 20%	AF predicts higher recanalization rates
Chang et al 2023 ⁴³	Retrospective observational single-center cohort study	109 AIS; 32 AF	NA	NA	NA	NA	NA	NA	AF independent predictor of sICH after MT

AF indicates atrial fibrillation; AIS, acute ischemic stroke; aOR, adjusted OR; IQR, interquartile range; IVT, intravenous thrombolysis; mTICI, modified Treatment in Cerebral Ischemia; mRS, modified Rankin Scale; MT, mechanical thrombectomy; NA, not available; OAC, oral anticoagulation; OR, odds ratio; RCT, randomized clinical trial; and sICH, symptomatic intracranial hemorrhage.

*Significantly different at $P < 0.05$.

patients with AF. Furthermore, the authors documented that mortality was significantly higher in the AF group, with no significant heterogeneity observed. These results were, however, not always consistently observed, especially in the elderly population.³⁸ Indeed, similar rates of successful reperfusion (modified Treatment in Cerebral Ischemia score, 2b–3) were found in patients with AF and their counterparts without AF after MT.³⁹ Although some studies identified AF as a risk factor for postprocedural symptomatic intracerebral hemorrhage,⁹ more recent data did not show significant differences in the rates of intracerebral hemorrhage and symptomatic intracerebral hemorrhage in patients with acute stroke with and without AF treated with MT.^{36,37} Patients with AIS with AF undergoing MT showed more frequently higher rates of comorbidities,³⁷ higher National Institutes of Health Stroke Scale score on admission, and lower Alberta Stroke Program Early CT [Computed Tomography] Score on admission⁸ compared with their counterparts without AF. Moreover, patients with LVO stroke with AF were less likely to be eligible for intravenous thrombolysis^{8,37} (IVT) because of their prestroke use of anticoagulants. Conversely, AF was associated with a lower number of attempts to successful recanalization, higher odds of first-pass success, and shorter procedure times.⁸ To date, limited evidence is available on the outcome profile between patients with AF detected after stroke and known AF and AIS attributable to LVO following MT. Leker et al investigated the influence of AF temporal detection on outcome after MT⁴⁰ and found no significant impact of the different subtypes of AF diagnosis on favorable mRS outcome following MT. In a more recent study with a cohort of patients with acute LVO ischemic stroke treated with MT, the authors did not observe a significant difference in terms of functional independence at 3 months when comparing patients with known AF to patients with AF detected after stroke and their counterparts without AF.³⁹ Only few studies have reported the procedural techniques used. Huang et al did not show significant differences between patients with and without AF undergoing MT in terms of procedural features.⁹ Similar results were obtained by D'Anna et al when comparing the use of thromboaspiration, stent retriever, and the combination of both techniques in patients with no AF, AF detected after stroke, and known AF.³⁹ AF, per se, is not a risk factor for risk of hemorrhagic transformation after MT, as suggested by previous studies.^{39,41–43} Finally, although studies assessing specifically the outcomes of patients with AF basilar artery occlusion receiving MT are relatively scarce, their results showed that the effect of MT did not differ statistically in patients with AIS with and without AF.^{44,45}

Atrial high-rate episodes represent a risk factor for AIS and other cardioembolic events, especially when

>30 seconds.⁴⁶ Subjects with documented atrial high-rate episodes have a risk of developing AF, which is estimated to be ≈8% to 9% per year.⁴⁷ It is not established if a prophylactic anticoagulation therapy is indicated in patients with atrial high-rate episodes, given that no benefit has been observed.^{48,49} To date, no studies assessed specifically the safety and the clinical outcomes of MT in patients with AIS in relationship to atrial high-rate episodes.

Summary of data (Figure 2):

- There are clear benefits of treating with MT the LVO patients with ischemic stroke and AF;
- Although some data are conflicting, in general, MT in patients with and without AF shows similar 90-day functional outcome and mortality rates;
- Patients with AF undergoing MT showed more frequently higher rates of comorbidities compared with their counterparts without AF; and this, not the recanalization procedure in itself, could impact on longer-term functional outcomes after MT.

Percutaneous Coronary Intervention

AIS is an uncommon complication of percutaneous coronary intervention (PCI).⁵⁰ The reported incidence of post-PCI ischemic stroke has varied among different studies. A recent analysis of the National Inpatient Sample⁵¹ with 8 753 574 patients undergoing PCI revealed that the post-PCI incidence of ischemic stroke was 0.56%; however, it was higher after PCI for ST-segment–elevation myocardial infarction (0.97%) and PCI for non–ST-segment–elevation myocardial infarction (0.81%) than after PCI for unstable angina or stable ischemic heart disease (0.41%). Among patients with post-PCI stroke, the rates of MT were 0.65% (Table 2). Saini et al described 4 patients who developed AIS attributable to LVO during cardiac catheterization.⁵² All the cases were identified while still in the cardiac catheterization suite, and they were treated by the cardiologist via a transfemoral arterial access and using solitaire stent retriever with balloon guide catheter technique. To improve and expedite a definitive diagnosis of LVO, allowing a rapid access to MT in patients undergoing cardiac catheterization, Saini et al proposed a triage strategy of “direct” cerebral digital diagnostic subtraction angiogram bypassing conventional computed tomography of the head.⁵² Patients did not experience complications after the procedure. However, further studies are needed to prove the use of this approach in routine clinical practice. The occurrence of cerebrovascular stroke after coronary revascularization is a substantial complication, with a higher frequency after coronary artery bypass grafting (CABG) compared with PCI.⁵⁰

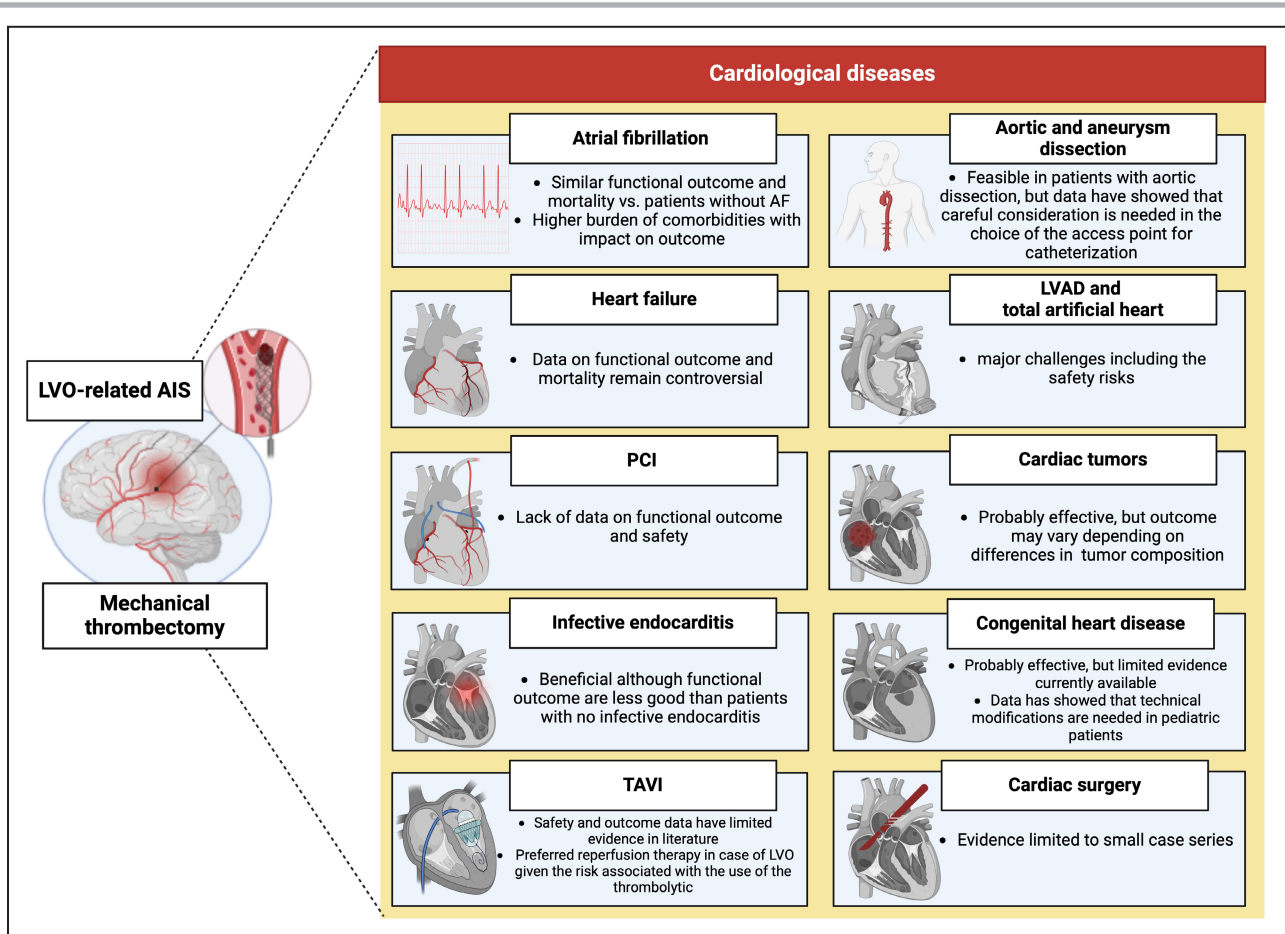


Figure 2. Summary of results per cardiac pathology

AF indicates atrial fibrillation; AIS, acute ischemic stroke; LVAD, left ventricular assist device; LVO, large-vessel occlusion; PCI, percutaneous coronary intervention; and TAVI, transcatheter aortic valve implantation.

Summary of data (Figure 2):

- There is a lack of data on outcomes of post-PCI patients with stroke treated with MT.

Transcatheter Aortic Valve Implantation

Transcatheter aortic valve implantation (TAVI) is an increasingly used treatment modality for patients with severe aortic stenosis with high or intermediate surgical risk with a considerable risk of periprocedural cerebrovascular embolic events.^{53–55} Despite the fact that MT represents the standard of care for AIS in selected patients, its efficacy and safety in patients undergoing TAVI have limited evidence in the literature. To date, the use of MT for ischemic stroke after TAVI has only been documented in a few case reports in the literature^{56–60} (Table 3). Gupta et al⁵⁶ described the case of a 74-year-old man with stroke post-TAVI treated with successful thromboaspiration MT after 3 passes, whereas in the case described by Matsuo et al,⁵⁹ successful recanalization of the entire left middle cerebral artery was achieved with a direct-aspiration first-pass procedure

performed twice. Finally, Coughlan et al⁵⁸ reported that 4 passes were made using the Trevo device to achieve successful recanalization in their clinical case of stroke post-TAVI. The severe bleeding from the TAVI access developed during the infusion of IVT suggested that the use of the lytic therapy in patients with acute stroke after TAVI should be considered on a case-by-case basis only.⁶⁰

Summary of data (Figure 2):

- The safety and efficacy of patients with post-TAVI LVO stroke have limited evidence in literature;
- MT in patients with AIS attributable to LVO post-TAVI insertion represents the preferred reperfusion therapy given the risk associated with the use of the thrombolytic.

Infective Endocarditis

AIS is the most common neurologic complication of infective endocarditis (IE), manifesting clinically in 20% to 40% of the patients.^{61,62} Treatment of patients with

Table 2. Percutaneous Coronary Intervention and Mechanical Thrombectomy

Reference	Study type	Total No. of patients	Age, y	Patients treated with MT, n (%)	Patients with mRS score 0–2 at 90 d, n (%)	Patients with mRS score of 6 at 90 d, n (%)	Patients with sICH, n (%)	Patients with successful recanalization (mTICI 2b–3), n (%)	Summary of study findings
Saini et al 2020 ⁶²	Case series	4	Mean, 63	4 (100)	3 (75)	0 (0)	0 (0)	3/3 (100, in 1 case NA)	MT in CC suite can be feasible
Alkhouli et al 2019 ⁵¹	Cohort study	8753574 Patients undergoing PCI, of whom 49097 (0.6%) with AIS	AIS after PCI for STEMI: mean, 68 (±SD: 13) AIS after PCI for NSTEMI: mean, 70 (±SD: 12) AIS after PCI for UA/SIHD: mean, 69 (±SD: 12)	0.65%	NA	NA	NA	NA	Low use of MT after PCI, although rate is increasing over time

AIS indicates acute ischemic stroke; CC, cardiac catheterization; mTICI, modified Treatment in Cerebral Ischemia; mRS, modified Rankin Scale; MT, mechanical thrombectomy; NA, not available; NSTEMI, non-ST-segment-elevation myocardial infarction; PCI, percutaneous coronary intervention; SIHD, stable ischemic heart disease; sICH, symptomatic intracranial hemorrhage; STEMI, ST-segment-elevation myocardial infarction; and UA, unstable angina.

acute stroke secondary to IE is often suboptimal as thrombolytic therapy is contraindicated because of the high risk of hemorrhagic transformation of the infarct.^{63,64} Despite MT being the standard of care for AIS with LVO, its efficacy and safety in patients with stroke secondary to IE have limited evidence in the literature.^{64–73} Table 4 shows the key studies. A review of the literature⁷⁴ using the Preferred Reporting Items for Systematic Reviews and Meta-Analyses framework described 30 patients reported in 19 published case series of 431 screened records.^{75–93} According to these findings, MT was as effective as in patients

presenting with LVOs attributable to nonendocarditis causes. The median National Institutes of Health Stroke Scale score decreased from 15 before to 2.5 after the procedure. Intracranial hemorrhage occurred in 13.3% of patients, and the overall mortality at 90 days was 23.3%. Functional independence with an mRS score of <2 was achieved in 46.7% of patients. Two large case-control studies compared the outcomes after MT of patients with AIS attributable to IE with patients with AF-related stroke.^{94,95} Marnat et al described a case series of 28 patients with ischemic stroke related to IE who were compared with 84 patients with AIS

Table 3. Transcatheter Aortic Valve Implantation and Mechanical Thrombectomy

Reference	Study type	Total No. of patients	Age, y	Patients treated with MT, n (%)	Patients with mRS score 0–2 at 90 d, n (%)	Patients with mRS of 6 at 90 d, n (%)	Patients with sICH, n (%)	Patients with successful recanalization (mTICI 2b–3), n (%)	Summary of study findings
Gupta et al 2022 ⁵⁶	Case report	2	74 and 88	2 (100)	2 (100)	0 (0)	0 (0)	2 (100)	MT after TAVI associated with excellent outcome
Pyra et al 2020 ⁵⁷	Case report	1	77	1 (100)	1 (100)	0 (0)	0 (0)	1 (100)	MT after TAVI associated with excellent outcome
Coughlan et al 2017 ⁵⁸	Case report	1	80	1 (100)	1 (100)	0 (0)	0 (0)	1 (100)	MT after TAVI is effective
Matsuo et al 2017 ⁵⁹	Case report	1	90	NA	NA	NA	0 (0)	1 (100)	MT after TAVI is effective
D'Anna et al 2019 ⁶⁰	Case report	1	98	1 (100)	1 (100)	0 (0)	0 (0)	1 (100)	MT after TAVI is effective and safe

mRS indicates modified Rankin Scale; MT, mechanical thrombectomy; mTICI, modified Treatment in Cerebral Ischemia; NA, not available; sICH, symptomatic intracranial hemorrhage; and TAVI, transcatheter aortic valve implantation.

Downloaded from http://ahajournals.org by on November 11, 2024

Table 4. Infective Endocarditis and Mechanical Thrombectomy

Reference	Study type	Total No. of patients	Age, y	Patients treated with MT, n (%)	Patients with mRS score 0–2 at 90d, n (%)	Patients with mRS score of 6 at 90d, n (%)	Patients with sICH, n (%)	Patients with successful recanalization (mTICI 2b–3), n (%)	Summary of study findings
D'Anna et al 2020 ⁷⁴	Literature review of 19 studies	30	Median, 67 (IQR: 32–75)	30 (100)	14 (46.7)	7 (23.3)	4 (13.3)	13 (43.3)	MT in patients with IE should be considered case by case as safety not established yet
Feil et al 2021 ⁹⁴	Retrospective observational multicenter cohort study	6635 Patients with AIS undergoing MT, of whom 159 included in the final analysis (55 with IE, 34.6%, 104 matched controls with cardioembolism, 65.4%)	Cardioembolism: mean, 66.5 (±SD: 13.4) IE: mean, 69.0 (±SD: 13.3)	159 (100)	Cardioembolism: 45 (43.3) IE: 11 (20.0)*	Cardioembolism: 30 (28.8) IE: 33 (60.0)*	Cardioembolism: 21 (20.2) IE: 14 (25.5)	CE: 91 (87.5) IE: 41 (74.5)*	MT is associated with worse clinical outcomes in patients with AIS with IE vs cardioembolism
Marnat et al 2021 ⁹⁵	Retrospective observational multicenter cohort study	112 Patients with AIS undergoing MT, of whom 28 (25%) with IE	Cardioembolism: mean, 61.4 (±SD: 16.5) IE: mean, 59.2 (±SD: 17.6)	112 (100)	Cardioembolism: 39/77 (50.6) IE: 7/27 (25.9)*	Cardioembolism: 15/77 (19.5) IE: 7/27 (25.9)	Cardioembolism: 4/77 (5.2) IE: 2/25 (8.0)	Cardioembolism: 80/84 (95.2) IE: 24/28 (85.7)	MT is associated with worse clinical outcomes in patients with AIS with IE vs cardioembolism
Bolognese et al 2018 ⁷⁹	Case report and literature review of 13 cases	14	Mean, 49 (range: 24–78)	14 (100)	NA	NA	0 (0)	NA	MT may be considered in AIS attributable to IE
Mowla et al 2022 ⁹⁶	Meta-analysis of 6 studies	120	Mean, 57.2 Median, 75.5	120 (100)	NA	50/84 (59.5)	31 (25.8)	89 (74.2)	MT may be considered in AIS attributable to IE
Marquardt et al 2019 ⁶⁹	Literature review and case series	40	No MT: median, 61.5 (IQR: 48–69) MT: median, 48.5 (37.5–67)	21 (52.5)	No MT: 7/19 (37) MT: 13/21 (62)	Only intrahospital mortality data available No MT: 4/19 (21) MT: 4/21 (19)	No MT: 8/19 (42) MT: 2/17 (12)	NA	MT may be considered in AIS attributable to IE

AIS indicates acute ischemic stroke; IE, infective endocarditis; IQR, interquartile range; mRS, modified Rankin Scale; MT, mechanical thrombectomy; mTICI, modified Treatment in Cerebral Ischemia; NA, not available; and sICH, symptomatic intracranial hemorrhage.

*Significantly different at $P < 0.05$.

attributable to AF.⁹⁵ The case-control study found no difference between the 2 groups in terms of recanalization rate, whereas patients with stroke attributable to IE less frequently reached functional independence at 90 days after the index event compared with those with stroke attributable to AF.⁹⁵ The first-line strategy MT techniques used did not differ between the 2 groups of patients. A larger case-control study from the German stroke registry showed lower rate of successful recanalization (74.5% versus 87.5%; $P=0.039$), comparable rates of intracranial hemorrhage (30.9% versus 21.6%; $P=0.175$), lower proportion of good functional outcome (20.0% versus 43.3%; $P=0.006$), and higher mortality (60.0% versus 28.8%; $P < 0.001$) after MT in patients with IE compared with those with AF-related stroke.⁹⁴ A similar number of favorable outcomes was also found in other reviews.^{79,96} On the basis of the available data, MT in patients with IE appears to carry some more risks and less benefits to those in patients

without IE. Despite this, MT should not be withheld from patients with IE.^{71,97}

Summary of data (Figure 2):

- MT is beneficial in patients with AIS and LVO attributable to IE, although functional outcomes are less good than in patients with AIS and LVO without IE.

Heart Failure

Heart failure (HF) is a clinical syndrome associated with high mortality and morbidity rates. HF may increase the risk of AIS because of thromboembolic complications associated with reduced ejection fraction, progressive left ventricle dilatation, and cardiac remodeling.^{98,99} At the same time, HF is associated with well-known stroke risk factors, such as hypertension, AF, coronary artery disease, obesity, and

diabetes.¹⁰⁰ Although patients with HF were generally underrepresented in the large clinical trials on MT (eg, ESCAPE [The Endovascular Treatment for Small Core and Anterior Circulation Proximal Occlusion with Emphasis on Minimizing CT to Recanalization Times], REVASCAT [Randomized Trial of Revascularization with Solitaire FR Device versus Best Medical Therapy in the Treatment of Acute Stroke Due to Anterior Circulation Large Vessel Occlusion Presenting within Eight Hours of Symptom Onset]),^{30,33} recent studies have investigated the impact of HF in patients with AIS treated with MT (Table 5). Previous studies reported that the presence of HF was associated with unfavorable functional outcomes^{101–103} or higher in-hospital mortality after MT.^{101,103} In the study by Tan et al, the presence of HF was associated with a worse outcome even in patients who obtained successful reperfusion.¹⁰³ A possible explanation for these findings is that HF might contribute to a decrease of the global cerebral blood flow, collateral flow, and cerebral vasomotor reactivity and predisposes to hypoperfusion during MT. In addition, other concurrent factors in patients with HF, such as aging, endothelial dysfunction, and proinflammatory and prothrombotic states, may impact on the functional outcome.¹⁰¹ Conversely, Schnieder et al showed no significant impact of HF on mortality and functional outcome after MT.⁹⁹ However, this cohort included only patients with mild heart failure. Similarly, another cohort study found no association between HF with or without AF and in-hospital mortality in patients undergoing MT.¹⁰⁴ Therefore, data on mortality and functional outcomes in patients with AIS with HF undergoing MT remain controversial. Patients with and without HF demonstrated similar recanalization rates^{101–103} and similar rates of symptomatic intracerebral hemorrhage.^{99,101,102} For other safety concerns, Gentile et al focused on the anesthetic management of patients with HF undergoing MT. The authors showed that general anesthesia (GA) might be associated with worse clinical outcomes compared with patients with HF not undergoing GA, although no differences in terms of mortality rates were observed between the 2 groups.¹⁰⁸ The authors explained their findings in relation to the vasodilation induced by the GA and the consequent cerebral and organ hypoperfusion.¹⁰¹

Takotsubo cardiomyopathy (TCM) or stress-induced cardiomyopathy is an acute cardiac syndrome characterized by transient systolic and diastolic left ventricular dysfunction.¹⁰⁵ AIS in TCM is often associated with left ventricular thromboembolism, which is explained by blood stasis attributable to wall motion abnormalities and hypercoagulability from catecholamine surge.¹⁰⁵ However, cardioembolism in TCM can occur with or without the presence of detectable left ventricular thromboembolism. Y-Hassan et al described the case of a 67-year-old woman with midapical TCM complicated

by left ventricular thromboembolism, left anterior descending artery, and left middle cerebral artery (segment M2) thromboembolic occlusions.¹⁰⁶ The cerebral artery thrombotic occlusion was treated successfully with MT with complete resolution of the neurologic deficits. Cases of TCM developed after MT have also been described.^{107–109}

Summary of data (Figure 2):

- Patients with HF were generally underrepresented in the large clinical trials on MT;
- Data on mortality and functional outcomes in patients with AIS with HF undergoing MT remain controversial.

Aortic Dissection

Acute aortic syndromes are a group of diseases that affect the thoracic aorta. The most common acute aortic syndromes include acute aortic dissection (AoD), intramural aortic hematoma, penetrating aortic ulcer, and aortic rupture. Acute aortic syndromes can occur spontaneously or as a result of trauma, even in individuals without preexisting aortic disease. Neurologic complications occur in 17% to 40% of AoD cases, with AIS being the most common initial finding.¹¹⁰ Thrombolytic therapy is contraindicated in patients with AoD and AIS as the lytic may extend dissection into the pericardium, leading to cardiac tamponade, or increase the risk of fatal rupture of the ascending aorta or the aortic arch.^{111,112} Thus, MT remains the only recommended reperfusion treatment for patients with AoD and concurrent AIS attributable to LVO.³ To avoid propagation of the clot in case of AoD via transfemoral access, transradial access may be preferred. Among the main randomized trials of MT in AIS with LVO, Solitaire with the Intention for Thrombectomy as Primary Endovascular Treatment explicitly excluded patients with suspected AoD.³¹ Table 6 showed the key studies. In 2014, Igarashi et al reported 2 patients treated successfully with MT after aortic repair.¹¹³ Patients were treated by removing thrombi within the false lumen using a Fogarty catheter, and no neurologic complications were found postoperatively. In 2017, Reznik et al described 3 patients who underwent MT for AIS attributable to AoD.¹¹⁴ All patients had right M1 occlusions and experienced successful recanalization after MT and improvement of their neurologic status. The authors did not report that patients showed significant complications related to the procedure. Interestingly, the access point differed in these 3 cases (ie, transfemoral, transradial, and transbrachial). None of these patients were affected by acute type A AoD. Indeed, 2 had chronic AoD and underwent graft repair, whereas a third had acute type B AoD. Recently, 2 cases of MT in patients with AIS

Table 5. Heart Failure, Takotsubo Cardiomyopathy, and Mechanical Thrombectomy

Reference	Study type	Total No. of patients	Age, y	Patients treated with MT, n (%)	Patients with mRS score 0–2 at 90 d, n (%)	Patients with mRS score of 6 at 90 d, n (%)	Patients with sICH, n (%)	Patients with successful recanalization (mTICI 2b–3), n (%)	Summary of study findings
Schnieder et al 2019 ⁹⁹	Observational study on prospective single-center stroke registry	373 Patients with AIS, of whom 90 (24%) with HF	No HF: median, 73 (IQR: 63–83) HF: median, 77 (IQR: 70–84)*	373 (100.0)	No HF: 105 (48.2) HF: 32 (43.8)	No HF: 17 (7.4) HF: 9 (11)	No HF: 2 (1) HF: 3 (4.4)	No HF: 175 (76.4) HF: 63 (75.9)	No significant differences in study outcomes between patients with vs without HF
Gentile et al 2023 ¹⁰¹	Observational study on multicenter registry	8924 Patients with AIS, of whom 642 (7.2%) with HF	No HF: median, 73.8 (IQR: 62.9–80.8) HF: median, 77.1 (IQR: 68.2–82.8)*	8924 (100.0)	No HF: 3992 (48.2) HF: 234 (36.4)*	No HF: 1530 (18.5) HF: 197 (30.7)*	No HF: 648 (8.3) HF: 45 (7.6)	No HF: 6398 (78.1) HF: 488 (76.9)	Worse 90-d functional outcomes and higher mortality rates than patients with vs without HF
Siedler et al 2019 ¹⁰²	Observational study on single-center registry	1209 Patients with AIS, of whom 378 (31.3%) with HF	No HF: mean, 69.9 (±SD: 13.5) HF: mean, 76.1 (±SD: 12.1)*	No HF: 155 (18) HF: 88 (24)	No HF: 51% HF: 35%*	No HF: 9% HF: 20%*	No HF: 3% HF: 7%	No HF: 87% HF: 92%	Patients with HF had worse 90-d functional outcomes and higher mortality rates than patients with vs without HF (also in the matched cohort)
Tan et al 2021 ¹⁰³	Retrospective study on 6 international stroke registries	440 Patients with AIS, of whom 101 (23.0%) with HF	No HF: mean, 67.0 (±SD: 13.2) HF: mean, 63.5 (±SD: 13.8)*	440 (100.0)	No HF: 161 (48.1) HF: 32 (32.0)*	No HF: 19 (5.7) HF: 21 (21.0)*	No HF: 35 (10.0) HF: 15 (15.0)	No HF: 289 (85.3) HF: 87 (87.0)	Worse 90-d functional outcomes and higher mortality rates than patients with vs without HF
Pana et al 2021 ¹⁰⁴	Observational study on publicly available national stroke registry	33 173 Patients with AIS undergoing EVT, of whom 2376 (7.2%) with HF, 4390 (13.2%) with HF and AF, and 10 826 (32.6%) with AF	No HF/AF: median, 61 (IQR: 51–72) AF: median, 76 (IQR: 67–82) HF: median, 67 (IQR: 56–77) HF+AF: median, 77 (IQR: 66–83)*	33 173 (100.0)	NA	NA	NA	No HF/AF: 3939 (25.3) AF: 3093 (28.6) HF: 596 (25.1) HF+AF: 1268 (28.9)	No difference in reperfusion rates in patients with vs without HF
Y-Hassan et al 2019 ¹⁰⁶	Case report	1	67	1 (100.0)	1 (100.0)	0 (0.0)	0 (0.0)	1 (100.0)	MT with TCM is effective and safe
Riva et al 2021 ¹⁰⁷	Case report	1	78	1 (100.0)	1 (100.0)	0 (0.0)	0 (0.0)	1 (100.0)	MT with TCM is effective and safe
Yamasaki et al 2021 ¹⁰⁸	Case report	1	73	1 (100.0)	1 (100.0)	0 (0.0)	0 (0.0)	1 (100.0)	MT with TCM is effective and safe
Nagendra et al 2023 ¹⁰⁹	Case report	1	67	1 (100.0)	1 (100.0)	0 (0.0)	0 (0.0)	1 (100.0)	MT with TCM is effective and safe

AF indicates atrial fibrillation; AIS, acute ischemic stroke; HF, heart failure; EVT, endovascular treatment; IQR, interquartile range; mRS, modified Rankin Scale; MT, mechanical thrombectomy; mTICI, modified Treatment in Cerebral Ischemia; NA, not available; sICH, symptomatic intracranial hemorrhage; TCM, Takotsubo cardiomyopathy.

*Significantly different at $P < 0.05$.

Table 6. Aortic Dissection and MT

Reference	Study type	Total No. of patients	Age, y	Patients treated with MT, n (%)	Patients with mRS score 0–2 at 90 d, n (%)	Patients with mRS score of 6 at 90 d, n (%)	Patients with sICH, n (%)	Patients with successful recanalization (mTICI 2b–3), n (%)	Summary of study findings
Igarashi et al 2014 ¹¹³	Case report	2	57 and 87	2 (100)	1 (50)	1 (50)	0 (0)	2 (100)	MT may be considered in cases of aortic dissection and LVO
Reznik et al 2017 ¹¹⁴	Case report	3	NA	3 (100)	3 (100)	0 (0)	0 (0)	3 (100)	MT may be safe and effective in patients with aortic dissection with carotid occlusion
Jeong et al 2023 ¹¹⁵	Case report	2	81 and 76	2 (100)	1 (50)	0 (0)	0 (0)	NA	MT may be safe and effective in patients with aortic dissection with carotid occlusion
Lin et al 2019 ¹¹⁶	Case report	1	45	1 (100)	1 (100)	0 (0)	0 (0)	1 (100)	MT may be safe and effective in patients with aortic dissection with carotid occlusion

LVO indicates large-vessel occlusion; mRS, modified Rankin Scale; MT, mechanical thrombectomy; mTICI, modified Treatment in Cerebral Ischemia; NA, not available; and sICH, symptomatic intracranial hemorrhage.

and hidden AoD have been reported.¹¹⁵ One patient with an internal carotid artery occlusion caused by the dissection flap was treated with a stent deployed from the distal portion of the common carotid artery to the proximal internal carotid artery. The second one had occlusion of the superior branch of the left middle cerebral artery, and suction thrombectomy was performed with a first-pass effect that completely restored the flow. Although difficult, both procedures used a transfemoral approach. The main challenge in performing MT for AIS before corrective surgery for acute AoD is to establish the appropriate approach site for catheterization. Catheterizing patients with AoD can be challenging because of technical difficulties and potential risks, such as extending the dissection, displacing thrombotic material, and causing total perforation of the aorta. On the basis of the location and acuity of the AoD, as well as the location of the target vessel, the access point must be decided on a case-by-case basis. A transradial or carotid approach should be considered in cases with acute AoD and anterior circulation occlusion. The carotid approach can be performed via ultrasound-guided common carotid artery puncture or open exploration. Lin et al described a patient with occlusion of the right common carotid artery up to the internal carotid artery attributable to type A AoD that

was treated successfully by exposing the right common carotid artery and directly puncturing the artery (the open exploration approach).¹¹⁶

Summary of data (Figure 2):

- The use of MT in patients with acute AoD and concurrent AIS attributable to LVO appears feasible despite limited literature available.

Left Ventricular Assist Device and Total Artificial Heart

Left ventricular assist devices (LVADs) and total artificial hearts are mechanical circulatory support devices that provide either a bridge to transplantation in patients with advanced heart failure or destination therapy in patients ineligible for transplantation.^{117–119} Despite the requirement for full effective anticoagulation (eventually in addition to antiplatelet agents), AIS remains a common adverse event in patients with LVAD and total artificial heart.^{117,118} Because of the concomitant anticoagulation therapy and recent thoracic surgery, this specific population is typically excluded from treatment with IVT. Therefore, the use of MT in patients with LVAD and total artificial heart may represent a valid option to potentially

reverse the clinical course and maintain eligibility for cardiac transplantation in case of AIS attributable to LVO^{117,118} (Table S1). Previous case reports, case series, and small observational studies^{117–125} documented that patients with LVADs were more frequently treated with MT compared with patients without LVADs, whereas the rate of successful recanalization was similar in both groups. Recently, Ibeh et al compared postthrombectomy outcomes in patients with and without LVAD support, and they additionally performed subgroup analyses among patients with LVADs with AIS in the postoperative setting and in the setting of preexisting device.¹²⁶ The authors showed that among those receiving MT, mortality was higher in the population with LVAD (31.0% versus 14.1%; $P=0.009$), although this was largely driven by the postoperative LVAD subgroup. In multivariable analysis, only postoperative patients with LVADs experienced greater odds of in-hospital death after MT; patients with preexisting LVADs demonstrated no difference in post-MT mortality or in odds of discharge home after MT. These findings suggest the lack of an association between preexisting LVAD and worse outcomes after MT, supporting the safety and efficacy of MT in the LVAD population. Nevertheless, one of the major challenges in this group remains to be avoiding hemorrhagic complications during MT.¹¹⁸

Summary of data (Figure 2):

- MT in the LVAD population poses major challenges, including the risk of hemorrhagic complications related to the procedure.

Congenital Heart Disease

The prevalence of congenital heart disease (CHD) worldwide is 9 per 1000 newborns, and because of medical advances, >90% of patients survive into adulthood.^{127,128} CHD represents a strong risk factor for ischemic stroke because of several factors, such as abnormal flow patterns, chamber dilatation, and dysrhythmias, with a risk ≈ 11 times higher than the general population.¹²⁸ Data on MT in AIS attributable to CHD mainly refer to pediatric cases (Table S2). Therefore, reports are sparse because of the low frequency and level of evidence in patients aged 1 to 18 years. Lu et al described a 38-year-old man with a history of anomalous pulmonary venous return corrected at 7 months of age and newly identified AF, treated with IVT and MT for a left middle cerebral artery branch occlusion with successful recanalization.¹²⁹ The patient subsequently made a complete recovery with regard to his language, with subtle deficits of fine finger movements and pronator drift on the right within 1 month of his event. Souto Silva et al described a 4-year-old boy with AIS, resulting from a left middle cerebral artery occlusion, successfully treated with IVT and

MT.¹³⁰ At the time of discharge, 8 days after the vascular event, he completely recovered from the aphasia and had mild right hemiparesis, but he was already capable of independent gait, with a Pediatric National Institutes of Health Stroke Scale score of 2. In another case, a 3-year-old boy with complex CHD underwent IVT and MT for complete 2-vessel occlusion of both the basilar artery and left middle cerebral artery, resulting in successful recanalization.¹³¹ The boy was discharged to a pediatric neurorehabilitation clinic. Short time outcome after 4 months was favorable, with a right-sided hemiparesis mainly of the upper limb. Nasr et al reported a case involving a 2-year-old girl with a prenatal diagnosis of single ventricle who underwent 2 palliative cardiac surgeries. She had a successful MT 9 hours after the stroke onset. Notably, the authors suggest that the cardioembolic origin of the stroke attributable to CHD, in the absence of underlying vasculopathy, potentially increases the odds of successful recanalization.¹³² The cases mentioned highlight successful interventions in pediatric patients with CHD-related ischemic stroke, underscoring the potential for effective treatment in such cases and the need for further research and evidence. However, interventions in pediatric patients need technical modifications, because of several limitations. First, a critical limiting factor in determining the feasibility of MT is the smaller size of the femoral artery, which increase the risk of severe vasospasm with vascular sheaths. The pediatric population aged ≤ 2 years has an estimated femoral artery diameter of < 4 mm. As the smallest sheath available, which allows the use of a microcatheter to deploy a stent retriever, is a 4F radial sheath with an outer diameter of 1.96 mm, the risk of vasospasm in a 4-mm femoral artery can be high. This also means that even when bigger sheaths can be used, it is mandatory to sacrifice the proximal stability of a guide catheter, and to advance the aspiration catheter directly over the guidewire. Second, when using the aspiration technique, blood loss during the aspiration process should be kept to a minimum, because the total blood volume of a pediatric patient is reduced. Third, the device and technique should be carefully selected. Indeed, arteriopathy may be present in the context of CHD, particularly in cardiovascular-related congenital syndromes, therefore potentially increasing the risk of arterial rupture or dissection. Finally, infants and young children are more susceptible to complications associated with contrast administration and radiation exposure.¹³³ Therefore, timing of treatment and duration should be kept to the minimum, further increasing the challenge of stroke treatment in people with pediatric and congenital heart disease.

Summary of data (Figure 2):

- Data on MT in AIS attributable to CHD mainly refer to pediatric cases;

- The cases mentioned highlight successful interventions in pediatric patients with CHD-related ischemic stroke;
- Interventions in pediatric patients need technical modifications, because of several limitations.

Cardiac Tumors

Cardiac tumors (CATs) can be grouped on the basis of their origin as either primary or secondary (metastatic). Primary CATs are globally rare, with a reported frequency of 1:100 000 people for primary CATs, whereas autopsy studies showed a higher prevalence for secondary tumors (1:100).¹³⁴ Among primary CATs, 10% are malignant, whereas 90% are benign. Myxomas, the most prevalent benign tumors, account for 80% of primary CATs and are commonly found in the left atrium¹³⁵ predominantly affecting women aged between 30 and 60 years. Ischemic stroke/transient ischemic attack represents the most common neurologic complication of CATs and can occur in up to 40% of patients with myxoma.¹³⁶ Cerebral infarctions are thought to be secondary to embolization of CAT particles or thrombotic material covering the surface of tumor cells.¹³⁷ Moreover, cerebral ischemic events may also be related to episodes of AF caused by the electric interference of the tumor on the heart conduction system, typically in the context of solid myxomas.^{137,138}

Available case studies suggest that MT (Table S3), either alone or after IVT (bridging therapy), can be safely achieved in patient LVO related to CAT embolization.^{139–146} Indeed, successful recanalization was achieved in most patients^{139,140,142–144,146} without hemorrhagic transformation in all but 1 case.¹⁴⁴ However, treatment outcome may vary depending on differences in clot consistency because of heterogeneous tumor composition. For example, solid myxomas may present with dense emboli composed of neoplastic spindle cells intricately intertwined with platelets and fibrin, potentially making the clot challenging to remove and increasing the likelihood of incomplete recanalization.¹⁴⁰ On the contrary, paucicellular mesenchymal tumors that contain a copious myxoid matrix with sporadic spindle cells might facilitate easier removal of the emboli via MT.¹⁴⁰ Accordingly, some authors suggest the use of histologic examination of the clot for diagnosis as its composition may predict differences in treatment outcome.¹⁴⁷

Summary of data (Figure 2):

- MT in patients with CATs appears to be associated with acceptable recanalization rates;
- Treatment outcome of MT in patients with CATs may vary depending on differences in clot consistency because of heterogeneous tumor composition.

Cardiac Surgery

Stroke after cardiac surgery has a prevalence between 1% and 10% and is associated with high mortality and morbidity.^{56,147–150} The main predictors are increasing age, previous cardiac and cerebrovascular disease, diabetes, emergent surgical status, prolonged aortic cross-clamp time, and prolonged cardiac bypass time.^{147–149} The diagnosis of stroke in these patients may occur in the stable postoperative period or waking up from GA.¹⁴⁸ In the latter context, the neurologic assessment may be challenging because of the prolonged interval between the time of last known well and the detection of neurologic deficit, analogous to the “wake-up” stroke.¹⁵⁰ Unfortunately, IVT is usually contraindicated in stroke following cardiac surgery because of recent surgery and significant risk of surgical site bleeding, whereas MT has emerged as an effective and safe intervention.¹⁵⁰ To date, no prospective study has investigated the outcomes of MT in these patients, and data available are mainly based on retrospective cohort analyses, case series, and case reports (Table S4). The largest retrospective series to date by Gupta et al, Sheriff et al, and Wilkinson et al (with 7, 6, and 6 cases, respectively, undergoing MT for postcardiac stroke) showed that MT may be associated with a better outcome compared with medical management, especially in the case of early reperfusion and favorable imaging characteristics.^{56,148,151} In the retrospective series of Wilkinson et al, data on the device used are available for only 6 patients of 15. Interestingly, 4 of them were treated with Solitaire stent retriever in combination with aspiration. Other reports (8 patients totally) showed the same trend,^{73,152–155} with most patients achieving a moderate to full recovery. Kashani et al described the outcome of 14 patients treated with MT for postoperative ischemic stroke and LVO with various stent-like devices.¹⁵⁰

Few case reports reported the use of intra-arterial thrombolysis after cardiac surgery.^{156–158}

CABG is required in patients who are not suitable for PCI, and it is preferred in cases of significant multivessel coronary artery disease. The development of postoperative cerebrovascular stroke is linked to prolonged hospitalization with high costs and increased hospital mortality. Laimoud et al documented that 7.5% of patients developed postoperative stroke after CABG, with MT performed in only 2 cases.¹⁴⁹ Madeira et al described the case of a 72-year-old woman who developed a left posterior cerebral artery syndrome with occlusion of the P1 segment 1 day after CABG.⁷³ MT was performed 3 hours after the symptom onset, with complete recanalization and with almost complete clinical recovery at discharge.

Finally, Gupta et al described the outcomes of 5 patients treated with MT after cardiac surgery for

heart valve disease.⁵⁶ A successful recanalization was achieved in 3 of 5 patients, whereas 2 of them regained functional independence (mRS score, ≤ 2) 3 months after the intervention.⁵⁶ In conclusion, large prospective cohort studies are needed to better investigate the outcome and safety of MT in patients with stroke after cardiac surgery. A more homogeneous and systematic identification of stroke in this population could improve access to appropriate consideration of MT.

Summary of data (Figure 2):

- Data available are mainly based on retrospective cohort analyses, case series, and case reports;
- Data showed that MT may be associated with a better outcome compared with medical management, especially in the case of early reperfusion and favorable imaging characteristics.

DISCUSSION

Herein, we provided an extensive overview of the currently available data on the clinical outcomes and safety of MT in patients with AIS attributable to cardiac diseases. To our knowledge, this is the first review in the literature that explores the outcomes and safety of MT for AIS in the context of cardiological diseases, including AF, PCI, CABG, TAVI, IE, HF, TCM, AoD, LVAD, CHD, and CATs.

Summary of Findings

Our review showed that MT is generally effective and safe for the treatment of LVO in AIS for patients with AF and HF, and among patients who presented with LVO AIS in the context of PCI or CABG. This is despite the fact the management of these patients is further complicated by the recent use of heparinization or oral anticoagulants that precludes the use of intravenous thrombolytics. Indeed, we also illustrated that MT is feasible in patients with IE and CATs, where the use of thrombolytic agents is generally accepted as contraindicated, making MT the only option for intervention in selected cases. Data available suggested that MT in patients with AIS after cardiac surgery or TAVI can be successful. There are limited data on patients with CHD undergoing MT for AIS attributable to LVO. Data on MT in AIS attributable to CHD mainly refer to pediatric cases and pose access-, device-, and technique-related challenges. Furthermore, our review showed that MT in the LVAD population with AIS and LVO has major challenges, including the risk hemorrhagic complications related to the procedure. Finally, the use of MT in patients with acute AoD and concurrent AIS attributable to LVO appears feasible despite limited literature available.

Interpretation of Findings

Our review highlights the importance of an early and prompt recognition of neurologic symptoms and signs in patients with a cardiological condition by all cardiac care providers. Despite the limited literature available in some circumstances, MT is generally feasible in cardiological patients who experience an AIS attributable to LVO. Therefore, efforts should be made to allow an early detection of clinical abnormalities and to perform urgent neuroimaging and referral to neurointerventional care providers in case of suspected AIS without delay. Indeed, patients who have an AIS attributable to LVO in the context of postcardiac surgery or TAVI are less likely to be diagnosed promptly because of the duration of the surgery and long emergence from GA, which does not allow for accurate neurologic evaluation. A preestablished multidisciplinary procedure adapted to each institution would facilitate the appropriate management and the identification of which patients would benefit most from MT.^{159,160} Moreover, priority setting exercises consisting of 3 phases (pre-prioritization, prioritization, and postprioritization) might help stroke physicians and cardiologists to develop de novo guidelines for the management and treatment of these patients.¹⁶¹

Strengths and Limitations

The strength of our review relies on the explicit, transparent, peer-reviewed search strategy.

Moreover, our review includes a vast range of different cardiological conditions. There are limitations to our scoping review. Our review relied on different types of studies (eg, reviews, case reports, and observational studies) that did not have sometimes all the variables considered for the review. We found limited data available on the MT procedure strategy used to treat LVO AIS attributable to cardiac diseases. Most of the studies included in this review were observational, case series, or case reports and therefore the choice of the thrombectomy procedures was left to the discretion and experience of the operator and was not dictated by a specific protocol. As stent retriever techniques were used predominantly in randomized clinical trials, questions remain on the safety and efficacy of aspiration thrombectomy techniques as a first-line therapy and whether there is an MT technique associated with better outcome depending on the cardiac disease associated with the stroke and its clot composition. Finally, as a scoping review, our main purpose was to identify and analyze knowledge gaps on the use of MT in patients with cardiological conditions. However, we recognized that we did not encompass all the cardiological conditions, and we recognized this as a limitation.

Implications for Practice and Future Research

Further studies are needed in these patients who are commonly excluded from “standard” thrombectomy randomized controlled trials. Given the rarity of some of these conditions, large randomized controlled trials may not be possible, whereas the design of multicenter observational studies and registries might help to better understand treatment for these patients. Stroke physicians and cardiologists should communicate closely to further develop the tools, resources, and treatments that would be useful for improving the detection of AIS and reducing the time to treatment in such patients. Creation of guidance posters incorporating the stroke recognition tool “BESFAST” (balance, eyes, face, arm, speech, time) led to substantial improvement in cardiac staff confidence and knowledge of stroke care.¹⁶² This might help in the future to drive innovations in the identified areas of greatest need.

CONCLUSIONS

In conclusion, available data outline the feasibility of MT in patients with AIS attributable to LVO secondary to cardiac diseases.

ARTICLE INFORMATION

Affiliations

Department of Stroke and Neuroscience, Charing Cross Hospital, Imperial College London NHS Healthcare Trust, London, United Kingdom (L.D., S.B.); Department of Brain Sciences, Imperial College London, London, United Kingdom (L.D., E.K., S.B.); Department of Neurology, Martin-Luther-University Halle-Wittenberg, Halle (Saale), Germany (S.A., L.B., M.O.); Stroke Unit and Clinical Neurology, Udine University Hospital, Udine, Italy (G.M., F.K., G.L.G.); Department of Biotechnological and Applied Clinical Sciences, University of L'Aquila, L'Aquila, Italy (R.O., M.F., S.S.); Interventional Neuroradiology, Vall d'Hebron University Hospital, Barcelona, Catalunya, Spain (F.D.); Neurology and Stroke Unit, Ospedale Infermi, Rimini, Italy (V.M.); Neurology and Stroke Unit, Department of Neuroscience, Bufalini Hospital, Azienda Unità Sanitaria Locale Romagna, Cesena, Italy (M.R.); Neuroradiology, Department of Imaging, Charing Cross Hospital, Imperial College London, NHS Healthcare Trust, London, United Kingdom (K.L.); Philip Kistler Research Center, Department of Neurology, Massachusetts General Hospital and Harvard Medical School, Boston, MA (F.B.); Clinical Neurology, Udine University Hospital and Dipartimento di Area Medica, University of Udine, Udine, Italy (M.V.); and Department of Neurology, Radiology, Boston Medical Center, Boston, MA (T.N.N.).

Sources of Funding

Drs Abu-Rumeileh and Barba received research support from the Medical Faculty of Martin-Luther-University Halle-Wittenberg (Junior Clinician Scientist Programm No. JCS24/02).

Disclosures

Dr Banerjee is a key opinion leader for RAPIDAI. The remaining authors have no disclosures to report.

Supplemental Material

Data S1
Tables S1–S4

REFERENCES

- Shah R, Wilkins E, Nichols M, Kelly P, El-Sadi F, Wright FL, Townsend N. Epidemiology report: trends in sex-specific cerebrovascular disease mortality in Europe based on WHO mortality data. *Eur Heart J*. 2019;40:755–764. doi: [10.1093/eurheartj/ehy378](https://doi.org/10.1093/eurheartj/ehy378)
- Adams HP Jr, Bendixen BH, Kappelle LJ, Biller J, Love BB, Gordon DL, Marsh EE 3rd. Classification of subtype of acute ischemic stroke. Definitions for use in a multicenter clinical trial. TOAST. Trial of Org 10172 in Acute Stroke Treatment. *Stroke*. 1993;24:35–41. doi: [10.1161/01.STR.24.1.35](https://doi.org/10.1161/01.STR.24.1.35)
- Powers WJ, Rabinstein AA, Ackerson T, Adeoye OM, Bambakidis NC, Becker K, Biller J, Brown M, Demaerschalk BM, Hoh B, et al. Guidelines for the early management of patients with acute ischemic stroke: 2019 update to the 2018 guidelines for the early Management of Acute Ischemic Stroke: a guideline for healthcare professionals from the American Heart Association/American Stroke Association. *Stroke*. 2019;50:50. doi: [10.1161/STR.0000000000000211](https://doi.org/10.1161/STR.0000000000000211)
- Tricco AC, Lillie E, Zarin W, O'Brien KK, Colquhoun H, Levac D, Moher D, Peters MDJ, Horsley T, Weeks L, et al. PRISMA extension for scoping reviews (PRISMA-ScR): checklist and explanation. *Ann Intern Med*. 2018;169:467–473. doi: [10.7326/M18-0850](https://doi.org/10.7326/M18-0850)
- Healey JS, Connolly SJ, Gold MR, Israel CW, Van Gelder IC, Capucci A, Lau CP, Fain E, Yang S, Bailleul C, et al. Subclinical atrial fibrillation and the risk of stroke. *N Engl J Med*. 2012;366:120–129. doi: [10.1056/NEJMoa1105575](https://doi.org/10.1056/NEJMoa1105575)
- January CT, Wann LS, Calkins H, Chen LY, Cigarroa JE, Cleveland JC, Ellinor PT, Ezekowitz MD, Field ME, Furie KL, et al. AHA/ACC/HRS focused update of the 2014 AHA/ACC/HRS guideline for the Management of Patients with Atrial Fibrillation: a report of the American College of Cardiology/American Heart Association task force on clinical practice guidelines and the Heart Rhythm Society in collaboration with the Society of Thoracic Surgeons. *Circulation*. 2019;2019:140. doi: [10.1161/CIR.0000000000000665](https://doi.org/10.1161/CIR.0000000000000665)
- Lip GYH, Hunter TD, Quiroz ME, Ziegler PD, Turakhia MP. Atrial fibrillation diagnosis timing, ambulatory ECG monitoring utilization, and risk of recurrent stroke. *Circ Cardiovasc Qual Outcomes*. 2017;10:10. doi: [10.1161/CIRCOUTCOMES.116.002864](https://doi.org/10.1161/CIRCOUTCOMES.116.002864)
- Akbik F, Alawieh A, Cawley CM, Howard BM, Tong FC, Nahab F, Saad H, Dimisko L, Mustroph C, Samuels OB, et al. Differential effect of mechanical thrombectomy and intravenous thrombolysis in atrial fibrillation associated stroke. *J Neurointerv Surg*. 2021;13:883–888. doi: [10.1136/neurintsurg-2020-016720](https://doi.org/10.1136/neurintsurg-2020-016720)
- Huang K, Zha M, Gao J, Du J, Liu R, Liu X. Increased intracranial hemorrhage of mechanical thrombectomy in acute ischemic stroke patients with atrial fibrillation. *J Thromb Thrombolysis*. 2021;51:536–544. doi: [10.1007/s11239-020-02269-3](https://doi.org/10.1007/s11239-020-02269-3)
- Lasek-Bal A, Żak A, Binek Ł, Student S, Tomalski W, Krzan A, Puz P, Uchwat U. The relevance of atrial fibrillation to the safety and efficacy of mechanical thrombectomy in stroke patients. *Pol Arch Intern Med*. 2021;132. doi: [10.20452/pamw.16148](https://doi.org/10.20452/pamw.16148)
- Leker RR, Farraj A, Sacagiu T, Honig A, ElHasan HA, Gomori JM, Cohen JE. Atrial fibrillation treatment adequacy and outcome after endovascular thrombectomy: adequacy of AF treatment and outcome after EVT. *J Stroke Cerebrovasc Dis*. 2020;29:29. doi: [10.1016/j.jstrokecerebrovasdis.2020.104948](https://doi.org/10.1016/j.jstrokecerebrovasdis.2020.104948)
- Lin C-J, Luo C-B, Chien C, Chang F-C, Lin C-J, Lee I-H, Hsu L-C, Chung C-P, Liu H-Y, Chi N-F, et al. Better endovascular mechanical thrombectomy outcome in atrial fibrillation patients with acute ischemic stroke: a single-center experience. *J Chin Med Assoc*. 2020;83:756–760. doi: [10.1097/JCMA.0000000000000377](https://doi.org/10.1097/JCMA.0000000000000377)
- Fu J, Cappelen-Smith C, Edwards L, Cheung A, Mannin N, Wenderoth J, Parsons M, Cordato D. Comparison of functional outcomes after endovascular thrombectomy in patients with and without atrial fibrillation. *Vessel Plus*. 2021;5:33. doi: [10.20517/2574-1209.2021.36](https://doi.org/10.20517/2574-1209.2021.36)
- Ždraljević M, Pekmezović T, Stanačević P, Vukašinović I, Berisavac I, Ercegović M, Vitošević F, Nestorović D, Cvetić V, Padjen V, et al. Atrial fibrillation is associated with poor long-term outcome after mechanical thrombectomy for anterior large vessel occlusion stroke. *J Stroke Cerebrovasc Dis*. 2022;31:106755. doi: [10.1016/j.jstrokecerebrovasdis.2022.106755](https://doi.org/10.1016/j.jstrokecerebrovasdis.2022.106755)
- Heshmatollah A, Fransen P, Berkhemer O, Beumer D, van der Lugt A, Majoie C, Oostenbrugge R, van Zwam W, Koudstaal P, Roos Y, et al. Endovascular thrombectomy in patients with acute ischaemic stroke and atrial fibrillation: a MR CLEAN subgroup analysis. *EuroIntervention*. 2017;13:996–1002. doi: [10.4244/EUJ-D-16-00905](https://doi.org/10.4244/EUJ-D-16-00905)
- Mujanovic A, Kurmann CC, Dobrocky T, Olivé-Gadea M, Maegerlein C, Pierot L, Mendes Pereira V, Costalat V, Psychogios M, Michel P,

- et al. Bridging intravenous thrombolysis in patients with atrial fibrillation. *Front Neurol*. 2022;13:13. doi: [10.3389/fneur.2022.945338](https://doi.org/10.3389/fneur.2022.945338)
17. Tong X, Li S, Liu W, Ren Z, Liu R, Jia B, Zhang X, Huo X, Luo G, Ma G, et al. Endovascular treatment for acute ischemic stroke in patients with versus without atrial fibrillation: a matched-control study. *BMC Neurol*. 2021;21:377. doi: [10.1186/s12883-021-02386-3](https://doi.org/10.1186/s12883-021-02386-3)
 18. Alobaida M, Harrison SL, Lane DA, Underhill P, Hill A, Lip GYH. Outcomes in patients with ischaemic stroke undergoing endovascular thrombectomy: impact of atrial fibrillation. *J Stroke Cerebrovasc Dis*. 2023;32:106917. doi: [10.1016/j.jstrokecerebrovasdis.2022.106917](https://doi.org/10.1016/j.jstrokecerebrovasdis.2022.106917)
 19. Munir MB, Alqahtani F, Beltagy A, Tarabishy A, Alkhouli M. Comparative outcomes of mechanical thrombectomy for acute ischemic stroke in patients with and without atrial fibrillation. *J Vasc Interv Radiol*. 2017;28:1604–1605. doi: [10.1016/j.jvir.2017.06.024](https://doi.org/10.1016/j.jvir.2017.06.024)
 20. Loo JH, Leow AS, Jing M, Sia C-H, Chan BP, Seet RC, Teoh H-L, Meyer L, Fiehler J, Papanagiotou P, et al. Impact of atrial fibrillation on the treatment effect of bridging thrombolysis in ischemic stroke patients undergoing endovascular thrombectomy: a multicenter international cohort study. *J Neurointerv Surg*. 2023;15:1274–1279. doi: [10.1136/jnis-2022-019590](https://doi.org/10.1136/jnis-2022-019590)
 21. Yang J, Wu Y, Gao X, Shang Q, Xu Y, Han Q, Li J, Chen C, Bivard A, Parsons MW, et al. Poor collateral flow with severe hypoperfusion explains worse outcome in acute stroke patients with atrial fibrillation. *Int J Stroke*. 2023;18:689–696. doi: [10.1177/17474930221138707](https://doi.org/10.1177/17474930221138707)
 22. Pillai P, Bush SJ, Kusuma Y, Churilov L, Dowling RJ, Luu VD, Davis SM, Mitchell PJ, Yan B. Atrial fibrillation is associated with higher first pass effect following thrombectomy for large vessel occlusion. *J Neurointerv Surg*. 2023;1–5. doi: [10.1136/jnis-2023-020512](https://doi.org/10.1136/jnis-2023-020512)
 23. Wu W, Pitton Rissardo J, Nguyen TN, Mofatteh M, Wei H, Liebeskind DS, Yang S, Li W, Pan W, Zhou S, et al. Effect of atrial fibrillation on outcomes in patients with anterior circulation occlusion stroke receiving endovascular therapy. *Front Aging Neurosci*. 2023;15:1160265. doi: [10.3389/fnagi.2023.1160265](https://doi.org/10.3389/fnagi.2023.1160265)
 24. Nogueira RG, Gupta R, Jovin TG, Levy EI, Liebeskind DS, Zaidat OO, Rai A, Hirsch JA, Hsu DP, Rymer MM, et al. Predictors and clinical relevance of hemorrhagic transformation after endovascular therapy for anterior circulation large vessel occlusion strokes: a multicenter retrospective analysis of 1122 patients. *J Neurointerv Surg*. 2015;7:16–21. doi: [10.1136/neurintsurg-2013-010743](https://doi.org/10.1136/neurintsurg-2013-010743)
 25. Churojana A, Mongkolratnan A, Sangpetngam B, Aurboonyawat T, Chankaew E, Withayasuk P, Songsaeng D, Cognard C. A comparison of mechanical thrombectomy for large vessel occlusion in acute ischemic stroke between patients with and without atrial fibrillation. *Siriraj Med J*. 2018;70:278–283.
 26. Sur NB, Saini V, Torres LF, Atchaneeyasakul K, Malik AM, Yavagal DR, Chaturvedi S. The proportion of preventable thrombectomy procedures with improved atrial fibrillation stroke prevention. *J Stroke Cerebrovasc Dis*. 2021;30:105599. doi: [10.1016/j.jstrokecerebrovasdis.2021.105599](https://doi.org/10.1016/j.jstrokecerebrovasdis.2021.105599)
 27. Wang C, Hang Y, Cao Y, Zhao L, Jiao J, Li M, Xu X, Jiang L, Liu S, Shi H, et al. Association between prior anticoagulation and thrombus composition in mechanical thrombectomy patients with atrial fibrillation. *J Stroke Cerebrovasc Dis*. 2022;31:106347. doi: [10.1016/j.jstrokecerebrovasdis.2022.106347](https://doi.org/10.1016/j.jstrokecerebrovasdis.2022.106347)
 28. Pan X, Liu G, Li Y, Wang B, Chong Y, Jiang C, Ci Y. Is atrial fibrillation a prognostic predictor for patients with acute ischemic stroke treated with thrombectomy? 2016. www.ijcem.com/.
 29. Berkhemer OA, Fransen PSS, Beumer D, van den Berg LA, Lingsma HF, Yoo AJ, Schonewille WJ, Vos JA, Nederkoorn PJ, Wermer MJH, et al. A randomized trial of Intraarterial treatment for acute ischemic stroke. *N Engl J Med*. 2015;372:11–20. doi: [10.1056/NEJMoa1411587](https://doi.org/10.1056/NEJMoa1411587)
 30. Goyal M, Demchuk AM, Menon BK, Eesa M, Rempel JL, Thornton J, Roy D, Jovin TG, Willinsky RA, Sapkota BL, et al. Randomized assessment of rapid endovascular treatment of ischemic stroke. *N Engl J Med*. 2015;372:1019–1030. doi: [10.1056/NEJMoa1414905](https://doi.org/10.1056/NEJMoa1414905)
 31. Saver JL, Goyal M, Bonafe A, Diener H-C, Levy EI, Pereira VM, Albers GW, Cognard C, Cohen DJ, Hacke W, et al. Stent-retriever thrombectomy after intravenous t-PA vs. t-PA alone in stroke. *N Engl J Med*. 2015;372:2285–2295. doi: [10.1056/NEJMoa1415061](https://doi.org/10.1056/NEJMoa1415061)
 32. Campbell BCV, Mitchell PJ, Kleinig TJ, Dewey HM, Churilov L, Yassi N, Yan B, Dowling RJ, Parsons MW, Oxley TJ, et al. Endovascular therapy for ischemic stroke with perfusion-imaging selection. *N Engl J Med*. 2015;372:1009–1018. doi: [10.1056/NEJMoa1414792](https://doi.org/10.1056/NEJMoa1414792)
 33. Jovin TG, Chamorro A, Cobo E, de Miquel MA, Molina CA, Rovira A, San Román L, Serena J, Abilleira S, Ribó M, et al. Thrombectomy within 8 hours after symptom onset in ischemic stroke. *N Engl J Med*. 2015;372:2296–2306. doi: [10.1056/NEJMoa1503780](https://doi.org/10.1056/NEJMoa1503780)
 34. Muir KW, Ford GA, Messow C-M, Ford I, Murray A, Clifton A, Brown MM, Madigan J, Lenthall R, Robertson F, et al. Endovascular therapy for acute ischaemic stroke: the pragmatic ischaemic stroke thrombectomy evaluation (PISTE) randomised, controlled trial. *J Neuro Neurosurg Psychiatry*. 2017;88:38–44. doi: [10.1136/jnnp-2016-314117](https://doi.org/10.1136/jnnp-2016-314117)
 35. Smaal J, de Ridder I, Heshmatollah A, van Zwam W, Dippel D, Majoie C, Brown S, Goyal M, Campbell B, Muir K, et al. Effect of atrial fibrillation on endovascular thrombectomy for acute ischemic stroke. A meta-analysis of individual patient data from six randomised trials: results from the HERMES collaboration. *Eur Stroke J*. 2020;5:245–251. doi: [10.1177/2396987320923447](https://doi.org/10.1177/2396987320923447)
 36. Zheng W, Tang Y, Lin H, Huang H, Lei H, Lin H, Huang Y, Lin X, Liu N, Du H. Atrial fibrillation and clinical outcomes of endovascular thrombectomy for acute ischemic stroke: a meta-analysis of adjusted effect estimates. *J Am Heart Assoc*. 2023;12:12. doi: [10.1161/JAHA.123.031733](https://doi.org/10.1161/JAHA.123.031733)
 37. Kobeissi H, Ghozy S, Seymour T, Gupta R, Bilgin C, Kadirvel R, Rabinstein AA, Kallmes DF. Outcomes of patients with atrial fibrillation following thrombectomy for stroke. *JAMA Netw Open*. 2023;6:e2249993. doi: [10.1001/jamanetworkopen.2022.49993](https://doi.org/10.1001/jamanetworkopen.2022.49993)
 38. D'Anna L, Barba L, Foschi M, Romoli M, Abu-Rumeileh S, Dolkar T, Vittay O, Dixon L, Bentley P, Brown Z, et al. Safety and outcomes of different endovascular treatment techniques for anterior circulation ischaemic stroke in the elderly: data from the Imperial college thrombectomy registry. *J Neurol*. 2023;271:1366–1375. doi: [10.1007/s00415-023-12077-3](https://doi.org/10.1007/s00415-023-12077-3)
 39. D'Anna L, Ornello R, Foschi M, Romoli M, Abu-Rumeileh S, Dolkar T, Vittay O, Dixon L, Bentley P, Brown Z, et al. Outcomes of mechanical thrombectomy in acute stroke patients with atrial fibrillation detected after stroke versus known atrial fibrillation. *J Thromb Thrombolysis*. 2023;57:445–452. doi: [10.1007/s11239-023-02923-6](https://doi.org/10.1007/s11239-023-02923-6)
 40. Leker RR, Farraj A, Filioglo A, Sacagiu T, Honig A, Gomori JM, Cohen JE. Influence of atrial fibrillation detection time on outcome after endovascular thrombectomy. *J Neurol Sci*. 2020;57:445–452. doi: [10.1016/j.jns.2020.117189](https://doi.org/10.1016/j.jns.2020.117189)
 41. Benavente L, Larrosa D, García-Cabo C, Pérez Ál, Rico M, Vega P, Murias E, Calleja S. Safety and efficacy of mechanical thrombectomy in acute ischemic stroke of anticoagulated patients—a prospective observational study. *J Stroke Cerebrovasc Dis*. 2016;25:2093–2098. doi: [10.1016/j.jstrokecerebrovasdis.2016.06.006](https://doi.org/10.1016/j.jstrokecerebrovasdis.2016.06.006)
 42. Lallinec V, Ernst M, Sevin-Allouet M, Testard N, Delasalle-Guyomarch B, Guillon B, Mazighi M, Desal H, Bourcier R, Roy M, et al. Safety and efficacy of mechanical thrombectomy in acute ischemic stroke of anticoagulated patients. *J Neurointerv Surg*. 2018;10:E29. doi: [10.1136/neurintsurg-2017-013714](https://doi.org/10.1136/neurintsurg-2017-013714)
 43. Chang G-C, Nguyen TN, Qiu J, Li W, Zhao Y-G, Sun X-H, Liu X, Zhao Z-A, Liu L, Abdalkader M, et al. Predicting symptomatic intracranial hemorrhage in anterior circulation stroke patients with contrast enhancement after thrombectomy: the CAGA score. *J Neurointerv Surg*. 2023;15:e356–e362. doi: [10.1136/jnis-2022-019787](https://doi.org/10.1136/jnis-2022-019787)
 44. Zhao C, Luo W, Liu X, Luo J, Song J, Yuan J, Liu S, Huang J, Kong W, Hu J, et al. Effect of atrial fibrillation on outcomes after mechanical thrombectomy and long-term ischemic recurrence in patients with acute basilar artery occlusion. *Front Neurol*. 2022;13:13. doi: [10.3389/fneur.2022.909677](https://doi.org/10.3389/fneur.2022.909677)
 45. Feng S, Li T, Wu Y, Shi H, Liu Y, Xu B, Xu C, Zhou Q, Qu F, Li R, et al. Endovascular treatment of acute basilar artery occlusion in patients with and without atrial fibrillation: results from the ATTENTION registry. *Ther Adv Neurol Disord*. 2023;15:e356–e362. doi: [10.1177/17562864231159438](https://doi.org/10.1177/17562864231159438)
 46. Sagris D, Georgiopoulos G, Pateras K, Perlepe K, Korompoki E, Millionis H, Tsiachris D, Chan C, Lip GYH, Ntaios G. Atrial high-rate episode duration thresholds and thromboembolic risk: a systematic review and meta-analysis. *J Am Heart Assoc*. 2021;10. doi: [10.1161/JAHA.121.022487](https://doi.org/10.1161/JAHA.121.022487)
 47. Bertaglia E, Blank B, Blomström-Lundqvist C, Brandes A, Cabanelas N, Dan G-A, Dichtl W, Goette A, de Groot JR, Lubinski A, et al. Atrial high-rate episodes: prevalence, stroke risk, implications for management, and clinical gaps in evidence. *EP Europace*. 2019;21:1459–1467. doi: [10.1093/europace/euz172](https://doi.org/10.1093/europace/euz172)

48. Schnabel RB, Haeusler KG, Healey JS, Freedman B, Boriani G, Brachmann J, Brandes A, Bustamante A, Casadei B, Crijns HJGM, et al. Searching for atrial fibrillation Poststroke. *Circulation*. 2019;140:1834–1850. doi: [10.1161/CIRCULATIONAHA.119.040267](https://doi.org/10.1161/CIRCULATIONAHA.119.040267)
49. Kirchhof P, Toennis T, Goette A, Camm AJ, Diener HC, Becher N, Bertaglia E, Blomstrom Lundqvist C, Borlich M, Brandes A, et al. Anticoagulation with edoxaban in patients with atrial high-rate episodes. *N Engl J Med*. 2023;389:1167–1179. doi: [10.1056/NEJMoa2303062](https://doi.org/10.1056/NEJMoa2303062)
50. Shaban A, Leira EC. Neurological complications of cardiologic interventions. *Curr Neurol Neurosci Rep*. 2019;19:19. doi: [10.1007/s11910-019-0923-1](https://doi.org/10.1007/s11910-019-0923-1)
51. Alkhouli M, Alqahtani F, Tarabishy A, Sandhu G, Rihal CS. Incidence, predictors, and outcomes of acute ischemic stroke following percutaneous coronary intervention. *JACC Cardiovasc Interv*. 2019;12:1497–1506. doi: [10.1016/j.jcin.2019.04.015](https://doi.org/10.1016/j.jcin.2019.04.015)
52. Saini V, Brunet MC, Sur S, Malik AM, Khandelwal P, Desai S, Starke RM, Peterson EC, Jadhav AP, Cohen MG, et al. "Direct" mechanical thrombectomy in acute ischemic stroke during percutaneous coronary intervention. *J Stroke*. 2020;22:271–274. doi: [10.5853/jos.2020.00500](https://doi.org/10.5853/jos.2020.00500)
53. Smith CR, Leon MB, Mack MJ, Miller DC, Moses JW, Svensson LG, Tuzcu EM, Webb JG, Fontana GP, Makkar RR, et al. Transcatheter versus surgical aortic-valve replacement in high-risk patients. *N Engl J Med*. 2011;364:2187–2198. doi: [10.1056/NEJMoa1103510](https://doi.org/10.1056/NEJMoa1103510)
54. Wendler O, Schymik G, Treede H, Baumgartner H, Dumonteil N, Neumann F-J, Tarantini G, Zamorano JL, Vahanian A. SOURCE 3: 1-year outcomes post-transcatheter aortic valve implantation using the latest generation of the balloon-expandable transcatheter heart valve. *Eur Heart J*. 2017;38:2717–2726. doi: [10.1093/eurheartj/ehx294](https://doi.org/10.1093/eurheartj/ehx294)
55. Amrane H, Porta F, Van Boven A, Kappetein AP, Head S. A meta-analysis on clinical outcomes after transaortic transcatheter aortic valve implantation by the heart team. *EuroIntervention*. 2017;13:e168–e176. doi: [10.4244/EIJ-D-16-00103](https://doi.org/10.4244/EIJ-D-16-00103)
56. Gupta AK, Sabab A, Goh R, Ovenden CD, Kovoor JG, Ramponi F, Chan JCY, Reddi BAJ, Bennetts JS, Maddern GJ, et al. Endovascular thrombectomy for large vessel occlusion acute ischemic stroke after cardiac surgery. *J Card Surg*. 2022;37:4562–4570. doi: [10.1111/jocs.17082](https://doi.org/10.1111/jocs.17082)
57. Pyra K, Szymgin M, Olszewski K, Tarkowski P, Sojka M, Jargiello T. Mechanical thrombectomy for intra-procedural ischemic stroke during transcatheter aortic valve implantation. *Adv Interv Cardiol*. 2020;16:519–520. doi: [10.5114/aic.2020.101784](https://doi.org/10.5114/aic.2020.101784)
58. Coughlan JJ, Fleck R, O'Connor C, Crean P. Mechanical thrombectomy of embolised native aortic valve post-TAVI. *BMJ Case Rep*. 2017;:bcr2016218787;2017:bcr2016218787. doi: [10.1136/bcr-2016-218787](https://doi.org/10.1136/bcr-2016-218787)
59. Matsuo K, Fujita A, Tanaka J, Nakai T, Kohta M, Hosoda K, Shinke T, Hirata K, Kohmura E. Successful cerebral thrombectomy for a nonagenarian with stroke in the subacute phase after transcatheter aortic valve implantation. *Surg Neurol Int*. 2017;8:193. doi: [10.4103/sni.sni_208_17](https://doi.org/10.4103/sni.sni_208_17)
60. D'Anna L, Demir O, Banerjee S, Malik I. Intravenous thrombolysis and mechanical thrombectomy in patients with stroke after TAVI: a report of two cases. *J Stroke Cerebrovasc Dis*. 2019;28:28. doi: [10.1016/j.jstrokecerebrovasdis.2019.06.035](https://doi.org/10.1016/j.jstrokecerebrovasdis.2019.06.035)
61. Sotero FD, Rosário M, Fonseca AC, Ferro JM. Neurological complications of infective endocarditis. *Curr Neurol Neurosci Rep*. 2019;19:23. doi: [10.1007/s11910-019-0935-x](https://doi.org/10.1007/s11910-019-0935-x)
62. Morris NA, Matiello M, Lyons JL, Samuels MA. Neurologic complications in infective endocarditis. *Neurohospitalist*. 2014;4:213–222. doi: [10.1177/1941874414537077](https://doi.org/10.1177/1941874414537077)
63. Masuda J, Yutani C, Waki R, Ogata J, Kuriyama Y, Yamaguchi T. Histopathological analysis of the mechanisms of intracranial hemorrhage complicating infective endocarditis. *Stroke*. 1992;23:843–850. doi: [10.1161/01.STR.23.6.843](https://doi.org/10.1161/01.STR.23.6.843)
64. Bettencourt S, Ferro JM. Acute ischemic stroke treatment in infective endocarditis: systematic review. *J Stroke Cerebrovasc Dis*. 2020;29:104598. doi: [10.1016/j.jstrokecerebrovasdis.2019.104598](https://doi.org/10.1016/j.jstrokecerebrovasdis.2019.104598)
65. Siccoli M, Benninger D, Schuknecht B, Jenni R, Valavanis A, Bassetti C. Successful intra-arterial thrombolysis in basilar thrombosis secondary to infectious endocarditis. *Cerebrovasc Dis*. 2003;16:295–297. doi: [10.1159/000071131](https://doi.org/10.1159/000071131)
66. Sukumaran S, Jayadevan N, Mandilya A, Sreedharan S, Hari Krishnan S, Radhakrishnan N, Sylaja P. Successful mechanical thrombectomy of acute middle cerebral artery occlusion due to vegetation from infective endocarditis. *Neurol India*. 2012;60:239. doi: [10.4103/0028-3886.96424](https://doi.org/10.4103/0028-3886.96424)
67. Hernández-Fernández F, Rojas-Bartolomé L, García-García J, Ayo-Martín Ó, Molina-Nuevo JD, Barbella-Aponte RA, Serrano-Heras G, Juliá-Molla E, Pedrosa-Jiménez MJ, Segura T. Histopathological and bacteriological analysis of thrombus material extracted during mechanical thrombectomy in acute stroke patients. *Cardiovasc Intervent Radiol*. 2017;40:1851–1860. doi: [10.1007/s00270-017-1718-x](https://doi.org/10.1007/s00270-017-1718-x)
68. Bhaskar S, Cordato D, Cappelen-Smith C, Cheung A, Ledingham D, Celermajer D, Levi C. Clarion call for histopathological clot analysis in "cryptogenic" ischemic stroke: implications for diagnosis and treatment. *Ann Clin Transl Neurol*. 2017;4:926–930. doi: [10.1002/acn3.500](https://doi.org/10.1002/acn3.500)
69. Marquardt RJ, Cho S-M, Thatikunta P, Deshpande A, Wisco D, Uchino K. Acute ischemic stroke therapy in infective endocarditis: case series and systematic review. *J Stroke Cerebrovasc Dis*. 2019;28:2207–2212. doi: [10.1016/j.jstrokecerebrovasdis.2019.04.039](https://doi.org/10.1016/j.jstrokecerebrovasdis.2019.04.039)
70. Ramos C, Mayo P, Trillo S, Gómez-Escalonilla C, Caniego JL, Moreu M, Vega J, Rosati S, Simal P, Carrillo ÁX, et al. Management of Large Vessel Occlusion Stroke Related to infective endocarditis: is mechanical thrombectomy a safe option? *J Stroke Cerebrovasc Dis*. 2020;29:105248. doi: [10.1016/j.jstrokecerebrovasdis.2020.105248](https://doi.org/10.1016/j.jstrokecerebrovasdis.2020.105248)
71. Sader E, Abdalkader M, Thom N, Nguyen TN, McDonald S, Greer D, Brown SC, Mohamedali A, Gutierrez J, Shi H, et al. Endovascular treatment of infective endocarditis-related acute large vessel occlusion stroke. *J Stroke Cerebrovasc Dis*. 2021;30:105775. doi: [10.1016/j.jstrokecerebrovasdis.2021.105775](https://doi.org/10.1016/j.jstrokecerebrovasdis.2021.105775)
72. Morales A, Parry PV, Jadhav A, Jovin T. A novel route of revascularization in basilar artery occlusion and review of the literature. *Case Rep Dermatol*. 2015;2015:bcr2015011723–bcr2015011723;2015:bcr2015011723. doi: [10.1136/bcr-2015-011723](https://doi.org/10.1136/bcr-2015-011723)
73. Madeira M, Martins C, Koukoulis G, Marques M, Reis J, Abecassis M. Mechanical thrombectomy for stroke after cardiac surgery. *J Card Surg*. 2016;31:517–520. doi: [10.1111/jocs.12776](https://doi.org/10.1111/jocs.12776)
74. D'Anna L. Endovascular treatment of ischemic large-vessel stroke due to infective endocarditis: case series and review of the literature. *Neurol Sci*. 2020;41:3517–3525. doi: [10.1007/s10072-020-04599-9](https://doi.org/10.1007/s10072-020-04599-9)
75. Sloane KL, Raymond SB, Rabinov JD, Singhal AB. Mechanical thrombectomy in stroke from infective endocarditis: case report and review. *J Stroke Cerebrovasc Dis*. 2020;29:104501. doi: [10.1016/j.jstrokecerebrovasdis.2019.104501](https://doi.org/10.1016/j.jstrokecerebrovasdis.2019.104501)
76. Distefano M, Calandrelli R, Arena V, Pedicelli A, Della Marca G, Pilato F. A puzzling case of cryptogenic stroke. *J Stroke Cerebrovasc Dis*. 2019;28:e33–e35. doi: [10.1016/j.jstrokecerebrovasdis.2019.01.001](https://doi.org/10.1016/j.jstrokecerebrovasdis.2019.01.001)
77. Sgreccia A, Carità G, Coskun O, Di MF, Benamer H, Tisserand M, Scemama A, Rodesch G, Lapergue B, Consoli A. Acute ischemic stroke treated with mechanical thrombectomy and fungal endocarditis: a case report and systematic review of the literature. *J Neuroradiol*. 2020;47:386–392. doi: [10.1016/j.neurad.2019.03.003](https://doi.org/10.1016/j.neurad.2019.03.003)
78. Ambrosioni J, Urta X, Hernández-Meneses M, Almela M, Falces C, Tellez A, Quintana E, Fuster D, Sandoval E, Vidal B, et al. Mechanical thrombectomy for acute ischemic stroke secondary to infective endocarditis. *Clin Infect Dis*. 2018;66:1286–1289. doi: [10.1093/cid/cix1000](https://doi.org/10.1093/cid/cix1000)
79. Bolognese M, von Hessling A, Müller M. Successful thrombectomy in endocarditis-related stroke: case report and review of the literature. *Interv Neuroradiol*. 2018;24:529–532. doi: [10.1177/1591019918774761](https://doi.org/10.1177/1591019918774761)
80. Elodie O, Labeyrie P-E, Aubry M, Cecile D, Roux S, Ferry T, Nighoghossian N. Whipple's endocarditis diagnosed by thrombus analysis retrieved by successful mechanical thrombectomy. *J Neurol Sci*. 2019;400:42–43. doi: [10.1016/j.jns.2019.03.009](https://doi.org/10.1016/j.jns.2019.03.009)
81. Nishino W, Tajima Y, Inoue T, Hayasaka M, Katsu B, Ebihara K, Kawauchi D, Kubota M, Suda S. Severe vasospasm of the middle cerebral artery after mechanical thrombectomy due to infective endocarditis: an autopsy case. *J Stroke Cerebrovasc Dis*. 2017;26:e186–e188. doi: [10.1016/j.jstrokecerebrovasdis.2017.06.002](https://doi.org/10.1016/j.jstrokecerebrovasdis.2017.06.002)
82. Scharf EL, Chakraborty T, Rabinstein A, Miranpuri AS. Endovascular management of cerebral septic embolism: three recent cases and review of the literature. *J Neurointerv Surg*. 2017;9:463–465. doi: [10.1136/neurintsurg-2016-012792](https://doi.org/10.1136/neurintsurg-2016-012792)
83. Sveinsson O, Herrman L, Holmin S. Intra-arterial mechanical thrombectomy: an effective treatment for ischemic stroke caused by endocarditis. *Case Rep Neurol*. 2016;8:229–233. doi: [10.1159/000452213](https://doi.org/10.1159/000452213)
84. Ladner TR, Davis BJ, He L, Kirshner HS, Froehler MT, Mocco J. Complex decision-making in stroke: preoperative mechanical thrombectomy

- of septic embolus for emergency cardiac valve surgery. *Case Rep Dermatol.* 2022;13:909677. doi: [10.1136/bcr-2014-202213](https://doi.org/10.1136/bcr-2014-202213):909677
85. Kim J-M, Jeon J-S, Kim Y-W, Kang D-H, Hwang Y-H, Kim Y-S. Forced arterial suction thrombectomy of septic embolic middle cerebral artery occlusion due to infective endocarditis: an illustrative case and review of the literature. *Neurointervention.* 2014;9:101–105. doi: [10.5469/neuroint.2014.9.2.101](https://doi.org/10.5469/neuroint.2014.9.2.101)
 86. Toeg HD, Al-Atassi T, Kalidindi N, Iancu D, Zamani D, Giaccone R, Masters RG. Endovascular treatment for cerebral septic embolic stroke. *J Stroke Cerebrovasc Dis.* 2014;23:e375–e377. doi: [10.1016/j.jstrokecerebrovasdis.2013.12.014](https://doi.org/10.1016/j.jstrokecerebrovasdis.2013.12.014)
 87. Akkoyunlu Y, Iraz M, Kocaman G, Ceylan B, Aydin C, Aslan T. Abiotrophia defectiva endocarditis presenting with hemiplegia. *Jundishapur J Microbiol.* 2013;6:6. doi: [10.5812/jjm.8907](https://doi.org/10.5812/jjm.8907)
 88. Kang G, Yang TK, Choi JH, Heo ST. Effectiveness of mechanical Embolectomy for septic embolus in the cerebral artery complicated with infective endocarditis. *J Korean Med Sci.* 2013;28:1244–1247. doi: [10.3346/jkms.2013.28.8.1244](https://doi.org/10.3346/jkms.2013.28.8.1244)
 89. Dababneh H, Hedna VS, Ford J, Taimeh Z, Peters K, Mocco J, Waters MF. Endovascular intervention for acute stroke due to infective endocarditis. *Neurosurg Focus.* 2012;32:E1. doi: [10.3171/2011.11.FOCUS11263](https://doi.org/10.3171/2011.11.FOCUS11263)
 90. Kan P, Webb S, Siddiqui AH, Levy EI. First reported use of retrievable stent Technology for Removal of a large septic embolus in the middle cerebral artery. *World Neurosurg.* 2012;77:591. doi: [10.1016/j.wneu.2011.05.059](https://doi.org/10.1016/j.wneu.2011.05.059)
 91. Liang JJ. Infective endocarditis complicated by acute ischemic stroke from septic embolus: successful solitaire FR thrombectomy. *Cardiol Res.* 2012;3:277–280. doi: [10.4021/cr235e](https://doi.org/10.4021/cr235e)
 92. Walker KA, Sampson JB, Skalabrin EJ, Majersik JJ. Clinical characteristics and thrombolytic outcomes of infective endocarditis-associated stroke. *Neurohospitalist.* 2012;2:87–91. doi: [10.1177/1941874412446199](https://doi.org/10.1177/1941874412446199)
 93. Bain MD, Hussain MS, Gonugunta V, Katzan I, Gupta R. Successful recanalization of a septic embolus with a balloon mounted stent after failed mechanical thrombectomy. *J Neuroimaging.* 2011;21:170–172. doi: [10.1111/j.1552-6569.2009.00457.x](https://doi.org/10.1111/j.1552-6569.2009.00457.x)
 94. Feil K, Küpper C, Tiedt S, Dimitriadis K, Herzberg M, Dorn F, Liebig T, Dieterich M, Kellert L. Safety and efficacy of mechanical thrombectomy in infective endocarditis: a matched case–control analysis from the German stroke registry–endovascular treatment. *Eur J Neurol.* 2021;28:861–867. doi: [10.1111/ene.14686](https://doi.org/10.1111/ene.14686)
 95. Marnat G, Sibon I, Gory B, Richard S, Olindo S, Consoli A, Bourcier R, Kyheng M, Labreuche J, Darganzali C, Schiporst A, Gariel F, Blanc R, Lapergue B; ETIS Registry Investigators. Safety and outcomes of mechanical thrombectomy for acute stroke related to infective endocarditis: a case–control study. *Int J Stroke* 2021;16:585–592, DOI: [10.1177/1747493020925360](https://doi.org/10.1177/1747493020925360).
 96. Mowla A, Abdollahifard S, Sizzdahkhani S, Taherifard E, Kheshti F, Khatibi K. Endovascular treatment of large vessel occlusion strokes caused by infective endocarditis: a systematic review, meta-analysis, and case presentation. *Lifestyles.* 2022;12:2146. doi: [10.3390/life1221146](https://doi.org/10.3390/life1221146)
 97. Al-Mufti F, Schirmer CM, Starke RM, Chaudhary N, De Leacy R, Tjounmakaris SI, Haranhalli N, Abecassis IJ, Amuluru K, Bulsara KR, et al. Thrombectomy in special populations: report of the society of neurointerventional surgery standards and guidelines committee. *J Neurointerv Surg.* 2022;14:1033–1041. doi: [10.1136/neurintsurg-2021-017888](https://doi.org/10.1136/neurintsurg-2021-017888)
 98. Kelley RE, Kelley BP. Heart–brain relationship in stroke. *Biomedicine.* 2021;9:1835. doi: [10.3390/biomedicine9121835](https://doi.org/10.3390/biomedicine9121835)
 99. Schnieder M, von Glasenapp A, Hesse A, Psychogios MN, Bähr M, Hasenfuß G, Schroeter MR, Liman J. Heart failure is not associated with a poor outcome after mechanical thrombectomy in large vessel occlusion of cerebral arteries. *Stroke Res Treat.* 2019;2019:1–6. doi: [10.1155/2019/4695414](https://doi.org/10.1155/2019/4695414)
 100. Sacco RL, Benjamin EJ, Broderick JP, Dyken M, Easton JD, Feinberg WM, Goldstein LB, Gorelick PB, Howard G, Kittner SJ, et al. Risk factors. *Stroke.* 1997;28:1507–1517. doi: [10.1161/01.STR.28.7.1507](https://doi.org/10.1161/01.STR.28.7.1507)
 101. Gentile L, Pracucci G, Saia V, Falcou A, Biraschi F, Zini A, Simonetti L, Riva L, Bigliardi G, Vallone S, et al. Mechanical thrombectomy in patients with heart failure: the Italian Registry of endovascular treatment in acute stroke. *Neurol Sci.* 2023;44:3577–3585. doi: [10.1007/s10072-023-06830-9](https://doi.org/10.1007/s10072-023-06830-9)
 102. Siedler G, Sommer K, Macha K, Marsch A, Breuer L, Stoll S, Engelhorn T, Dörfler A, Arnold M, Schwab S, et al. Heart failure in ischemic stroke. *Stroke.* 2019;50:3051–3056. doi: [10.1161/STROKEAHA.119.026139](https://doi.org/10.1161/STROKEAHA.119.026139)
 103. Tan BYQ, Leow AS, Lee T-H, Gontu VK, Andersson T, Holmin S, Wong H-F, Lin C-M, Cheng C-K, Sia C-H, et al. Left ventricular systolic dysfunction is associated with poor functional outcomes after endovascular thrombectomy. *J Neurointerv Surg.* 2021;13:515–518. doi: [10.1136/neurintsurg-2020-016216](https://doi.org/10.1136/neurintsurg-2020-016216)
 104. Pana TA, Mohamed MO, Clark AB, Fahy E, Mamas MA, Myint PK. Revascularisation therapies improve the outcomes of ischemic stroke patients with atrial fibrillation and heart failure. *Int J Cardiol.* 2021;324:205–213. doi: [10.1016/j.ijcard.2020.09.076](https://doi.org/10.1016/j.ijcard.2020.09.076)
 105. Abe T, Olanipekun T, Igwe J, Khoury M, Busari O, Musonge-Effoe J, Valery E, Egbuche O, Mather P, Ghali J. Trends, predictors and outcomes of ischemic stroke among patients hospitalized with Takotsubo cardiomyopathy. *J Stroke Cerebrovasc Dis.* 2021;30:106005. doi: [10.1016/j.jstrokecerebrovasdis.2021.106005](https://doi.org/10.1016/j.jstrokecerebrovasdis.2021.106005)
 106. Y-Hassan S, Holmin S, Abdula G, Böhm F. Thrombo-embolic complications in takotsubo syndrome: review and demonstration of an illustrative case. *Clin Cardiol.* 2019;42:312–319. doi: [10.1002/clc.23137](https://doi.org/10.1002/clc.23137)
 107. Riva L, Casella G, Simonetti L, Zini A. Combined neurogenic pulmonary oedema and atypical Takotsubo cardiomyopathy in a patient with ischaemic stroke: a unique case report. *Eur Heart J Case Rep.* 2021;5:5. doi: [10.1093/ehjcr/ytab425](https://doi.org/10.1093/ehjcr/ytab425)
 108. Yamasaki T, Hayashi K, Shibata Y, Furuta T, Yamamoto K, Uchimura M, Fujiwara Y, Nakagawa F, Kambara M, Yoshikane T, et al. Takotsubo cardiomyopathy following mechanical thrombectomy for acute ischemic stroke: illustrative case. *J Neurosurg.* 2021;2:2. doi: [10.3171/CASE21372](https://doi.org/10.3171/CASE21372)
 109. Nagendra S, Arabambi B, Smith EE, Almekhlafi M. Takotsubo cardiomyopathy as an unusual complication after mechanical Thrombectomy for acute ischemic stroke. *Ann Indian Acad Neurol.* 2023;26:812–814. doi: [10.4103/aian.aian_559_23](https://doi.org/10.4103/aian.aian_559_23)
 110. Gaul C, Dietrich W, Erbguth FJ. Neurological symptoms in aortic dissection: a challenge for neurologists. *Cerebrovasc Dis.* 2008;26:1–8. doi: [10.1159/000135646](https://doi.org/10.1159/000135646)
 111. Kamp TJ, Goldschmidt-Clermont PJ, Brinker JA, Resar JR. Myocardial infarction, aortic dissection, and thrombolytic therapy. *Am Heart J.* 1994;128:1234–1237. doi: [10.1016/0002-8703\(94\)90756-0](https://doi.org/10.1016/0002-8703(94)90756-0)
 112. Fessler AJ, Alberts MJ. Stroke treatment with tissue plasminogen activator in the setting of aortic dissection. *Neurology.* 2000;54:1010–1010. doi: [10.1212/WNL.54.4.1010](https://doi.org/10.1212/WNL.54.4.1010)
 113. Igarashi T, Takahashi S, Takase S, Yokoyama H. Intraoperative thrombectomy for occluded carotid arteries in patients with acute aortic dissection: report of two cases. *Surg Today.* 2014;44:1177–1179. doi: [10.1007/s00595-013-0542-4](https://doi.org/10.1007/s00595-013-0542-4)
 114. Reznik ME, Espinosa-Morales AD, Jumaa MA, Zaidi S, Ducruet AF, Jadhav AP. Endovascular thrombectomy in the setting of aortic dissection. *J Neurointerv Surg.* 2017;9:17–20. doi: [10.1136/neurintsurg-2016-012397](https://doi.org/10.1136/neurintsurg-2016-012397)
 115. Jeong HS, Jeong E-O, Lee IY, Lee HI, Koh H-S, Kwon H-J. Endovascular recanalization therapy for patients with acute ischemic stroke with hidden aortic dissection: a case series. *J Cerebrovasc Endovasc Neurosurg.* 2023;25:333–339. doi: [10.7461/jcen.2022.E2022.06.011](https://doi.org/10.7461/jcen.2022.E2022.06.011)
 116. Lin C-M, Chang C-H, Chen S-W, Huang Y-H, Yi-Chou Wang A, Chen C-C. Direct neck exposure for rescue endovascular mechanical Thrombectomy in a patient with acute common carotid occlusion concurrent with type aortic dissection. *World Neurosurg.* 2019;124:361–365. doi: [10.1016/j.wneu.2019.01.081](https://doi.org/10.1016/j.wneu.2019.01.081)
 117. Al-Mufti F, Bauerschmidt A, Claassen J, Meyers PM, Colombo PC, Willey JZ. Neuroendovascular interventions for acute ischemic strokes in patients supported with left ventricular assist devices: a single-center case series and review of the literature. *World Neurosurg.* 2016;88:199–204. doi: [10.1016/j.wneu.2015.12.061](https://doi.org/10.1016/j.wneu.2015.12.061)
 118. Kawamura S, Koizumi S, Umekawa M, Miyawaki S, Kinoshita O, Ono M, Saito N. Long-term benefit of mechanical thrombectomy for acute ischemic stroke in patients with a left ventricular assist device: a single-center retrospective study. *World Neurosurg.* 2022;165:e331–e336. doi: [10.1016/j.wneu.2022.06.046](https://doi.org/10.1016/j.wneu.2022.06.046)
 119. Le Picault B, David C-H, Alexandre P-L, Lenoble C, Bizouarn P, Lepoivre T, Groleau N, Rozec B, Desal H, Roussel J-C, et al. Success of thrombectomy in management of ischemic stroke in two patients with SynCardia total artificial heart in bridge-to-transplantation. *Bioengineering.* 2021;8:126. doi: [10.3390/bioengineering8090126](https://doi.org/10.3390/bioengineering8090126)

120. Rice CJ, Cho S-M, Zhang LQ, Hassett C, Starling RC, Uchino K. The management of acute ischemic strokes and the prevalence of large vessel occlusion in left ventricular assist device. *Cerebrovasc Dis*. 2018;46:213–217. doi: [10.1159/000495080](https://doi.org/10.1159/000495080)
121. Rettenmaier LA, Garg A, Limaye K, Leira EC, Adams HP, Shaban A. Management of ischemic stroke following left ventricular assist device. *J Stroke Cerebrovasc Dis*. 2020;29:105384. doi: [10.1016/j.jstrokecerebrovasdis.2020.105384](https://doi.org/10.1016/j.jstrokecerebrovasdis.2020.105384)
122. Ryu B, Ishikawa T, Yamaguchi K, Matsuoka G, Eguchi S, Kawamata T. Long-term outcomes following thrombectomy for acute ischemic stroke in patients with a left ventricular assist device: a case series and literature review. *Acta Neurochir*. 2018;160:1729–1735. doi: [10.1007/s00701-018-3635-4](https://doi.org/10.1007/s00701-018-3635-4)
123. Whitaker-Lea WA, Toms B, Toms JB, Shah KB, Quader M, Tang D, Kasirajan V, Rivet DJ, Reavey-Cantwell JF. Neurologic complications in patients with left ventricular assist devices: single institution retrospective review. *World Neurosurg*. 2020;139:e635–e642. doi: [10.1016/j.wneu.2020.04.064](https://doi.org/10.1016/j.wneu.2020.04.064)
124. Hak J-F, Moreau de Bellaing A, Boulouis G, Roux C-J, Kerleroux B, Bonnet D, Houyel L, Raisky O, Kossorotoff M, Naggara O. Late pediatric mechanical thrombectomy for embolic stroke as bridge reinforcement from LVAD to heart transplantation. *JACC Case Rep*. 2021;3:686–689. doi: [10.1016/j.jaccas.2020.10.028](https://doi.org/10.1016/j.jaccas.2020.10.028)
125. Suzuki K, Nishinaka T, Tateishi M, Ichihara Y, Abe K, Niinami H, Sakai S. Computed tomography perfusion in patients of stroke with left ventricular assist device. *Heart Vessel*. 2021;36:121–126. doi: [10.1007/s00380-020-01674-1](https://doi.org/10.1007/s00380-020-01674-1)
126. Ibeh C, Mandigo GK, Sisti JA, Lavine SD, Willey JZ. Mechanical thrombectomy after acute ischemic stroke in patients with left ventricular assist devices: a nationwide analysis. *Int J Stroke*. 2023;18:215–220. doi: [10.1177/17474930221097271](https://doi.org/10.1177/17474930221097271)
127. Baumgartner H, De Backer J, Babu-Narayan SV, Budts W, Chessa M, Diller G-P, Lung B, Kluijn J, Lang IM, Meijboom F, et al. ESC guidelines for the management of adult congenital heart disease. *Eur Heart J*. 2020;2021(42):563–645. doi: [10.1093/eurheartj/ehaa554](https://doi.org/10.1093/eurheartj/ehaa554)
128. Mandalenakis Z, Rosengren A, Lappas G, Eriksson P, Hansson P, Dellborg M. Ischemic stroke in children and Young adults with congenital heart disease. *J Am Heart Assoc*. 2016;5:5. doi: [10.1161/JAHA.115.003071](https://doi.org/10.1161/JAHA.115.003071)
129. Lu N, Smith JMC, Andrade JG, Flexman AM, Field TS. Considerations in adult congenital heart disease and stroke. *Stroke*. 2020;51:51. doi: [10.1161/STROKEAHA.119.028605](https://doi.org/10.1161/STROKEAHA.119.028605)
130. Souto Silva R, Rodrigues R, Reis Monteiro D, Tavares S, Pereira JP, Xavier J, Melo C, Ruano L. Acute ischemic stroke in a child successfully treated with thrombolytic therapy and mechanical thrombectomy. *Case Rep Neurol*. 2019;11:47–52. doi: [10.1159/000496535](https://doi.org/10.1159/000496535)
131. Gerstl L, Olivieri M, Heinen F, Borggraefer I, Schroeder AS, Tacke M, Vill K, Dalla-Pozza R, Reiter K, Lutz J, et al. Successful mechanical thrombectomy in a three-year-old boy with cardioembolic occlusion of both the basilar artery and the left middle cerebral artery. *Eur J Paediatr Neurol*. 2016;20:962–965. doi: [10.1016/j.ejpn.2016.07.014](https://doi.org/10.1016/j.ejpn.2016.07.014)
132. Nasr N, Delamarre L, Cheuret E, Chausseray G, Olivot JM, Acar P, Bonneville F. Case report: late successful thrombectomy for ischemic stroke in a 2-year-old child. *Front Neurol*. 2021;12:12. doi: [10.3389/fneur.2021.670565](https://doi.org/10.3389/fneur.2021.670565)
133. Sun LR, Harrar D, Drocton G, Castillo-Pinto C, Gailloud P, Pearl MS. Endovascular therapy for acute stroke in children: age and size technical limitations. *J Neurointerv Surg*. 2021;13:794–798. doi: [10.1136/neurintsurg-2021-017311](https://doi.org/10.1136/neurintsurg-2021-017311)
134. Basso C, Rizzo S, Valente M, Thiene G. Cardiac masses and tumours. *Heart*. 2016;102:1230–1245. doi: [10.1136/heartjnl-2014-306364](https://doi.org/10.1136/heartjnl-2014-306364)
135. Brinjikji W, Morris JM, Brown RD, Thielen KR, Wald JT, Giannini C, Cloft HJ, Wood CP. Neuroimaging findings in cardiac Myxoma patients: a single-center case series of 47 patients. *Cerebrovasc Dis*. 2015;40:35–44. doi: [10.1159/000381833](https://doi.org/10.1159/000381833)
136. Rosário M, Fonseca AC, Sotero FD, Ferro JM. Neurological complications of cardiac tumors. *Curr Neurol Neurosci Rep*. 2019;19:15. doi: [10.1007/s11910-019-0931-1](https://doi.org/10.1007/s11910-019-0931-1)
137. Roeltgen D, Kidwell CS. Neurologic complications of cardiac tumors. *Handb Clin Neurol*. 2014;119:209–222. doi: [10.1016/B978-0-7020-4086-3.00015-1](https://doi.org/10.1016/B978-0-7020-4086-3.00015-1)
138. Grolla E, Dalla Vestra M, Zoffoli G, D'Ascoli R, Critelli A, Quatrala R, Mangino D, Rigo F. Papillary fibroelastoma, unusual cause of stroke in a young man: a case report. *J Cardiothorac Surg*. 2017;12:33. doi: [10.1186/s13019-017-0592-6](https://doi.org/10.1186/s13019-017-0592-6)
139. Bedoya RA, Smith T, Ma H, Goodner A, Sreedhar J. Incidental finding of an exceptionally large left atrial myxoma presenting as an acute cardioembolic stroke. *Cureus*. 2021;13:e18056. doi: [10.7759/cureus.18056](https://doi.org/10.7759/cureus.18056)
140. Garcia-Ptacek S, Matias-Guiu JA, Valencia-Sánchez C, Gil A, Bernal-Becerra I, De las Heras-Revilla V, Serna-Candel C. Mechanical endovascular treatment of acute stroke due to cardiac myxoma. *J Neurointerv Surg*. 2014;6:e1–e1. doi: [10.1136/neurintsurg-2012-010343](https://doi.org/10.1136/neurintsurg-2012-010343)
141. Santos AF, Pinho J, Ramos V, Pardal J, Rocha J, Ferreira C. Stroke and cardiac papillary fibroelastoma: mechanical thrombectomy after thrombolytic therapy. *J Stroke Cerebrovasc Dis*. 2014;23:1262–1264. doi: [10.1016/j.jstrokecerebrovasdis.2013.09.018](https://doi.org/10.1016/j.jstrokecerebrovasdis.2013.09.018)
142. Stefanou M-I, Rath D, Stadler V, Richter H, Hennersdorf F, Lausberg HF, Lescan M, Greulich S, Poli S, Gawaz MP, et al. Cardiac myxoma and cerebrovascular events: a retrospective cohort study. *Front Neurol*. 2018;9:9. doi: [10.3389/fneur.2018.00823](https://doi.org/10.3389/fneur.2018.00823)
143. Tadi P, Feroze R, Reddy P, Sravanthi P, Fakhri N, McTaggart R, Yaghi S, Silver B. Clinical reasoning: mechanical thrombectomy for acute ischemic stroke in the setting of atrial myxoma. *Neurology*. 2019;93:93. doi: [10.1212/WNL.0000000000008321](https://doi.org/10.1212/WNL.0000000000008321)
144. Tejada J, Galiana A, Balboa Ó, Clavera B, Redondo-Robles L, Alonso N, Magadán V. Mechanical endovascular procedure for the treatment of acute ischemic stroke caused by total detachment of a papillary fibroelastoma. *J Neurointerv Surg*. 2014;6:e37–e37. doi: [10.1136/neurintsurg-2013-010800.rep](https://doi.org/10.1136/neurintsurg-2013-010800.rep)
145. van den Wijngaard I, Wermer M, van Walderveen M, Wiendels N, Peeters-Scholte C, Lycklama À Nijeholt G. Intra-arterial treatment in a child with embolic stroke due to atrial myxoma. *Interv Neuroradiol*. 2014;20:345–351. doi: [10.15274/INR-2014-10026](https://doi.org/10.15274/INR-2014-10026)
146. Vega RA, Chan JL, Anene-Maidoh TI, Grimes MM, Reavey-Cantwell JF. Mechanical thrombectomy for pediatric stroke arising from an atrial myxoma: case report. *J Neurosurg Pediatr*. 2015;15:301–305. doi: [10.3171/2014.10.PEDS14292](https://doi.org/10.3171/2014.10.PEDS14292)
147. Sultan I, Bianco V, Kilic A, Jovin T, Jadhav A, Jankowitz B, Aranda-Michel E, D'angelo MP, Navid F, Wang Y, et al. Predictors and outcomes of ischemic stroke after cardiac surgery. *Ann Thorac Surg*. 2020;110:448–456. doi: [10.1016/j.athoracsur.2020.02.025](https://doi.org/10.1016/j.athoracsur.2020.02.025)
148. Sheriff F, Hirsch J, Shelton K, D'Alessandro D, Stapleton C, Koch M, Rabinov J, Jassar A, Patel A, Leslie-Mazwi T. Large-vessel occlusion stroke after cardiothoracic surgery: expanding time windows offer new salvage opportunities. *J Thorac Cardiovasc Surg*. 2019;158:186–196. doi: [10.1016/j.jtcvs.2018.11.106](https://doi.org/10.1016/j.jtcvs.2018.11.106)
149. Laimoud M, Maghirang M, Alanazi M, Al-Mutlaq SM, Althibait SA, Alanazi B, Alomran M, Al-Halees Z. Predictors and clinical outcomes of post-coronary artery bypass grafting cerebrovascular strokes. *Egypt Heart J*. 2022;74:76. doi: [10.1186/s43044-022-00315-4](https://doi.org/10.1186/s43044-022-00315-4)
150. Kashani HH, Mosienko L, Grocott BB, Glezeron BA, Grocott HP. Postcardiac surgery acute stroke therapies: a systematic review. *J Cardiothorac Vasc Anesth*. 2020;34:2349–2354. doi: [10.1053/j.jvca.2020.03.041](https://doi.org/10.1053/j.jvca.2020.03.041)
151. Wilkinson DA, Koduri S, Anand SK, Daou BJ, Sood V, Chaudhary N, Gemmete JJ, Burke JF, Patel HJ, Pandey AS. Mechanical thrombectomy improves outcome for large vessel occlusion stroke after cardiac surgery. *J Stroke Cerebrovasc Dis*. 2021;30:105851. doi: [10.1016/j.jstrokecerebrovasdis.2021.105851](https://doi.org/10.1016/j.jstrokecerebrovasdis.2021.105851)
152. Al-Khawaldeh MA, Haddad OK, Alshabatat AO, Deo SV, Rababa'h A, Altarabsheh SE. A successful endovascular treatment of an ischemic stroke following cardiac surgery. *Oman Med J*. 2015;30:473–476. doi: [10.5001/omj.2015.92](https://doi.org/10.5001/omj.2015.92)
153. Haider AS, Garg P, Watson IT, Leonard D, Khan U, Haque A, Nguyen P, Layton KF. Mechanical thrombectomy for acute ischemic stroke after cardiac surgery. *Cureus*. 2017;9:e1150. doi: [10.7759/cureus.1150](https://doi.org/10.7759/cureus.1150)
154. Fitzgerald S, Rizvi A, Dai D, Williamson EE, Lanzino G, Doyle KM, Kallmes DF, Brinjikji W. Acute ischemic stroke secondary to cardiac embolus of a 'foreign body' material after a redo sternotomy for mitral valve replacement: a case report. *Interv Neuroradiol*. 2019;25:208–211. doi: [10.1177/1591019918810538](https://doi.org/10.1177/1591019918810538)
155. Thomas MC, Delgado Almandoz JE, Todd AJ, Young ML, Fease JL, Scholz JM, Milner AM, Mulder M, Kayan Y. A case of right middle cerebral artery 'tendonectomy' following mitral valve replacement surgery. *BMJ Case Rep*. 2017;2017:bcr2016012951. doi: [10.1136/bcr-2016-012951](https://doi.org/10.1136/bcr-2016-012951)
156. Moazami N, Smedira NG, McCarthy PM, Katzan I, Sila CA, Lytle BW, Cosgrove DM. Safety and efficacy of intraarterial thrombolysis for perioperative stroke after cardiac operation. *Ann Thorac Surg*. 2001;72:1933–1938. doi: [10.1016/S0003-4975\(01\)03030-2](https://doi.org/10.1016/S0003-4975(01)03030-2)

157. Joy MA. Neurovascular rescue for embolic stroke following atrial septal defect closure. *Indian Heart J.* 2002;54:309–311.
158. Fukuda I, Imazuru T, Osaka M, Watanabe K, Meguro K, Wada M. Thrombolytic therapy for delayed, in-hospital stroke after cardiac surgery. *Ann Thorac Surg.* 2003;76:1293–1295. doi: [10.1016/S0003-4975\(03\)00455-7](https://doi.org/10.1016/S0003-4975(03)00455-7)
159. Boyer T, Sigaut S, Puybasset L, Deltour S, Clarençon F, Degos V. From preoperative evaluation to stroke center: management of postoperative acute ischemic stroke. *Anaesth Crit Care Pain Med.* 2016;35:299–305. doi: [10.1016/j.accpm.2015.11.007](https://doi.org/10.1016/j.accpm.2015.11.007)
160. Schweizer R, Jacquet-Lagrèze M, Fellahi J-L. Cerebrovascular complications after cardiac surgery: it is time to track and treat large vessel occlusion. *J Thorac Cardiovasc Surg.* 2020;159:e263–e264. doi: [10.1016/j.jtcvs.2019.10.147](https://doi.org/10.1016/j.jtcvs.2019.10.147)
161. El-Harakeh A, Lotfi T, Ahmad A, Morsi RZ, Fadlallah R, Bou-Karroum L, Akl EA. The implementation of prioritization exercises in the development and update of health practice guidelines: a scoping review. *PLoS One.* 2020;15:e0229249. doi: [10.1371/journal.pone.0229249](https://doi.org/10.1371/journal.pone.0229249)
162. Han J, Takova A, Lowcock D, Zaw HH, Quartey K, Mohan S, Redwood R, Singh-Curry V, George J, Bathula R, et al. Improving hyperacute stroke pathways at two specialist cardiothoracic centres (Royal Brompton Hospital and Harefield hospital). *Clin Med (Lond).* 2023;23:107–108. doi: [10.7861/clinmed.23-6-s107](https://doi.org/10.7861/clinmed.23-6-s107)